

THE EFFECT OF A MEDIUM DOSE (430 ROENTGENS) OF X-RAY IRRADIATION ON RESTING CELLS OF THE LIVER

ANTONI HORST and TADEUSZ RUDNICKI

From the Department of General and Experimental Pathology (Physiopathology) and the Department of Medical Physics, The Medical Academy, Poznań, Poland

ABSTRACT

The mitotic activity of regenerating liver cells after a single dose (430 r) of x-ray irradiation was studied. In every group of the experimental animals (white rats), the mitotic activity (mitotic index) and the number of abnormal mitotic figures were determined. The results indicated that resting cells irradiated a short time before mitotic activity showed reactions similar to those of cells irradiated during mitotic activity. The disturbances in the irradiated mitotically active cells were only quantitatively different from those in the irradiated resting cells. The disturbances in the irradiated resting cells depended upon the time interval between the irradiation and the beginning of mitotic activity stimulated by partial hepatectomy. It was found that the shorter the time interval, the more pronounced were the disturbances and the more similar they became to those of irradiated mitotically active cells. Conversely, the longer the time interval between the irradiation and the beginning of mitotic activity, the less pronounced were the disturbances and the more similar they became to those of the non-irradiated control cells. A discussion is presented as to whether or not the lesions of resting cells caused by a single medium dose of x-ray irradiation are reversible, and whether such lesions are only brought to light by the process of mitosis or whether the process of mitosis renders it possible for these lesions to develop.

The greater radiosensitivity of young undifferentiated cells or mitotically active cells has been known for more than fifty years. Numerous papers have been published on this subject, but only a few have dealt with the effects of radiation on resting cells (2, 3). This may be explained, perhaps, by the fact that there are only a few organs in which mitosis begins only after the application of a stimulating factor such as a partial resection which induces regeneration. One such organ is the liver; under normal conditions no mitoses are observed in this organ, but after partial hepatectomy brisk regeneration occurs and numerous mitotic figures are seen (4). Therefore, regenerating liver is very good material in which to study the effects of irradiation on resting cells (6, 7).

Holmes (5), investigating DNA synthesis in the

regenerating liver of the rat 24 hours after the animal had been irradiated with 450 r, found a decreased synthesis of DNA with inhibition of mitosis and abnormal mitotic figures.

Albert (1), who studied the effect of x-ray irradiation on the resting cells of the liver of mice, found that a dose of 125 to 1000 r caused no observable cytological effects. When the cells divided, however, the damage to them was brought to light. Cellular damage was indicated by the appearance of abnormal mitotic figures. The damage was proportional to the dose of irradiation: the greater the dose, the more numerous were the abnormal mitotic figures. That the cellular lesions caused by irradiation were irreversible was indicated by the fact that the percentage of abnormal mitotic figures induced by the toxic

effects of CCl_4 was the same at 257 days after irradiation as it was on the first few days after irradiation. The percentage of abnormal mitotic figures was greater among cells undergoing mitosis than among resting cells.

Scherer (8), using preponderantly the phase contrast microscope, found that 3 hours after irradiation of resting cells of the liver the nuclear vacuoles had extruded, probably through the nuclear membranes, without destroying the cell during the period after irradiation.

interval between irradiation and the beginning of the mitotic activity of the cells.

MATERIALS AND METHOD

Our experiments were performed on white female rats, 6 to 8 months of age, having an average weight of 160 gm. The animals were fed a uniform diet throughout the period of investigation. The partial hepatectomy was performed under ether anesthesia. First we removed the left hepatic lobe, and then we ligated the vessels going to the left part of the middle lobe and both right liver lobes in order to bring about

TABLE I
Experimental Groups

Group	No. of animals	Dose of x-rays per rat (r)	Time between irradiation and partial hepatectomy	Remarks
I	7	430	45 days	
II	30	430	72 hours (3 days)	
III	10	430	48 hours (2 days)	
IV	26	430	24 hours (1 day)	
V	29	430		Control group, irradiated 24 hours after partial hepatectomy
VI	30	—	—	Control group, not irradiated

Shapiro (9) investigated the remote effects of irradiation on the livers of rats by irradiating with 500 r and then performing partial hepatectomy 2 to 4 months later. Despite the long time interval between irradiation and partial hepatectomy, he still found a lower mitotic rate and a relatively high percentage of cells with abnormal mitotic figures. He considers these findings to be the result of irreversible genetic changes in the irradiated resting cell.

Williams *et al.* (10), on the contrary, found only a temporary suppression of the mitotic rate in livers of rats irradiated at intervals before and after partial hepatectomy.

Wilson *et al.* (11, 12), using large doses (5000 to 12,000 r) of irradiation, also described lesions of the resting cells of the liver. They found that the cells decreased in size, while the nuclei and the nucleoli increased in size. In addition, isolated necrotic cells and areas of necrosis and hemorrhage were found.

Since all these experiments showed that the mitotic changes can be found within a certain period of time between irradiation and mitosis, we decided to investigate the influence of this time

necrosis of these areas. Thus about 65 per cent of the hepatic tissue was eliminated. The postoperative course was good in all the cases. All animals were sacrificed by decapitation. Material for histologic examination was taken from the anterior part of the middle lobe of the liver. Tissue sections were fixed in Carnoy's solution and stained with iron hematoxylin.

All the experimental animals were arranged into six groups (Table I). The determination of mitotic rate in the animals in groups II, IV, V, and VI was made on the 3rd, 5th, and 7th days after partial hepatectomy. For this purpose these groups were divided into three subgroups. On the small number of animals in groups I and III, the determination of mitotic rate was made only on the 3rd day after partial hepatectomy.

Microscopic examinations were performed in order to determine the mitotic index and the percentage of cells with abnormal mitotic figures in different phases of mitosis.

The mitotic index was calculated by determining the number of cells in any phase of mitosis (from prophase to telophase) for 1000 cells. In every preparation 10,000 cells were examined.

The percentage of abnormal mitotic figures was determined separately for the meta-, ana-, and telophase stages by counting an average of 400 to 500 cells in every phase. The following were considered abnormal mitotic figures for each stage: (a) meta-

phase: unilateral spindle, interrupted connection of some chromosomes with the spindle, fragmentation of chromosomes, clumping of chromosomes into a homogeneous circular formation; (b) anaphase: irregular distribution of chromatin, fragmentation of chromosomes and chromatin bridges; (c) telophase: pseudo amitosis, acentric fragments.

Irradiation was performed with a single dose of 430 r. The intensity of radiation measured in air at a distance of 32 cm from the focus was 44 r/min. The animals were irradiated in a cage of plexiglass from the rear.

mitotic index was 127.0 ± 10.0). In group II, irradiated 72 hours before partial hepatectomy, the mitotic index on the 3rd day after partial hepatectomy was 106.0 ± 7.6 . On the 5th and 7th days after partial hepatectomy, the mitotic index became lower. The mitotic rates of all groups are shown in Table II and Fig. 1.

The damage to the chromosomal apparatuses of the cells was defined on the basis of the average number of abnormal mitotic figures (in meta-, ana-, and telophase). The percentages of the

TABLE II
Mitotic Indices in the Experimental Groups at 3 to 7 Days after Partial Hepatectomy

Time after partial hepatectomy	Groups					
	I	II	III	IV	V	VI
3 days						
No. of rats	7	10	10	9	10	10
Mitotic indices	138.0 ± 12.0	106.0 ± 7.6	69.0 ± 3.7	57.6 ± 9.8	35.9 ± 4.2	127.0 ± 10.0
5 days						
No. of rats	—	10	—	9	10	10
Mitotic indices		45.0 ± 5.5		22.8 ± 1.4	23.8 ± 2.0	41.0 ± 1.3
7 days						
No. of rats	—	10	—	8	9	10
Mitotic indices		19.1 ± 3.4		21.0 ± 1.0	21.7 ± 1.8	1.1 ± 0.5

RESULTS

Group I, Irradiated 45 Days before Partial Hepatectomy

No essential differences were found when this group was compared with the non-irradiated control group VI. The mitotic index in this group was 138.0 ± 12.0 . The difference between this and the control group is within the limits of statistical error. The average percentage of abnormal mitotic figures was 10.0 ± 2.0 per cent, and in comparison with the non-irradiated control group VI the difference is also within the limits of statistical error.

Groups II, III, and IV, Irradiated Respectively 72, 48, and 24 Hours before Partial Hepatectomy

In these groups, as compared with the non-irradiated control group VI, a marked diminution of the mitotic rate occurred. The number of cells with abnormal mitotic figures became higher. The greatest reduction of mitotic activity was observed in group IV, where the mitotic index on the 3rd day after partial hepatectomy was only 57.6 ± 9.8 (in the non-irradiated control group VI, the

abnormal mitotic figures of all groups are shown in Table III and Fig. 2.

Abnormal mitotic figures, following irradiation, were seen in all the phases of mitosis.

In the prophase, the dominating feature was an abnormally formed chromatin network which appeared homogeneous and without the typical filamentous structure. Where the degenerative process was more advanced, the compact chromatin network became more and more irregular in shape and finally nuclear dissolution occurred, which is identified by irregular chromatin clumps in the cell cytoplasm. Finally, the chromatin clumps became unstainable and the picture of karyolysis was evident.

In the later phases of mitosis, the abnormal mitotic figures did not differ from the typical postirradiation lesions of the chromosomal apparatus. In the metaphases, the location of the chromosomes appeared to be abnormal; they occupied peripheral areas of cytoplasm and had no apparent connection with the spindle. In advanced lesions caused by malformation of the spindle, the arrangement of the chromosomes was entirely irregular and haphazard. In the

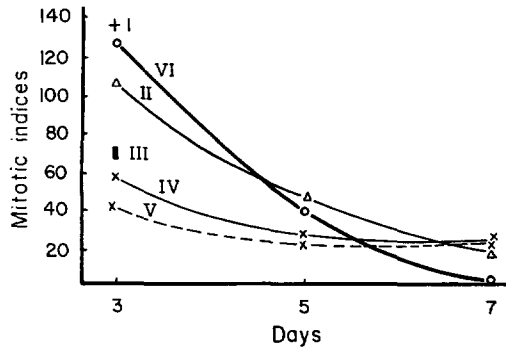


FIGURE 1
The mitotic indices at 3 to 7 days after partial hepatectomy in relation to the irradiation time. Groups I to VI.

In some resting cells, a diminution in the size of nuclei was seen. The nuclei were shrunken and had undulating nuclear membranes, and sometimes they were totally separated from the cytoplasm so that there was an empty space intervening between the nucleus and cytoplasm. Such nuclei were stained darker, which indicated their degeneration (Fig. 5). The number of nucleoli was also increased (there were 6 to 7 nucleoli). In those cases the nuclei were, as a rule, large and irregular in shape (Fig. 6). The most definite and most numerous lesions in the nuclei of resting cells were seen in group IV.

At 3 to 7 days after partial hepatectomy, the number of abnormal cells in the phase of inter-

TABLE III
The Average Percentage of Abnormal Mitotic Figures in Meta-, Ana-, and Telophases at 3 to 7 Days after Partial Hepatectomy

Time after partial hepatectomy	Groups				
	I	II	IV	V	VI
3 days					
No. of rats	7	10	9	10	10
Abnormal mitotic figures (%)	10.0 ± 2.0	31.3 ± 1.3	34.6 ± 5.1	53.0 ± 2.2	7.0 ± 1.3
5 days					
No. of rats	—	10	9	10	10
Abnormal mitotic figures (%)	—	19.7 ± 1.0	23.5 ± 1.2	25.6 ± 2.8	6.9 ± 1.0
7 days					
No. of rats	—	10	8	9	10
Abnormal mitotic figures (%)	—	11.1 ± 1.3	12.1 ± 0.5	21.3 ± 2.0	4.1 ± 1.0

anaphases and telophases, all the previously described abnormal mitotic figures were observed, such as asymmetric distribution of the chromosomes in the anaphase, chromosomal bridges in ana- and telophase, and acentric fragments and micronuclei in the telophase. All these abnormal mitotic figures are shown in Fig. 3.

Besides the lesions of mitotic cells, marked lesions were observed also in resting cells in groups II, III, and IV, but not in group I. The most striking symptom was pycnosis and vacuolization of the nuclei. In normal liver cells the chromatin appeared to be aggregated into a few small clumps. In groups II, III, and IV, the chromatin in numerous resting cells was accumulated in irregular clumps, most of which were small and kidney-shaped (Fig. 4) although some were very large.

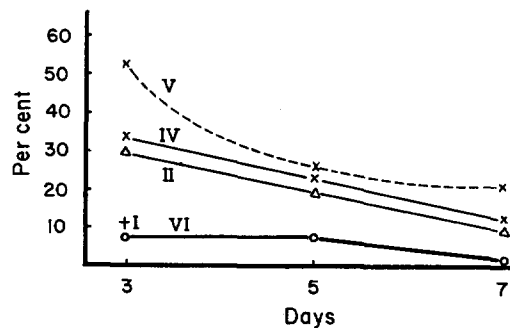


FIGURE 2
The average percentage of abnormal mitotic figures in meta-, ana-, and telophases at 3 to 7 days after partial hepatectomy in relation to the irradiation time. Groups I to VI.

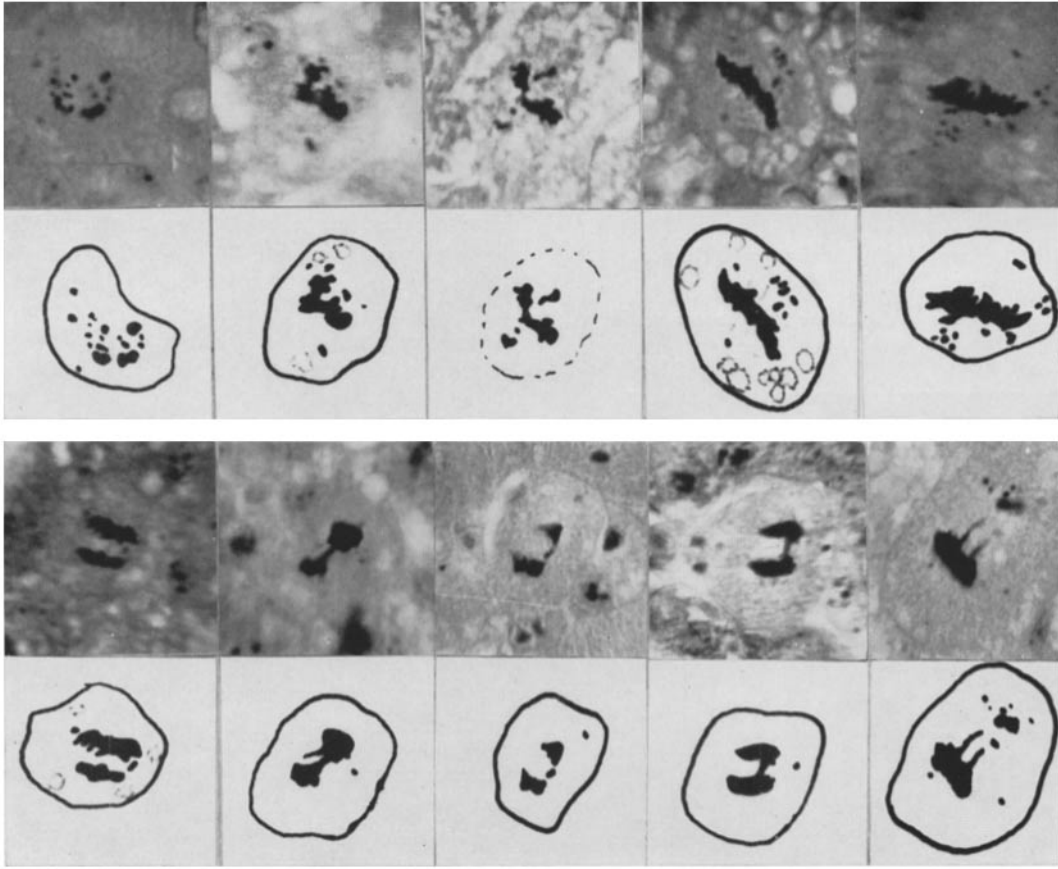


FIGURE 3
Abnormal mitotic figures. Magnification, 1200.

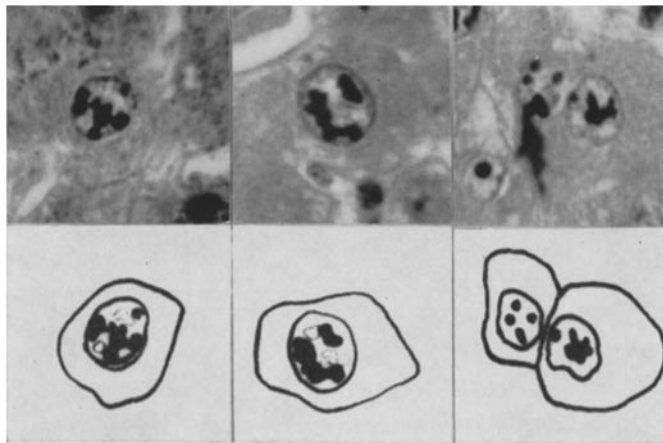


FIGURE 4
Chromatin changes in resting cells. Magnification, 1250.

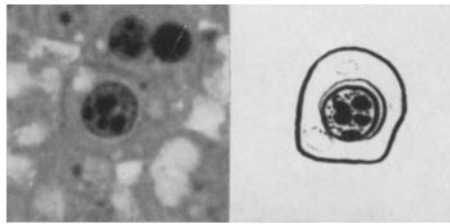


FIGURE 5
Diminution in size of the nucleus in a resting cell.
Magnification, 1250.

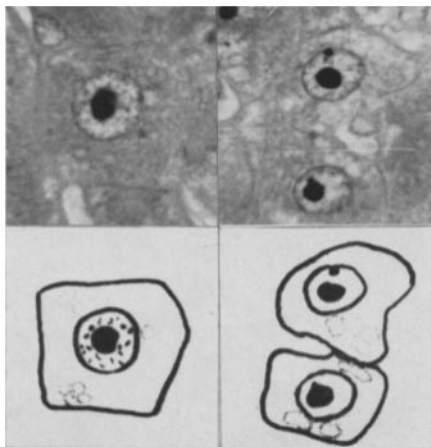


FIGURE 6
Disturbances of the nucleoli. Magnification, 1250.

kinesis (resting cells) diminished, but the number of cells with degenerative changes simultaneously increased.

Group V, Irradiated 24 Hours after Partial Hepatectomy

The animals in this group were used to check the influence of irradiation during mitotic activity of the cells of the regenerating liver. In this group, the same changes of the mitotic index and the same abnormal mitotic figures occurred as in groups II, III, and IV, the only difference being that the lesions were more severe (Tables II and III; Figs. 1 and 2).

Group VI, Control, Not Irradiated

The purpose of studying this group was to demonstrate normal mitosis in the liver after partial hepatectomy and especially to obtain an

estimate of the qualitative and quantitative deviations from the normal shown by the experimentals. In our material, we found that the first signs of mitosis occurred 24 hours after partial hepatectomy and that mitotic activity reached a peak on the 3rd day. In spite of very careful selection of animals, the differences in the mitotic rate were relatively great (96.0 to 201.0). On the 3rd day after partial hepatectomy, the mitotic index began to decrease rapidly, becoming 42 on the 5th day. On the 7th day only sporadic mitotic cells, or no mitotic cells at all, were found (Table II and Fig. 1).

Abnormal mitotic figures were not numerous in this group (Table III and Fig. 2). They were found especially in the metaphase, very sporadically in the anaphase, and not at all in the telophase.

DISCUSSION

The experiments presented here were performed in order to determine whether a single, medium dose of x-ray irradiation could influence mitotic activity at a definite time after irradiation and whether the resulting changes were reversible or not.

We found that the mitotic disturbances (the mitotic index and the abnormal mitotic figures) were more pronounced the earlier the application of the mitosis-stimulating factor, that is, the shorter the time between the irradiation and the beginning of mitotic activity induced by hepatectomy. These data are shown best in Fig. 7. The

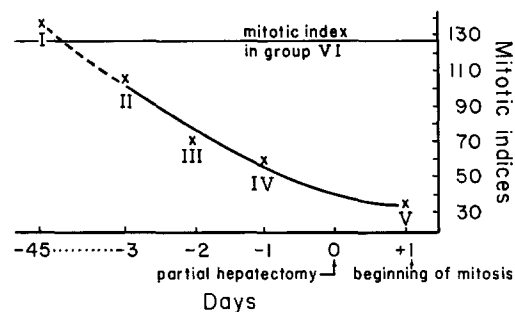


FIGURE 7
The relation of mitotic indices and the time interval between irradiation and the beginning of mitotic activity. Data obtained on the 3rd day after partial hepatectomy.

mitotic index in group II, irradiated 72 hours before partial hepatectomy, was 106; it reached almost the same level as that of the control group VI (mitotic index 127). On the contrary, in group IV, irradiated 24 hours before partial hepatectomy, this index was 57.6, being similar to the mitotic index of group V (35.9), irradiated 24 hours after partial hepatectomy, at the beginning of mitotic activity.

In contrast, the percentage of abnormal mitotic figures (Fig. 8) is almost the same in group II as

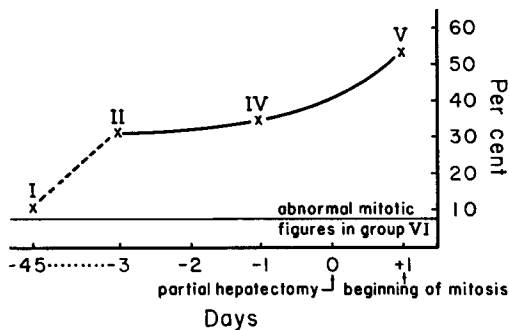


FIGURE 8

The relation of abnormal mitotic figures and the time interval between irradiation and the beginning of mitotic activity. Data obtained on the third day after partial hepatectomy.

in group IV (31.3 per cent and 34.6 per cent, respectively), proving that the damage to genetic material is more persistent than the damage to mitotic activity itself. Nevertheless, in comparison with group I (10 per cent), groups II and IV show a significant difference.

The most pronounced disorders of mitotic activity and the most abnormal mitotic figures were found in control group V, irradiated at the time of intensive mitotic activity of the hepatic cells. It is striking to find, however, that the character of these lesions is the same as that of lesions appearing in cells irradiated before hepatectomy, the only difference being greater severity.

At later times (5th and 7th days) after partial hepatectomy, the mitotic index became lower. According to Harkness (4), Yokoyama *et al.* (13), Wilson *et al.* (11, 12), Zaki (14), and others, after partial hepatectomy the mitotic activity in the regenerating liver starts in 24 hours, reaches a peak on the 3rd day, and drops off quickly, becoming almost zero about the 7th day. Thereafter

the mitotic activity begins again but remains low. Since the mitotic index becomes physiologically lower on the 5th and 7th days after partial hepatectomy, it is difficult to determine whether this lowering in the irradiated groups is a result of the irradiation. It seems rather that a certain increase of mitotic activity occurs in these groups as a kind of compensation for insufficient mitosis during the first days after partial hepatectomy.

The lesions in the resting cells (not the dividing cells) in groups II, III, IV, and V present the greatest problems for interpretation. It is difficult to determine whether these cells were damaged as resting cells or whether the damage occurred during or is a result of the preceding mitosis. On the basis of our investigations, we do not know whether these cells were damaged as resting cells during irradiation and therefore have not divided (which could explain the decrease of the mitotic index in groups II, III, and IV) or consequently show abnormal mitosis, or whether they were damaged during the preceding mitosis as result of partial hepatectomy but not sufficiently to cause the death of the cells. They could also represent cells damaged during the mitosis but partially recovered.

As in the experiments of other authors (Albert (1) and others), the pathological findings in the cells of the liver after a single dose of x-ray irradiation were more significant when the irradiation was performed during mitotic activity than during the phase of interkinesis. The question now is whether the mitotic process brings to light the lesions of irradiated resting cells, or whether the mitotic process renders it possible for these lesions to develop. We think that the second possibility is the more probable, because when the cells do not divide (as in group I, irradiated 45 days before partial hepatectomy), the lesions do not appear as they do in groups II, III, and IV, irradiated a short time before the stimulation of mitosis.

The second question pertains to whether the lesions of resting cells caused by a single x-ray irradiation are reversible or not. We think that this depends on the severity of the lesions and on the occurrence of mitosis. When the cells are not forced to divide they appear to recover, as is evident from Figs. 7 and 8; but when the lesions have already arisen as result of mitosis, then recovery is possible only by the selection and elimination of damaged cells.

There appear to be some differences between our findings and those of other authors who have reported on the same subject. Unlike most authors, we used a larger number of animals and counted 10,000 cells in order to determine the mitotic index; and we examined 400 to 500 mitotic figures in every phase in order to find the percentage of abnormal mitotic figures. Subsequently, in our non-irradiated control group, we found that the percentage of abnormal mitotic figures was relatively high (7 per cent), as compared with the

figures given by other authors, especially Albert (1), who found only 1 per cent of abnormal mitotic figures in her non-irradiated control group of mice. Perhaps this discrepancy may be explained by the fact that we used rats rather than mice. Furthermore, as we confirmed, and as is well known, the differences in mitotic index and abnormal mitotic figures among individual animals are relatively great.

Received for publication, July 11, 1961.

REFERENCES

1. ALBERT, M. D., X-irradiation induced mitotic abnormalities in mouse liver after carbon tetrachloride injury, *J. Nat. Cancer Inst.*, 1958, **20**, 309.
2. ALBERTI, W., and POLITZER, G., Ueber den Einfluss der Roentgenstrahlen auf die Zellteilung, *Arch. mikr. Anat.*, 1923, **100**, 63; 1924, **103**, 284.
3. BRECLAWIEC, L., Papers of Radiobiology, Moscow, Izdatel'stvo Akademiia Nauk SSSR, 1956.
4. HARKNESS, R., Changes of the liver of the rat after partial hepatectomy, *J. Physiol.*, 1952, **117**, 257.
5. HOLMES, B., Ionizing Radiations and Cell Metabolism, Moscow, Izdatel'stvo Inostronnoi Literatury, 1958 (translated from English edition, London, 1956).
6. ŁUCZNIK, N. V., and TSARAPKIN, L. S., *Doklady Akad. Nauk SSSR*, 1952, **124**, 213.
7. POHLE, E., and BUNTING, C., Studies of the effect of roentgen rays on the liver, *Acta Radiol.*, 1932, **13**, 117.
8. SCHERER, E., Cytologische und karyometrische Untersuchungen zur Strahlenwirkung auf Leber und Milz bei Anwendung von Total- und Teil-Bestrahlung, *Strahlentherapie*, 1956, **100**, 86.
9. SHAPIRO, I., *Doklady Akad. Nauk SSSR*, 1959, **124**, 681.
10. WILLIAMS, R. B., JR., DE LONG, R. P., and JAFFE, J. J., The effect of whole body X radiation upon cell division in radiosensitive and radioresistant tissues (abstract), *Am. J. Path.*, 1952, **28**, 546 (cited by Albert (1)).
11. WILSON, M., and STOWELL, R., Cytological changes following roentgen irradiation of the liver in mice, *J. Nat. Cancer Inst.*, 1953, **13**, 1123.
12. WILSON, M., STOWELL, R., YOKOYAMA, H., and TSUBOI, K., Cytological changes in regenerating mouse liver, *Cancer Research*, 1953, **13**, 86.
13. YOKOYAMA, H., WILSON, M., TSUBOI, K., and STOWELL, R., Regeneration of mouse liver after partial hepatectomy, *Cancer Research*, 1953, **13**, 80.
14. ZAKI, F. G., Maximum mitosis and water content in regenerating rat liver, *Z. Naturforsch.*, 1954, **96**, 239.