

OBSERVATIONS ON A STRAIN OF SPIROCHÆTA
PALLIDA ISOLATED FROM THE
NERVOUS SYSTEM.*

By HENRY J. NICHOLS, M.D.

Captain, Medical Corps, U. S. Army.

(From the Department of Pathology of the Army Medical School, Washington.)

PLATES 41 AND 42.

Our knowledge of *Spirochæta pallida* is now entering on the stage of differentiation of strains, which has already been reached in the study of many other pathogenic microorganisms. In parasitology in general, the single, original organism is soon replaced by a group of related organisms and this group is developed as a result of investigation in two directions. On the one hand relationships are discovered with outlying organisms, and on the other hand the original organism itself is resolved into a number of varieties so that the clear cut outlines of our first views give way, on closer observation, to a confusing series of gradations. In the case of *Spirochæta pallida* the same change may be noted. Soon after the discovery of the pallida, an outlying organism was found in *Spirochæta pertenuis*, which, while a distinct organism, undoubtedly belongs in the pallida group (1). On the other hand the pallida itself, according to Noguchi, consists of three different forms, the thick, the thin, and the medium form, and, what is more significant, the thick form produces characteristic lesions in the rabbit, different from those produced by the thinner forms (2).

While the work of differentiating strains is usually confined to biological characters, the explanation of clinical variations is the goal of scientific medicine. From the clinical side there has long come a strong suggestion of the existence of strains of pallida, especially of a neurotropic strain. Clinical evidence pro and con has been cited by many authors (3). Experience has shown that

* Received for publication, January 22, 1914.

clinical suggestions based on the observations of the patient alone are often fallacious on account of the many factors involved, but at the same time they form the starting point for experimental work. In the case of some organisms, the typhoid bacillus for example, the lack of a suitable experimental animal has prevented a satisfactory demonstration of the existence of mild or virulent strains, etc. In experimental syphilis, however, we have in the rabbit an animal by which, I think, certain strains can be clearly differentiated.

In this paper I propose to give some evidence on which I believe it is possible to differentiate a strain isolated from the nervous system. Whether the strain should be called neurotropic or simply highly invasive will be discussed later. As far as it is known no observations have been made on a similar strain. Most of the work in experimental syphilis has been carried out with strains isolated from chancres or mucous patches, and the clinical potentialities of these strains are entirely unknown (4). Hence it is not safe to draw clinical conclusions from the lesions in the animal. Again in the only other instance, before ours, in which a strain has been isolated from the nervous system, the experimenter simply made the statement that a typical lesion was produced in one transfer (Hoffmann (5)). Since we isolated this strain, another one has been secured by Uhlenhuth and Mulzer under similar circumstances, but no detailed report on it has been made (6). The results of experimental work in paresis will be referred to later, but it may be said here that no definite conclusions can yet be drawn except that it is difficult to transfer and to continue the strain in the rabbit. If there is any special strain of pallida, the proper way to study it would seem to be to work back from the clinical condition to the experimental animal and to carry on the strain long enough to determine its peculiar characteristics. The subject of strains of pathogenic microorganisms is, of course, a complicated one, as it calls for consideration of variations in both the host and the parasite. In this paper only variations in the parasite are considered and the conditions of the host have been made as uniform as possible by carrying the strain through a large series of animals. Fourteen transfers have been made covering a period of eighteen months, and lesions have been studied in twenty animals. Certain con-

stant characteristics have been noted and these have been compared with lesions developing in four other strains isolated from mucous patches or chancres, one of which has been carried on for four years (7).

The strain in question was isolated by Dr. Hough and myself from the spinal fluid of a case of nervous relapse following salvarsan in the secondary stage of the disease (8). The patient had definite primary and secondary symptoms, and pains in the muscles and joints probably indicated that the nervous system was already involved (9). Two intravenous injections of salvarsan were given and the symptoms rapidly cleared up. Five months later the patient developed a definite psychosis with partial paralysis of the right side of the body. The cells in the spinal fluid reached 840 per cubic millimeter and the organism was recovered by injecting three cubic centimeters of whole spinal fluid into a rabbit's testicle. The case was a typical one of nervous relapse in the secondary stage following inadequate treatment. According to our theory of the condition, the nervous system must have been already invaded during the early secondary period, and the patient would probably have suffered from nervous syphilis later.

In morphology the strain corresponds to Noguchi's thick type. While characteristic of the *pallida* in its sharp regular twists, the body is distinctly thicker than that of many other specimens which have been examined. As a result the curves are not so deep as in the thinner varieties. In Levaditi sections the thickness is especially noticeable, being almost like that of the coarser spirochætes, such as *Spirochæta refringens*. It is recognized that in dealing with such a minute organism as the *pallida*, too much weight should not be given to slight differences in form, but a constant difference is of some significance especially when accompanied by distinct lesions, as in the present instance.

Noguchi has noted that on inoculation the thick form produces hard nodules almost cartilaginous in consistence and sharply defined from the surrounding tissues. This description is suggestive in considering the present strain. On inoculation of the scrotum or testicle, a hard, discrete nodule develops and the rim retains this character while the center becomes distinctly necrotic (figure

1). Spirochætes are found in abundance in the rim but are scarce in the center of the lesion. The necrosis of the core is not due to mixed infection as no extraneous organism can be demonstrated by cultures. The sort of lesion developed by this strain is easily differentiated from the diffuse, edematous lesion which is most frequently produced by inoculation from chancres and mucous patches. With a medium type of organism, which has been carried on for four years, the lesion always grades off into the surrounding testicular tissue. On intravenous inoculation the same sort of hard, discrete lesion is produced in the testicle and scrotum. In connection with the hardness of the nodule, it is suggestive that nervous relapses have been most frequently noted in patients who have shown the papular form of secondary eruption rather than the macular (10). This clinical finding is probably to be explained by the strain of spirochæta concerned. Histologically the rim consists of a dense collection of lymphoid cells, while the center is composed of a loose connective tissue with few cells and shows evidences of degeneration.

Aside from a characteristic lesion, a characteristic location has been noted, namely, on the scrotal side of the tunica vaginalis. The lesion might be called an internal chancre. The skin surface of the scrotum and the testicle may not be at all affected, but a definite nodule will develop between them. This lesion has resulted both from local inoculation of the testicle and from intravenous injection. A similar localization has been noted in experimental syphilis with ordinary strains and may have no significance, but its occurrence is quite constant with this strain.

The third feature about this strain is a short incubation period which averaged eighteen days in testicular or scrotal inoculations. No great emphasis is laid on this fact, except when it is taken in consideration with the other characters. In Noguchi's two thick forms isolated from protracted chancres, the incubation period was five or six weeks.

The fourth and most striking feature is the generalization of this strain with the production of lesions remote from the site of inoculation. Generalization of the infection from a local inoculation has been noted occasionally by Uhlenhuth and Mulzer and

by others. Occasionally the opposite testicle is affected, rarely the eye. With the present strain one half of the animals observed have shown this generalization. The lesions have been chancres in the opposite scrota, nodules in the opposite testicle, but, most noticeably, keratitis and lesions of the eyelid. The average incubation of the first lesion was fifteen days, and of the secondary lesion forty-five days. In other words, about one month has elapsed before the generalization has become evident.

GENERALIZATION TO THE EYELIDS.

Rabbit 5/8.—Nov. 19, 1912. Right testicle; inoculation with material taken in pipette from testicle of rabbit 5/6; 5th transfer.

Dec. 2, 1912. Definite nodule present (13 days).

Jan. 6, 1913. Large nodule present in right testicle. Left scrotum shows small chancre (48 days).

Jan. 13, 1913. Multiple nodules present on the edge of upper and lower eyelids. Spirochætæ numerous (55 days).

Rabbit 5/26.—Oct. 22, 1913. Both scrota inoculated with material taken in pipette from nodule of testicle of rabbit 5/24; 13th transfer.

Oct. 31, 1913. Chancre present, right side (9 days).

Nov. 14, 1913. Chancre present, left side (23 days).

Dec. 6, 1913. Both chancres nearly healed; multiple nodules present on margin of eyelids of both eyes. Spirochætæ positive (45 days) (figure 2). Nodule present in left epididymus major (45 days). Spirochætæ positive.

The developments in rabbit 5/26 are especially striking since no inoculation was made in the testicle. After a simple subcutaneous inoculation, which was followed in nine days by a chancre, there developed in forty-five days multiple nodules in the eyelids and a lesion of the testicle, all rich in spirochætæ. Generalization of the virus can often be secured by intravenous injections especially after a strain has passed through a series of animals, but generalization following a simple cutaneous inoculation is an unusual and striking occurrence, and it has been observed so often with this strain that it must be regarded as characteristic.

GENERALIZATION TO THE CORNEA.

Rabbit 5/9.—Dec. 10, 1912. Right testicle inoculated with material taken in pipette from testicular lesion of rabbit 5/8; 6th transfer.

Dec. 30, 1912. Nodule positive in epididymus major (20 days).

Jan. 20, 1913. Nodule positive; testicle removed; large nodule with hard rim and necrotic center present. No mixed infection.

Feb. 28, 1913. Both eyes show diffuse keratitis with injection of corneal margin and pannus (80 days after inoculation, 39 days after removal of testicle).

Apr. 2, 1913. Left eye excised. Spirochætæ positive in scraping from cornea, and present in large numbers in Levaditi section (figure 3).

On intravenous injection in adult animals the same results are readily produced.

CHOROIDITIS.

In the course of the examination of the lesions of the cornea, a new lesion of experimental syphilis in the eye has been discovered by Dr. Louis Green, by the use of the ophthalmoscope; namely, a definite choroiditis. The condition has been noted in a number of animals with this strain after local inoculation, either with or without other lesions of the eye. The condition closely resembles that found in the human eye and consists of hemorrhagic points generally diffused in the lower pole of the eye. A detailed report of this lesion will be made elsewhere, but after careful study of a large number of normal eyes there is no doubt about its occurrence. It has never been observed with other strains except after intravenous injections. In one case the choroid was removed and was injected into a rabbit's testicle, but no lesion resulted. Treatment with salvarsan does not produce much improvement in the lesion.

As a further evidence of the invading power of this strain, it may be mentioned that local inoculation of the anterior chamber of the eye has always resulted positively, while with other strains my results have been slight and uncertain. The occasional occurrence of any one of the generalized lesions mentioned might be disregarded, but their occurrence in one half of the animals observed seems to me clear evidence that we are dealing here with a distinct strain, whose chief characteristic may be called its invasive power. It might also be called more virulent than other strains, or more pathogenic, but these terms are more indefinite than the one used.

PARESIS.

Now that it has been shown that paresis is "parenchymatous" syphilis of the nervous system, it becomes of interest to know the characteristics of the strain, if there is one, which produces this

disease. Unfortunately the strain seems difficult to transfer to rabbits. Noguchi succeeded in 2 out of 36 animals inoculated from 6 cases in producing lesions with spirochætæ. In one case they were present in few numbers in a section, and in one case they were found in a chancre more abundantly, but the second transfer resulted in only a trivial lesion (11). No mention is made of the type of organism. Berger has reported that after prolonged search he found a few spirochætæ in 3 slight lesions out of 20 inoculations (12). No attempt was made to continue the strain. Dr. Hough and I have made 5 inoculations of spinal fluid from 5 cases of paresis, all with negative results. We have made 16 inoculations of brain substance from 8 cases and have had slight success in 2 instances (13). In one case a slight testicular lesion was followed by a marked double keratitis, and inoculation of the cornea resulted in another slight lesion of the testicle with a definite choroiditis. Inoculation of the choroid resulted in a unilateral keratitis in the third generation, but we have been unable to demonstrate spirochætæ in the lesions or to continue the strain. In the other case a small nodule developed in the testicle after thirty-one days, but spirochætæ could not be found and transfers were unsuccessful. The only conclusion to be drawn from this work so far is that the local lesions which result from the inoculation of the brain substance in paresis are slight and contain few organisms. This finding is in marked contrast to the well marked lesion, rich in spirochætæ, which develops with the strain isolated from the case of nervous syphilis. The only resemblance between the two strains is the apparent generalization of our first strain from a paretic in the form of keratitis. The natural assumption is, of course, that in paresis the spirochætæ become modified by their long parasitization in the human brain and lose some of their power to thrive elsewhere. In this way an originally highly invasive strain might not appear so in a few transfers.

DISCUSSION.

The evidence presented above seems to me to indicate that the strain in question is a distinct one and it is characterized chiefly by its invasive power. No evidence has been found in the rabbit of any especial neurotropic power, and inoculation of a monkey's

brain was negative. By highly artificial means, such as the intravenous injection of a rich emulsion of spirochætæ, I have obtained in one case, with a generalized eruption of the skin, some symptoms of involvement of the nervous system and some slight infiltration in the meninges, but my object in general has been to imitate natural conditions as far as possible with the results given above. I believe that these experimental results may have a clinical equivalent. There is some evidence that the nervous system is more resistant to *Spirochæta pallida* than other parts of the body, and only the more active strains may be able to establish themselves there. In other words, the invasive power of the parasite may be of more importance in syphilis of the nervous system than its affinities. An affinity seems to exist in the sexual organs, and all strains might be called genitotropic, as, after intravenous injection, they invariably locate in the sexual organs whether they do elsewhere or not. But when, after local inoculation, the organism leaves the site of predilection and establishes itself in other tissues, a new factor seems to be introduced and this new factor may be called its invasive power.

Variations in this power seem to afford ground for classifying the members of the pallida group in a series of gradations. *Spirochæta pertenuis* must certainly be classed in the pallida group, but its invasive power is much less than that of the pallida. Yaws is known clinically as a non-venereal, non-hereditary, skin disease. While it is a general disease in which the spirochætæ are distributed by the blood, it also spreads by auto-inoculation in the skin. And following the septicemic stage, the organisms appear always to settle in the skin and not to penetrate the other tissues, such as the nervous system. In the rabbit the pertenuis produces a constant and characteristic lesion of the scrotum consisting of a large, edematous chancre-like lesion which is distinct from the ordinary chancres seen in experimental syphilis (figure 4). On intravenous injections, lesions of the skin of the head are produced which are also distinctive (14). *Spirochæta pertenuis*, therefore, might be put at one end of the series as affecting chiefly the skin. The strain in question might be put at the other end of the series from a point of invasive power in experimental animals and in man. Other

strains of the pallida might be given an intermediate position according to their clinical and experimental characters. If this idea is correct, it is not unreasonable to imagine that in the course of time, an examination of the type of organism in a chancre may be used for prognosis. In this discussion the condition of the host has been intentionally ignored because it is desired to emphasize a definite character in the parasite. The so called resistance of the host must, however, be considered in the last analysis, as it might lessen or accentuate the original characters of the strain, but it could not entirely change them.

SUMMARY.

A strain of *Spirochæta pallida* isolated from the nervous system has shown the following constant characters: (1) thick form; (2) the production of hard, well demarcated lesions with necrotic centers; (3) a characteristic location of the lesion; (4) a short incubation period; (5) a tendency to generalize with lesions of the skin and eye, following local inoculation of the testicle and scrotum.

It is suggested that these characters constitute a definite strain of highly invasive power and that a classification of members of the pallida group may be made in accordance with this power.

BIBLIOGRAPHY.

1. Castellani, A., *Jour. Cey. Branch, Brit. Med. Assn.*, 1905, ii, 54.
2. Noguchi, H., *Jour. Exper. Med.*, 1912, xv, 201.
3. Nonne, M., *Syphilis and the Nervous System*, translated by C. R. Ball, 2d edition, Philadelphia, 1913, 54.
4. Uhlenhuth, P., and Mulzer, P., *Arb. a. d. k. Gsndhtsamte*, 1913, xlv, 307.
5. Hoffmann, E., *Dermat. Ztschr.*, 1906, xiii, 561.
6. Uhlenhuth and Mulzer, *Centralbl. f. Bakteriol., 1te Abt., Ref.*, 1913, lvii, Supplement, 162.
7. Nichols, H. J., *Jour. Exper. Med.*, 1910, xii, 620.
8. Nichols, H. J., and Hough, W. H., *Jour. Am. Med. Assn.*, 1913, lx, 108.
9. Ehrlich, P., *Abhandlungen über Salvarsan*, 1st edition, Munich, 1913, iii, 545.
10. Benario, J., *Über Neurorezidive nach Salvarsan*, 1st edition, Munich, 1911, 125.
11. Noguchi, H., *München. med. Wchnschr.*, 1913, lx, 2484.
12. Berger, H., *München. med. Wchnschr.*, 1913, lx, 1921.
13. Nichols, H. J., and Hough, W. H., *Jour. Am. Med. Assn.*, 1913, lxi, 120.
14. Castelli, G., *Ztschr. f. Chemotherap., Orig.*, 1912-13, i, 167.

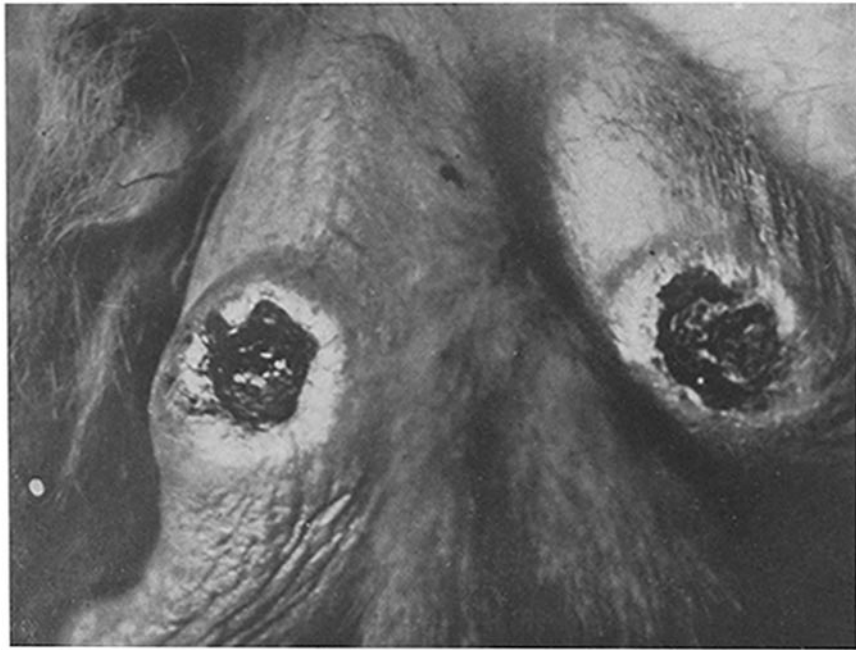


FIG. 1.

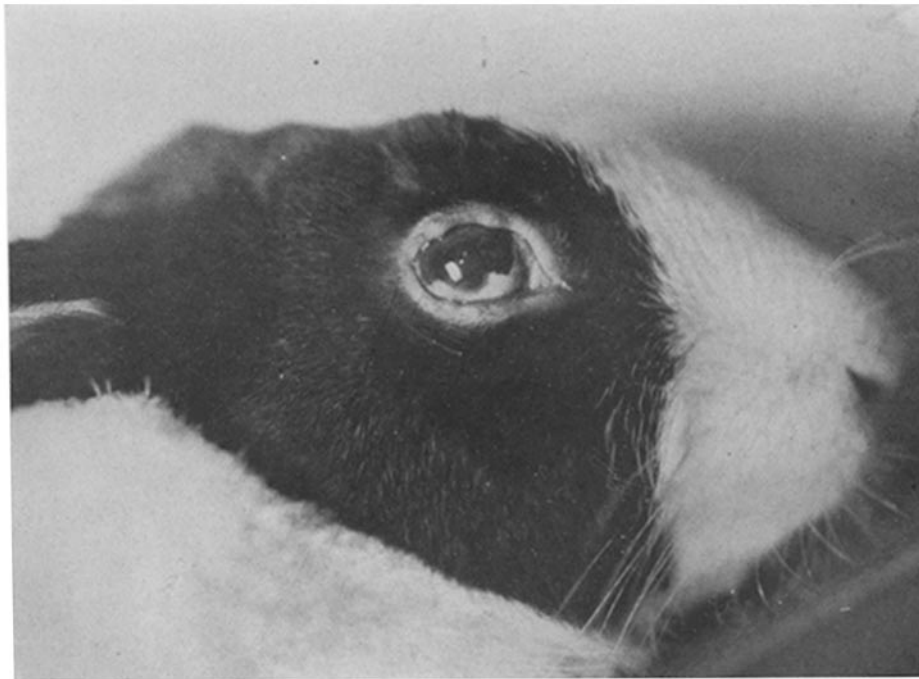


FIG. 2.

(Nichols: Observations on *Spirocheta pallida*.)

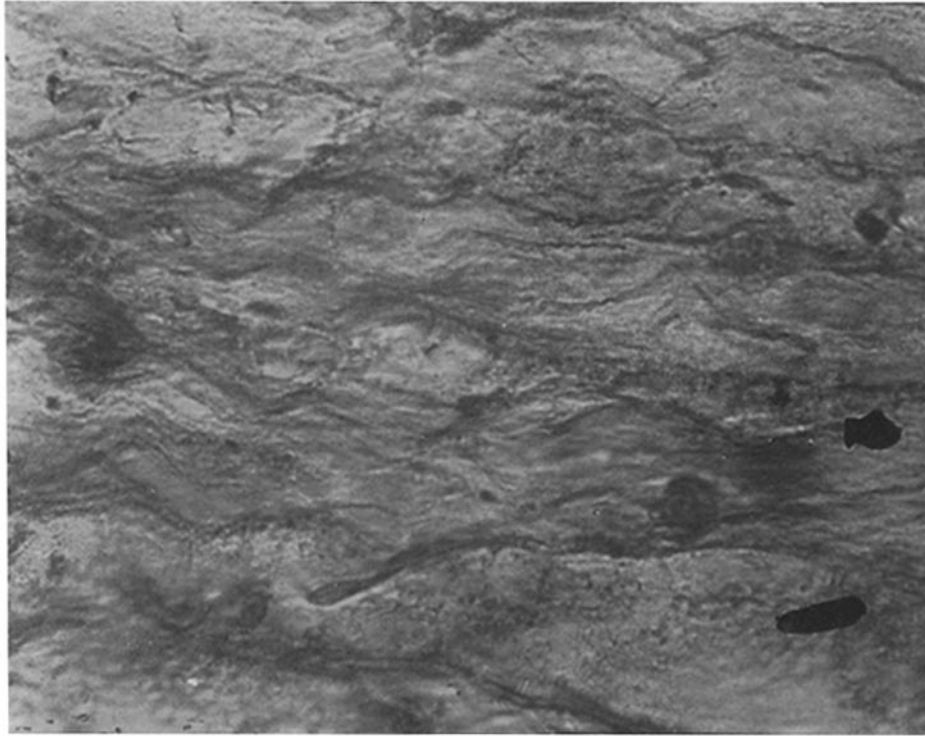


FIG. 3.

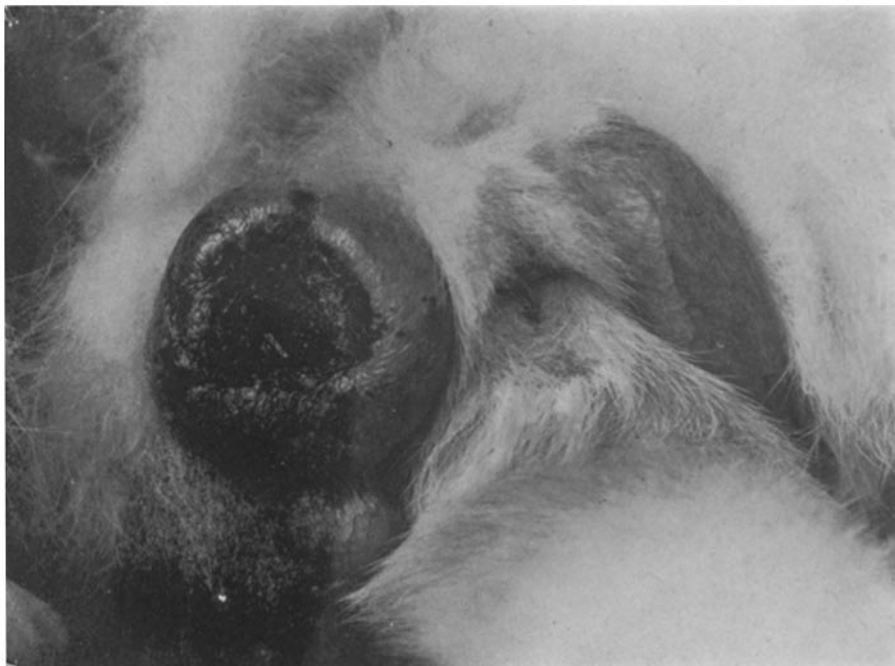

FIG. 4.

(Nichols: Observations on *Spirocheta pallida*.)

EXPLANATION OF PLATES.

PLATE 41.

FIG. 1. Type of lesion produced by subcutaneous inoculation of the scrotum with a strain from the nervous system; hard edge with completely necrotic center.

FIG. 2. Nodules on the margin of the eyelids of rabbit 5/26 (48 days after scrotal inoculation). Spirochætæ numerous.

PLATE 42.

FIG. 3. *Spirochæta pallida* in the cornea of rabbit 5/9; Levaditi section, $\times 1,300$ (80 days after testicular inoculation).

FIG. 4. Typical lesion of the scrotum produced by subcutaneous inoculation of *Spirochæta pertenuis*; large, edematous lesion; superficial necrosis.