

# Tumor Necrosis Factor Is a Critical Mediator in Hapten-induced Irritant and Contact Hypersensitivity Reactions

By Pierre F. Piguet,\* Georges E. Grau,\* Conrad Hauser,† and Pierre Vassalli\*

From the \*Department of Pathology, University of Geneva; and the †Department of Dermatology, Hôpital Cantonal Universitaire, 1211 Geneva, Switzerland

## Summary

We examined the role of cytokines in the cutaneous response to the application of trinitrochlorobenzene (TNCB) in both nonsensitized and sensitized mice, i.e., in the irritant reaction (IR) and contact hypersensitivity reactions (CH). When administered immediately before challenge, anti-tumor necrosis factor (TNF) antibody abrogated the ear swelling response in CH; antibody directed against interferon  $\gamma$  or antibodies to both granulocyte/macrophage colony-stimulating factor and interleukin 3 (IL-3) had a partial inhibitory effect; anti-IL-2 receptor antibody had no effect. Anti-TNF prevented the various features of the CH, as seen on histological sections, e.g., leukocyte infiltration and hemorrhages within the dermis and keratinocytes necrosis. Anti-TNF antibody also prevented the IR. The presence of TNF mRNA was evaluated on Northern blots; TNF- $\alpha$  mRNA was detectable in an untreated ear, increased after the application of TNCB in nonsensitized mice, and was highest in sensitized mice. TNF mRNA accumulation, which was evident 0.5 h after hapten application and lasted >72 h, was abolished by treatment with anti-TNF antibody, thus suggesting an auto-amplification of TNF production. The cellular origin of TNF mRNA was explored by *in situ* hybridization; basal keratinocytes showed the highest labeling, but TNF mRNA was also detectable in cells of the dermal infiltrate. After hapten (TNCB) application at sites susceptible (the ear) or resistant (the foot pad) to CH or IR, a close correlation was observed between TNF mRNA accumulation and the intensity of the inflammatory reaction. The major role played by TNF in both the CH and the IR explains the histologically similar aspects of these reactions and the extreme variability of these reactions at various anatomical sites.

The epicutaneous application of highly reactive compounds (haptens) to the skin can elicit two types of reactions; the primary "irritant" reaction (IR)<sup>1</sup> and the contact hypersensitivity reaction (CH) when the subject has been previously sensitized (1–3). The ability of a chemical contactant to induce CH and IR is related to its ability to couple covalently to a protein of the skin (4). Histologically, IR and CH are characterized by vasodilation, the extravasation of leukocytes in the upper dermis (i.e., monocytes, polymorphs, and eosinophils), and epidermal alterations such as keratinocyte damage (5, 6).

T lymphocytes play an inductive role in CH as well as in other delayed-type hypersensitivity (DTH) reactions elicited by the subcutaneous injection of antigen. The CH is dependent upon T lymphocytes of the CD8<sup>+</sup> phenotype (7), in contrast to the DTH, which is mainly dependent upon

the CD4<sup>+</sup> subset (8). T lymphocytes of either the CD4 or CD8 subset secrete a large variety of cytokines that might be involved in the inflammatory reaction of CH (9, 10). In this report, we investigated the role of TNF- $\alpha$  as well as that of IL-2, IL-3, granulocyte/macrophage (GM)-CSF and IFN- $\gamma$  in the elicitation phase of the CH by studying the effect of anticytokine antibody on the skin response to the application of hapten. Anti-TNF antibody treatment was the most effective inhibitor of CH; this treatment also blocked the IR. Both reactions were associated with an accumulation of TNF mRNA within basal keratinocytes and dermal infiltrate, as shown by Northern blotting and *in situ* hybridization.

## Materials and Methods

**Mice.** CBA/Ca mice were purchased from Olac Ltd., Bicester, UK, and were bred in our animal facility.

**Contact Hypersensitivity.** Mice were sensitized by an abdominal application of 0.05 ml of trinitrochlorobenzene (TNCB) (Polysciences, Inc., Warrington, PA) at 7% in olive oil/acetone (4:1).

<sup>1</sup> Abbreviations used in this paper: CH, contact hypersensitivity reaction; DTH, delayed-type hypersensitivity; GM, granulocyte/macrophage; IR, irritant reaction.

Mice were challenged by an application of 0.01 ml of 0.2–2% TNCB in olive oil on the inner face of the ear. Oxazolone (ethoxymethylene-2 phenyl oxazolone; Sigma Chemical Co., St. Louis, MO) was applied at the same concentration as TNCB. The reaction was evaluated by measuring the ear thickness with a micrometer (Oditest, HC Kroeplin GMBH, FRG).

**Histology.** The ears were fixed by immersion in 2% glutaraldehyde in 0.1 M cacodylate buffer. Tissues were embedded in methylmetacrylate, and 3- $\mu$ m sections were stained with hematoxylin-eosin. Semi-quantitative evaluation of epidermal cell necrosis was performed by scoring the number of sebaceous glands with more than three necrotic cells. The intensity of the dermal infiltrate was evaluated by counting the number of dermal leukocytes per microscopic field at 1,000-fold magnification.

**RNA Analysis.** After death by cervical dislocation, the ears were immediately frozen in liquid nitrogen. They were minced in guanidine thiocyanate, and the RNA was isolated by guanidine-thiocyanate/cesium chloride centrifugation (11). Northern blots were performed as described, using <sup>32</sup>P-labeled mRNA obtained from a *sP64* (or *6i* plasmid) containing the 696 Taq-EcoR1 fragment of the mouse TNF gene (11). Northern gels were analyzed with genoscan 1.3 (Genofit S.A., Geneva, Switzerland).

**In Situ Hybridization.** Either frozen sections or sections from formaldehyde-fixed and paraffin-embedded tissue were hybridized with a <sup>35</sup>S-labeled TNF cRNA probe (12). Sections were first exposed to a photographic film and subsequently dipped in an emulsion (Ilford Scientific Product Limited, Mobberley, Cheshire, UK).

**Rabbit Anti-mouse Cytokine Antibodies.** TNF- $\alpha$  was a kind gift from B. Allet, Glaxo, IMB, Geneva. IFN- $\gamma$  was a gift from G. Adolf, Genetech & Boehringer, Vienna, Austria. IL-3 was a gift from G. Schrimcher, Glaxo IMB. GM-CSF was a gift from J. DeLamarter, Glaxo IMB. Antibodies were prepared in rabbits by the repeated injections of recombinant cytokines in CFA, as previously described (13–15). The IgG fraction was ultracentrifuged (150,000 g for 120 min) before injection. These antibodies have been previously shown to be effective in other in vivo models (13–15). Approximately 10

$\mu$ g of the IgG fraction was able to neutralize the biological activity of 1  $\mu$ g of the purified cytokine.

**Monoclonal Antibodies.** In this study, we used mAbs for rat anti-murine IFN- $\gamma$  (R46A2) (16) and rat anti-mouse IL-2R (PC61) (17). These mAbs have been found to be effective in vivo (15, 18).

**Statistical Evaluation.** The difference between two means was evaluated by the nonparametric Mann and Whitney U test.

## Results

**Effect of Anticytokine Antibodies on the Hypersensitivity and Irritant Reactions.** TNCB-sensitized mice were injected with antibodies 4 h before challenge with TNCB. The effect on the ear swelling response is presented in Table 1. Anti-TNF antibody had the most clear-cut effect of the anticytokine antibodies tested; it abrogated the CH in all eight experiments performed ( $p < 10^{-4}$  in all experiments). Anti-GM-CSF and anti-IL-3 were used in combination since their effects are in part overlapping and since only their combined administration has been found effective in T lymphocyte-induced immunopathological reactions (14). These antibodies had a moderate inhibitory effect upon the CH which was significant ( $p < 0.05$ ) in two of four different experiments. Anti-IFN- $\gamma$  antibodies (either mAb or rabbit IgG) produced a moderate decrease of the reaction, which was significant at a  $p < 0.05$  in four of five experiments. Anti-IL-2R mAb had no detectable effect.

In these experiments performed with sensitized mice, the increased ear thickness was calculated from the response obtained in nonsensitized mice (i.e., the IR), which was used as a control. Unexpectedly, it was observed that the response of sensitized and anti-TNF-treated mice was below zero. Therefore, the possibility that the inflammatory response

**Table 1.** Effect of Anticytokine Antibodies on Cutaneous CH and IR

Priming	Challenge (TNCB)	Treatment	Ear thickness*	Inhibition†
	%		$\delta$ mm $\times 10^{-2}$	%
+	0.1	Nonimmune Ig	75 (6)	(0)
+	0.1	Anti-TNF	0 (5)	86–100
+	0.1	Anti-GM + IL-3	68 (12)	9–35
+	0.1	Anti-IFN- $\gamma$	49 (7)	18–58
+	0.1	Anti-IL-2R	89 (14)	0–0
–	0	0	0 (0)	–
–	0.1	0	21 (3)	–
–	1.0	Nonimmune Ig	43 (5)	(0)
–	1.0	Anti-TNF	3 (1)‡	61–93

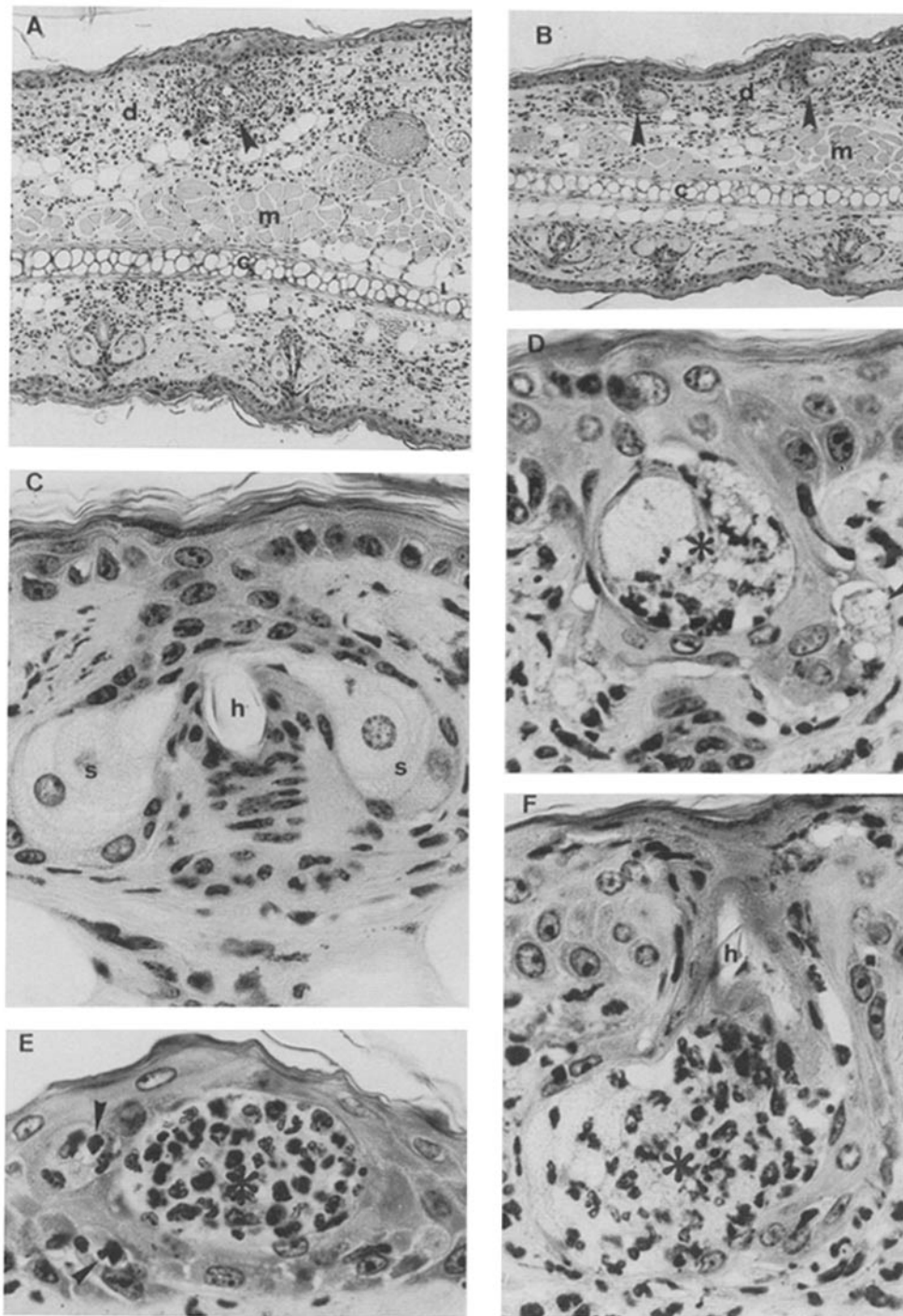
The results of the ear swelling response are the mean (+SD) of the values of a representative experiment obtained 24 h after application (six mice/group). Antibodies were injected immediately before challenge.

\* In nonsensitized animals, the ear swelling was measured in comparison with that of control, treated with the solvent (acetone/oid), while in sensitized animals, the swelling was measured in comparison with the response to TNCB of nonsensitized mice.

† Range of inhibition observed in three to five experiments.

‡  $p < 10^{-2}$ .

§  $p < 10^{-4}$ .



**Figure 1.** Ear sections from TNCB-sensitized mice killed 24 h after application of TNCB to the inner face of the ear. (A and B) Mice treated with nonimmune (A) or anti-TNF (B) rabbit IgG (H and E;  $\times 32$ ). Dermis (d), striated muscle (m), and ear cartilage (c) are recognizable. In A, the dermis of the inner side is edematous and heavily infiltrated with leukocytes and a hair follicle is necrotic (arrow); while in B, the epidermis does not show alterations and a moderate leukocytic infiltration of the inner face of the ear is evident. (C–F) Epithelial alterations of mice treated with anti-TNF (C) or normal IgG (D–F) (H and E;  $\times 202$ ). In C, a hair follicle centered around the hair (h) with two sebaceous glands does not show evident alterations. (D) The infiltrated dermis and a hair follicle present both an apparently isolated necrosis (arrow) and a more massive necrotic formation (asterisk). (E) The epidermis present a well-demarcated necrotic formation (asterisk) as well as more isolated cell necrosis. (F) Hair follicle, whose hair is recognizable (h), is completely necrotic (asterisk).

produced by TNCB in nonsensitized mice (i.e., the IR) was also influenced by anti-TNF was explored. As shown in Table 1, the IR was clearly inhibited by the anti-TNF antibody treatment.

**Histological Evaluation.** Application of TNCB to the ear of sensitized mice produced both epidermal and dermal alterations (Fig. 1 and Table 2). In the epidermis, it elicited necrosis of isolated or grouped keratinocytes (Fig. 1, D–F). In addition, necrosis was also evident in the hair follicles and

sebaceous glands (Fig. 1, D and F). Since necroses are multifocal and heterogeneous in size, the precise quantification of the entire epidermal damage was difficult. Therefore a semi-quantitative evaluation was performed on the sebaceous gland only (Table 2). In the dermis, edema, occasionally associated with hemorrhages and polynuclear leukocyte infiltration, was evident (Fig. 1, A and B). These epidermal and dermal alterations were observed in both naive and sensitized mice: e.g., challenge of a nonsensitized mice with 1% TNCB produced

**Table 2.** Histological Evaluation of the Effect of Anti-TNF on CH and IR

Priming	Challenge Treatment (TNCB)		Epithelial* necrosis	Dermal† infiltrates
	%			
-	0 <sup>§</sup>	-	<1	<1
-	0.1	-	1	1
-	1.0	-	22 (8)	23 (9)
-	1.0	n Ig	12 (3)	13 (2)
-	1.0	a TNF	<1 <sup>  </sup>	2 (2) <sup>  </sup>
+	0.1	n Ig	4 (3)	9 (8)
+	0.1	a TNF	1 (2)	3 (2)
+	1.0	n Ig	32 (14)	59 (8)
+	1.0	a TNF	16 (10) <sup>  </sup>	21 (6) <sup>  </sup>

Results are the mean (+SD) of the values observed in greater than five mice.

\* Epithelial necrosis is the percentage of sebaceous glands with more than three necrotic cells.

† Number of dermal leukocytes per microscopic field.

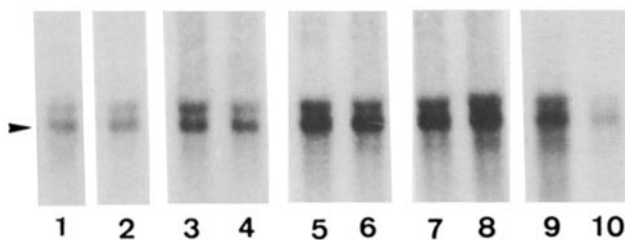
§ Application of acetone/oil.

||  $p < 10^{-2}$ .

lesions similar to those observed with 0.1% TNCB applied upon the ear of TNCB-sensitized mice.

Administration of anti-TNF antibody reduced all the components (i.e., dermal and epidermal) of the CH and the IR (Fig. 1, A and B, and Table 2).

**Expression of TNF- $\alpha$  mRNA.** After extraction of whole ear RNA, the content of TNF mRNA was evaluated on Northern blots. TNF mRNA was detectable in normal ears and was gradually increased by the topical application of the solvent (acetone/oil), of TNCB in nonsensitized recipients, and of TNCB in sensitized mice, as seen 24 h after application (Fig. 2). RNA extracted various times after application

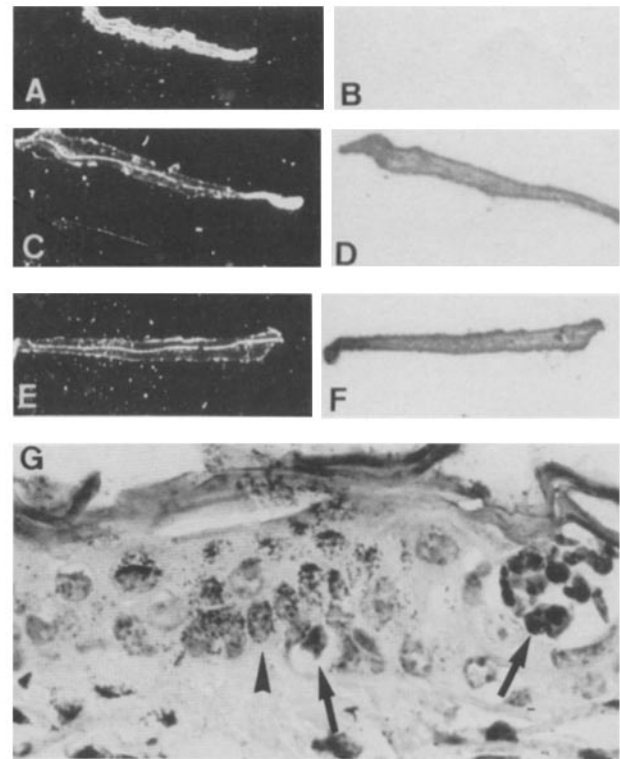


**Figure 2.** Expression of TNF- $\alpha$  mRNA in the whole ear RNA. Lanes were loaded with the RNA from individual mice killed 24 h after application. (Lanes 1 and 2) Nontreated mice; (lanes 3 and 4) mice treated with the solvent acetone/oil; (lanes 5 and 6) mice treated with 1% TNCB; (lanes 7 and 8) sensitized mice, treated with 1% TNCB; (lanes 9 and 10) sensitized mice treated with 1% TNCB and treated with nonimmune (9) or anti-TNF (10) rabbit IgG. The position of the TNF mRNA is indicated by an arrow.

of TNCB to nonsensitized mice showed a clear-cut increase of the TNF mRNA level 0.5 h after application, which persisted without gross change for 72 h (data not shown). Similar accumulation of TNF mRNA were observed after application of oxazolone (data not shown).

The accumulation of TNF mRNA during CH was influenced by TNF itself, since it was prevented by anti-TNF antibody (Fig. 2, lanes 9 and 10); in four mice undergoing CH and treated with anti-TNF IgG, the TNF mRNA was <3% of that of the mice treated with nonimmune IgG, as seen by densitometric analysis of the Northern blots.

The cellular origin of TNF mRNA was explored by in situ hybridization. As seen in Fig. 3, the TNCB application to the inner face of the ear greatly increased the hybridization of the <sup>35</sup>S-labeled TNF probe to the ear, the basal layer of the epidermis being the most intensively labeled (Fig. 3, A-D). This pattern of hybridization was further increased by the application of TNCB to sensitized mice (Fig. 3, E and F). Cells bearing grains were detected in the basal layer of keratinocytes (Fig. 3 G) and also in the dermis, which appeared to be polymorphonuclear leukocytes (not shown).



**Figure 3.** TNF mRNA revealed by in situ hybridization. (A-F) Frozen ear sections, with on the left (A, C, and E) the phase contrast microscopy, and on the right (B, D, and F), the film autoradiograph. (A and B) Mice treated with solvent only; (C and D) nonsensitized mice treated with 1% TNCB; (E and F) sensitized mice treated with 1% TNCB. Grains are present over D and F and are more dense over the epidermis. (G) Autoradiograph performed upon a paraffin-embedded ear section showing a group of basal keratinocytes bearing grains (wide arrow) with isolated or groups of necrotic keratinocytes in the proximity (thin arrows).

**Table 3.** Correlation between TNCB-induced IR and TNF mRNA Accumulation

Organ	Epithelial necrosis	Dermal leukocytes	TNF mRNA
Ear	49 (8)	34 (12)	72
Back	41 (12)	18 (2)	5
Foot pad	-	1	<1

Four individual mice were examined as in Table 1. TNF mRNA is expressed as the median (range) in arbitrary units of the densitometric analysis of the Northern blots.

*Correlation between Expression of TNF mRNA and CH.* The intensity of the CH varies greatly in different anatomical sites. As shown on Table 3, it is severe in the ear, intermediate in the trunk, and completely absent in the foot pad skin. This response correlated with the TNF mRNA accumulation after application of TNCB; TNF mRNA was most abundant in the ear and undetectable in the foot pad (Table 3).

## Discussion

The epicutaneous application of certain chemicals on the skin can induce two types of inflammatory reactions; the IR and the CH, in nonsensitized and sensitized subjects, respectively. In one case, the reaction results from some inflammatory properties of the chemical, while in the other, it is amplified by the activation of previously sensitized T lymphocytes. These two types of reactions are extremely difficult to discriminate on histological sections and this has been a long standing diagnostic concern (1-3, 6). The present results indicate that these morphological similarities are due to the involvement of the same effector mechanism, in which TNF plays a key role; this conclusion is similar to that obtained in several other inflammatory or immunopathological reactions, such as the endotoxemia (19), Graft-vs.-host-disease (20), BCG granuloma (21), cerebral malaria (13), or the fibrotic reactions induced by a drug (bleomycin) (22) or silica particles (23). In these reactions, T lymphocytes and macrophages appear to be the major source of TNF, while in the present experiments, it is the keratinocytes.

There are three lines of evidence that argue in favor of a major role of TNF in both IR and CH; first, these reactions are associated with a marked rise in the TNF mRNA level; second, they are considerably reduced or abrogated by anti-TNF antibody; third, a continuous hypodermal infusion of TNF can reproduce many of the dermal or epidermal features of CH, notably epidermal necrosis, dermal leukocytic infiltration, and hemorrhagic necrosis (24). TNF, which is recognized as a powerful mediator of inflammatory reaction, might induce these alterations either directly, since it can react with a wide range of cell types (19), or indirectly by the activation of several other cells. Thus, epidermal cell necrosis might be due to a direct toxic effect of TNF, since the toxicity of TNF for epithelial cells is documented in vitro (25). Simi-

larly, edema and hemorrhagic necrosis might be due to a toxic effect of TNF on endothelial cells since TNF can damage endothelial cells in vitro (26). In addition, these lesions are aggravated by the sequestration of leukocytes: there is indeed an obvious correlation between the increase in ear thickness (i.e., in great part due to dermal edema) and the accumulation of leukocytes within the dermis (i.e., see tables 1 and 2). Cell adhesion molecules are most likely involved in leukocyte sequestration, and TNF is indeed one of the cytokines that can increase the expression of cell adhesion molecules upon endothelial cells and leukocytes (27). Overexpression of the intercellular adhesion molecule 1 (ICAM-1) has indeed been reported as an early event in CH (28), and administration of anti-LFA-1 mAb blocks both the CH and IR (our unpublished observation).

The in situ hybridization data suggest that several cell types are accumulating TNF mRNA (and presumably producing TNF) during IR or CH, the quantitatively most important being the basal keratinocyte. Production of IL-1 by epidermal cells has been extensively documented (reviewed in reference 29), and accumulation of IL-1- $\alpha$  mRNA during IR and CH was detectable on Northern blots (not shown). In contrast, information concerning epidermal TNF is relatively scarce; a squamous cell epidermal carcinoma has been reported to contain TNF mRNA (30). Production of TNF by the basal keratinocytes appears to occur in close correlation and proximity with a massive necrosis of these epithelial cells (see Fig. 3). Since anti-TNF antibody abrogates the TNF mRNA accumulation (Fig. 2, lanes 9 and 10), this implies that TNF influences its own synthesis during CH and is therefore involved in an auto-amplification process. In this respect, it is of interest to recall that TNF is an inducer of its own synthesis in macrophages (21). Studies of keratinocytes in vitro should help clarify whether this TNF-induced auto-amplification process can occur with the keratinocytes alone.

Of the other cytokines explored in this work, two, IL-2 and IFN- $\gamma$ , are produced rather exclusively by lymphocytes, while IL-3 and GM-CSF are produced by both the cells of the immune system and the epidermal cells (reviewed in reference 29). IL-2 and IFN- $\gamma$  might be involved in various phases of T lymphocyte activation and proliferation, while IL-3 and GM-CSF might be involved in the sequestration and local growth of leukocytes. Antibody capable of blocking the action of IFN- $\gamma$  or GM-CSF IL-3 had moderate inhibitory effects on the CH, indicating that these cytokines exert some complementary role in the full expression of the CH. A similar decrease of the DTH reaction by treatment with anti-IFN- $\gamma$  antibody has already been reported (31). Anti-IL-2R mAb had no effect upon the CH when given immediately before the challenge, while it has been reported to exert an inhibitory effect upon a DTH reaction (32), a difference that might be related to the implication of different T lymphocyte subset in these two reactions.

The present study is also relevant with respect to the considerable differences in the response of the skin to hapten application at different anatomical sites (ear, back, foot pad). Differences in responsiveness have been related to differences in the density of vaso-amine-secreting cells such as basophils

and mastocytes (33, 34) or to differences in the density of epidermal Langerhans cells (35) or epidermal Thy-1 cells (36). The present study provides an alternative or additional in-

terpretation, i.e., the capacity of basal keratinocytes to produce TNF might determine the degree of skin responsiveness to hapten application.

---

We thank A. F. Rochat, C. Vesin, C. Briollet, C. Magniu, and G. Leyvraz for their technical collaboration.

This work was supported by the grant 3.550.87 from the Swiss National Science foundation.

Address correspondence to Pierre F. Piguet, Département de Pathologie, Centre Médical Universitaire, Université de Genève, 1 rue Michel-Servet, 1211 Genève 4, Switzerland.

Received for publication 7 November 1990.

## References

1. Avnstorp, C., E. Ralfkier, J. Jorgensen, and G.L. Wantzin. 1987. Sequential immunophenotypic study of lymphoid infiltrate in allergic and irritant reactions. *Contact Dermatitis*. 16:239.
2. Robinson, M.K., R.E. Fletcher, G.R. Johnson, W.E. Wyder, and J.K. Maurer. 1990. Value of the cutaneous basophil hypersensitivity (CBH) response for distinguishing weak contact sensitization from irritation reactions in the guinea pig. *J. Invest. Dermatol.* 94:636.
3. Medenica, M., and A. Rostenberg. 1971. A comparative light and electron microscopic study of primary irritant contact dermatitis and allergic contact dermatitis. *J. Invest. Dermatol.* 56:259.
4. Eisen, H.N., L. Orris, and S. Belman. 1952. Elicitation of delayed allergic skin reactions with haptens: the dependence of elicitation on hapten combination with protein. *J. Exp. Med.* 95:473.
5. Roupe, G., and B. Ridell. 1979. The cellular infiltrate in contact sensitivity in mice to picryl chloride in the mouse. *Acta Dermatovenes. (Stockholm)*. 59:191.
6. Flax, M.H., and J.B. Caulfield. 1963. Cellular and vascular components of allergic contact dermatitis. *Am. J. Pathol.* 43:1031.
7. Gocinski, B.L., and R.E. Tigelaar. 1990. Roles of CD4<sup>+</sup> and CD8<sup>+</sup> T cells in murine contact sensitivity revealed by in vivo monoclonal antibody depletion. *J. Immunol.* 144:4121.
8. Cher, D.J., and T.R. Mosmann. 1987. Two types of murine helper T cell clone. II. Delayed-type hypersensitivity is mediated by Th1 clones. *J. Immunol.* 138:3688.
9. Fong, T.A., and T.R. Mosmann. 1990. Alloreactive murine CD8<sup>+</sup> T cell clones secrete the Th1 pattern of cytokines. *J. Immunol.* 144:1744.
10. Mosmann, T.R., and R.L. Coffman. 1989. Th1 and Th2 cells: different patterns of lymphokine secretion lead to different functional properties. *Annu. Rev. Immunol.* 7:145.
11. Collart, M., D. Belin, J.D. Vassalli, and P. Vassalli. 1987. Modulation of functional activity in differentiated macrophages are accompanied by early and transient increase or decrease in c-Fos gene transcription. *J. Immunol.* 139:949.
12. Sappino, A.P., J. Huarte, D. Belin, and J.D. Vassalli. 1989. Plasminogen activators in tissue remodeling and invasion: messenger RNA localization in mouse ovaries and implanting embryos. *J. Cell Biol.* 109:2471.
13. Grau, G.E., L.F. Fajardo, P.F. Piguet, B. Allet, P.H. Lambert, and P. Vassalli. 1987. Tumor necrosis factor (cachectin) as an essential mediator in murine cerebral malaria. *Science (Wash. DC)*. 237:1210.
14. Grau, G.E., V. Kindler, P.F. Piguet, P.H. Lambert, and P. Vassalli. 1988. Prevention of experimental cerebral malaria by anticytokine antibodies. Interleukin 3 and granulocyte/macrophage colony-stimulating factor are intermediates in increased tumor necrosis factor production and macrophage accumulation. *J. Exp. Med.* 168:1499.
15. Grau, G.E., H. Heremans, P.F. Piguet, P. Pointaire, P.H. Lambert, A. Billiau, and P. Vassalli. 1989. Monoclonal antibody against interferon-gamma can prevent experimental cerebral malaria and its associated overproduction of tumor necrosis factor. *Proc. Natl. Acad. Sci. USA*. 86:5572.
16. Spitalny, G.L., and E.A. Havell. 1984. Monoclonal antibody to murine gamma interferon inhibits lymphokine-induced antiviral and macrophage tumoricidal activities. *J. Exp. Med.* 159:1560.
17. Lowenthal, J.W., P. Corthesy, C. Tougne, R. Lees, R.H. MacDonald, and M. Nabholz. 1985. High and low affinity IL-2 receptors: analysis by IL-2 dissociation rate and reactivity with monoclonal anti-receptor antibody PC-61. *J. Immunol.* 135:3988.
18. Ferrara, J.L., A. Marion, J.F. McIntyre, G.F. Murphy, and S.J. Burakoff. 1986. Amelioration of acute graft vs. host disease due to minor histocompatibility antigens by in vivo administration of anti-interleukin-2 receptor antibody. *J. Immunol.* 137:1847.
19. Beutler, B., and A. Cerami. 1989. The biology of cachectin/TNF- A primary mediator of the host response. *Annu. Rev. Immunol.* 7:625.
20. Piguet, P.F. 1990. Tumor necrosis factor and graft versus host disease. In *Graft-vs.-Host Disease. Immunology, Pathophysiology, and Treatment*. S.J. Burakoff, H.J. Deeg, J. Ferrara, and K. Atkinson, editors. Marcel Dekker, Inc., New York. 255-276.
21. Kindler, V., A.P. Sappino, G.E. Grau, P.F. Piguet, and P. Vassalli. 1989. The inducing role of tumor necrosis factor in the development of bactericidal granulomas during BCG infection. *Cell*. 56:731.
22. Piguet, P.F., M.A. Collart, G.E. Grau, Y. Kapanci, and P. Vassalli. 1989. Tumor Necrosis Factor Cachectin Plays a Key Role in Bleomycin-Induced Pneumopathy and Fibrosis. *J. Exp. Med.*

- 170:655.
23. Piguet, P.F., M.A. Collart, G.E. Grau, A.P. Sappino, and P. Vassalli. 1990. Requirement of tumor necrosis factor for development of silica-induced pulmonary fibrosis. *Nature (Lond.)* 344:245.
  24. Piguet, P.F., G.E. Grau, and P. Vassalli. 1990. Subcutaneous perfusion of tumor necrosis factor induces local proliferation of fibroblasts, capillaries, and epidermal cells, or massive tissue necrosis. *Am. J. Pathol.* 136:103.
  25. Taverne, J., D.C. Rayner, P.H. van der Meide, P.M. Lydyard, S.P. Bidey, and A. Cooke. 1987. Cytotoxicity of tumor necrosis factor for thyroid epithelial cells and its regulation by interferon-gamma. *Eur. J. Immunol.* 17:1855.
  26. Schuger, L., J. Varani, R.M. Marks, S.L. Kunkel, K.J. Johnson, and P.A. Ward. 1989. Cytotoxicity of tumor necrosis factor-alpha for human umbilical vein endothelial cells. *Lab Invest.* 61:62.
  27. Pober, J.S. 1988. Cytokine-mediated activation of vascular endothelium: physiology and pathology. *Am. J. Pathol.* 133:426.
  28. Griffiths, C.E.M., and B.J. Nickoloff. 1989. Keratinocyte intercellular adhesion molecule-1 (ICAM-1) expression precedes dermal T lymphocyte infiltration in allergic contact dermatitis (*Rhus dermatitis*). *Am. J. Pathol.* 135:1045.
  29. Ansel, J., P. Perry, J. Brown, D. Damm, T. Phan, C. Hart, T. Luger, and S. Hefeneider. 1990. Cytokine modulation of keratinocyte cytokines. *J. Invest. Dermatol.* 94:101.
  30. Spriggs, D.R., K. Imamura, C. Rodriguez, E. Sariban, and D.W. Kufe. 1988. Tumor necrosis factor expression in human epithelial tumor cell lines. *J. Clin. Invest.* 81:455.
  31. Fong, T.A.T., and T.R. Mosmann. 1989. The role of IFN-gamma in delayed-type hypersensitivity mediated by Th1 clones. *J. Immunol.* 143:2887.
  32. Kelley, V.E., G.N. Gaulton, and T.B. Strom. 1987. Inhibitory effects of anti-interleukin 2 receptor and anti-L3T4 antibodies on delayed type hypersensitivity: the role of complement and epitope. *J. Immunol.* 138:2771.
  33. Galli, S., and I. Hammel. 1984. Unequivocal delayed hypersensitivity in mast cell deficient and beige mice. *Science (Wash. DC)* 226:710.
  34. Askenase, P.W., H. Van Loveren, S. Kraeuter-Kops, Y. Ron, R. Maede, T.C. Theoharides, J.J. Nordlund, H. Scovern, M. Gerhson, and W. Ptak. 1985. *Scand. J. Immunol.* 21:159.
  35. Lynch, D.H., M. Gurish, and R.A. Daynes. 1981. Relationship between epidermal langerhans cell density, ATPase activity and the induction of contact hypersensitivity. *J. Immunol.* 126:1892.
  36. Bigby, M., T. Kwan, and M.S. Sy. 1987. Ratio of Langerhans cells to Thy-1<sup>+</sup> dendritic epidermal cells in murine contact epidermis influences the intensity of contact hypersensitivity. *J. Invest. Dermatol.* 89:495.