

***ras* ONCOGENE p21 EXPRESSION IS INCREASED
IN PREMALIGNANT LESIONS AND HIGH GRADE
BLADDER CARCINOMA**

BY MICHAEL V. VIOLA, FRANK FROMOWITZ, SHEILA ORAVEZ,
SWATI DEB, AND JEFFREY SCHLOM*

*From the Departments of Medicine, Microbiology and Pathology, State University of New York at Stony Brook, Stony Brook, New York 11794, and the *Tumor Immunology and Biology Branch, National Cancer Institute, National Institutes of Health, Bethesda, Maryland 20205*

The most frequently detected transformation-inducing genes in human solid tumors are members of the *ras* family of cellular oncogenes (1). Somatic mutations of the cellular *ras* oncogenes result in a gene product (p21) with increased transformation-inducing activity (2–4). Quantitative changes in *ras* expression may be equally important in carcinogenesis, since increased levels of cellular Harvey *ras* (*c-H-ras*) p21 will transform cells in vitro (5), and increased levels of messenger RNA (mRNA) specific for *ras* genes, as well as other oncogenes, are frequently detected in human tumors (6). However, there is a paucity of data on the relationship between the malignant potential of a tumor and the levels of p21 expressed in neoplastic cells (7). Human bladder cancer is particularly suited for studies of this sort, since patients with this disease have diffuse abnormalities of the urinary tract epithelium (urothelium) consisting of benign and presumed “pre-malignant” (dysplastic) lesions in regions separate from the primary carcinoma (8). We have used an immunohistochemical assay to localize and quantitate *ras* p21 in the urinary tract of bladder cancer patients. In contrast to previous studies (9, 10) showing *ras* activation (mutation) in <10% of bladder carcinomas, our study demonstrates increased *ras* p21 expression in all high grade bladder carcinomas studied, and, further, this antigen may be an indicator of the malignant potential of pre-malignant as well as neoplastic lesions of the bladder.

Materials and Methods

Pathological Classification. The criteria of the National Bladder Cancer Collaborative Group A were used to classify benign (hyperplasia) and dysplastic (atypical) epithelial changes (11). Papillary and invasive carcinomas of the bladder were classified according to the degree of nuclear anaplasia (12). Patients who had received previous bladder radiation or chemotherapy were excluded from the study.

Immunoperoxidase Studies. The *ras* p21 monoclonal antibody (RAP-5) was generated against a synthetic peptide having the sequence of amino acids 10–17 of the T24 bladder cancer cell line *H-ras-1* oncogene. This peptide (Gly, Ala, Val, Gly, Val, Gly, Lys, Ser) has a Gly → Val substitution in position 12, compared to the normal cellular *H-ras-1* p21. The specificity of RAP-5 for *ras* p21 was established by protein blot (Western) and radioimmunoassay experiments, and was reported previously (13). This antibody reacts with both the normal human cellular Harvey, Kirsten (K), and neuroblastoma (N) *ras* p21, as well as with p21 molecules with a substitution at residue 12, e.g. T24 *H-ras*, *v-H-*

ras, *v-K-ras* (ref. 13 and unpublished results). The avidin-biotin complex immunoperoxidase assay (14) was performed on 4 μ m sections from formalin-fixed, paraffin-embedded tissue, as described previously (13), using reagents commercially prepared by Vector Laboratories, Burlingame, CA. A semiquantitative estimate of p21 expression was performed by serially diluting the primary antibody and determining the terminal dilution eliciting a 1+ reaction in the immunoperoxidase assay (i.e., a definite positive staining reaction above background levels). A reference slide exhibiting a 1+ reaction was used to score intensity of staining. Statistical analysis of anti-p21 titres in different histopathological groups was performed using a student's *t* test.

Results

Pattern of staining. The transitional epithelium of the normal adult human bladder has 3–7 layers, the most superficial layer composed of large, often multinucleated cells (umbrella cells). Immunoperoxidase staining of sections from normal bladder biopsies (obtained from transurethral resections of the prostate) from six patients without carcinoma demonstrated weak staining of only the most superficial cells (Fig. 1). This pattern of staining was not an “edge” artifact, since use of a number of melanoma-specific monoclonal antibodies as the primary antibody gave negative results. All bladder epithelial cells not in the superficial layer, as well as connective tissue cells, vascular endothelial cells, muscle, and nerve cells were easily identified in sections from the bladder and surrounding tissues, and were consistently negative. In the three biopsies showing hyperplasia (increase in cell layers without significant nuclear abnormalities), the pattern of p21 staining was identical to that seen in the normal bladder. Bladder biopsies from two patients with benign squamous metaplasia of the bladder epithelium were negative for p21, also. Sections from 14 biopsies demonstrated moderate to marked epithelial dysplasia, and were uniformly positive for p21 expression (Fig. 1). All five specimens showing carcinoma in situ were markedly positive for p21 staining (Fig. 1). Grade I papillary carcinomas have a normal epithelial structure, and the four specimens examined had a staining pattern similar to that seen in the normal urothelium. Higher grade malignancies demonstrated a uniformly intense staining for p21 throughout all sections examined, even when high dilutions of the primary antibody were used. Pelvic wall metastases from two patients with invasive grade III carcinoma were also studied. In both instances, the metastases had a similar staining intensity as the primary tumor. In contrast to previous studies of colon carcinoma, minimal tumor cell heterogeneity of p21 expression was noted (13). One exception to this general pattern of p21 staining in grade III carcinomas was found in sections from an invasive, markedly anaplastic bladder carcinoma. Multiple sections demonstrated heterogeneity of p21 staining with some neoplastic cells scoring negative (Fig. 1E). There was considerable necrosis in this area of the tumor, and we could not determine whether the heterogeneity of p21 expression was related to tumor cell viability, or was a reflection of the heterogeneity of tumor cell expression found with other tumor-associated phenotypic markers (15).

When sections from high grade carcinomas exhibiting positive immunohistochemical reactions were not counterstained with hematoxylin, p21-specific staining was either cytoplasmic, or clearly localized to the plasma membrane (Fig. 1F). This latter finding is consistent with ultrastructural studies that have

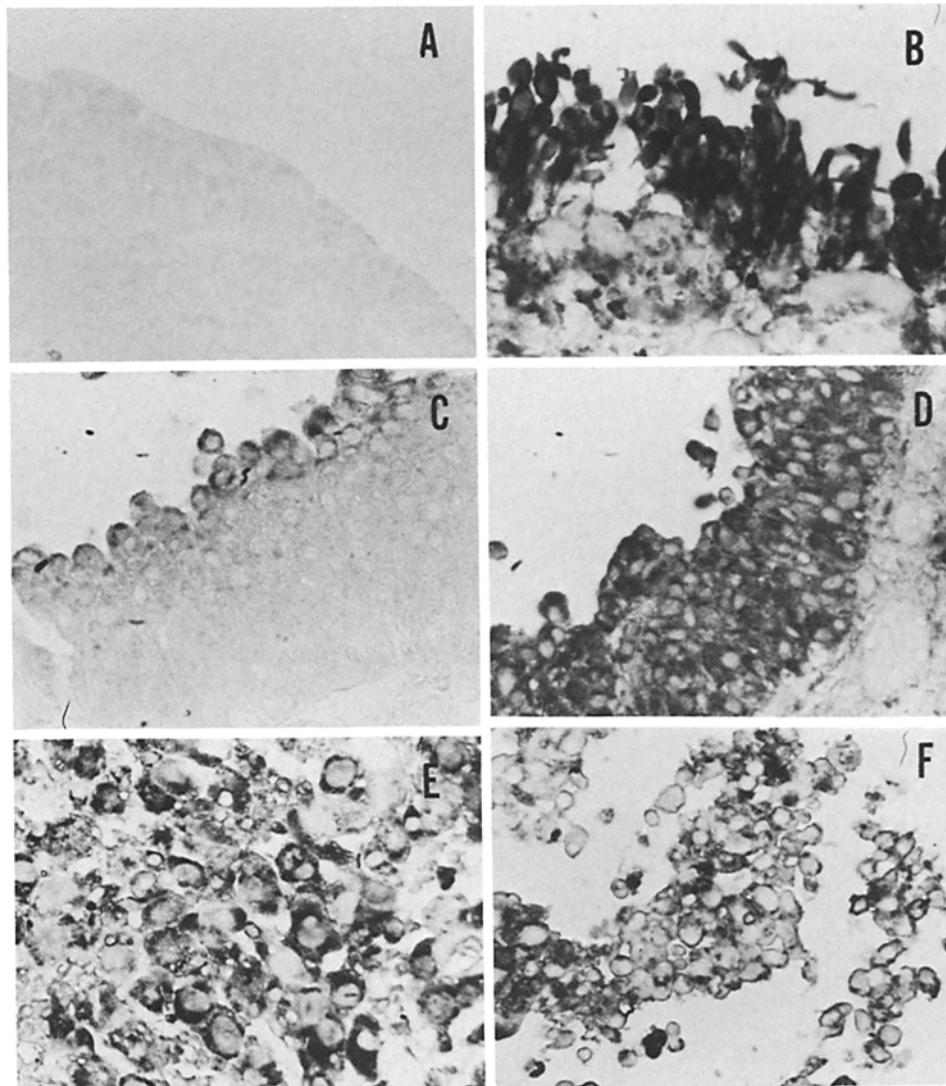


FIGURE 1. Immunoperoxidase staining of bladder biopsy sections for *ras* p21. The primary antibody, RAP-5, was used at a dilution of 1:1,000. The dark color represents a positive reaction of the diaminobenzadine substrate. All panels except *F* were lightly counterstained with hematoxylin. *A*, normal urothelium; *B*, carcinoma in situ; *C*, grade I papillary carcinoma; *D*, grade III papillary carcinoma; *E*, heterogeneity of p21 staining in markedly anaplastic bladder carcinoma; *F*, plasma membrane staining of grade III papillary carcinoma, no hematoxylin counterstain. All panels magnification 250 \times .

localized p21 to the inner surface of the plasma membrane (16). Control melanoma-specific antibodies did not react with sections of bladder carcinomas.

Quantitation of p21 Staining. We used serial dilutions of anti-p21 to determine endpoint titers on sections from bladder biopsies diagnosed as normal, hyperplastic, dysplastic, and carcinoma (Fig. 2). There were no significant differences in the mean titers found in sections with dysplasia as compared to grade III

with severe dysplasia and carcinoma in situ are at greatest risk for developing invasive carcinoma.

High grade carcinomas of the bladder exhibit a more malignant and invasive biological behavior, and have a poorer prognosis than carcinomas of a lower grade (21). Our findings of elevated p21 expression in high grade carcinomas suggest that neoplastic cells expressing *ras* p21 may have a growth advantage over other transformed cells, and a population of neoplastic cells expressing high levels of this oncogene product may evolve in more aggressive tumors.

These studies do not address whether the elevated levels of p21 we are detecting are products of a mutated *ras* gene. Although the original transformation gene isolated from the T24 bladder carcinoma line had a Gly → Val substitution of *H-ras-1* p21, this mutation was not found in 17 primary bladder carcinomas (9). Further, DNA from only 2 of 21 primary high grade bladder carcinomas scored positive in the mouse 3T3 transformation system, an assay which appears to have a bias for detecting *ras* p21 mutated at amino acid positions 12 and 61. Because we found that all high grade carcinomas examined expressed increased p21 antigen, it is likely that we are detecting the product of an unaltered cellular *ras* gene.

Summary

ras oncogene p21 antigen is present in the most superficial cells of the normal bladder urothelium, as demonstrated by immunohistochemical staining. The pattern and intensity of p21 staining of cells in epithelial hyperplasia and low grade bladder carcinoma were similar to that seen in the normal urothelium. In contrast, epithelial cells in "pre-malignant" (dysplastic) lesions and high grade carcinomas exhibited an intense staining reaction for p21 antigen. *ras* p21 may be a useful marker for the malignant potential of both pre-malignant lesions and carcinomas of the bladder.

References

1. Land, H., G. Paroda, and R. Weinberg. 1983. Cellular oncogenes and multistep carcinogenesis. *Science (Wash. DC)*. 222:771.
2. Tabin, C., S. Bradley, C. Bargmann, R. Weinberg, A. Papageorge, E. Scolnick, R. Dhar, D. Lowy, and E. Chang. 1982. Mechanism of activation of a human oncogene. *Nature (Lond.)*. 300:143.
3. Reddy, E., R. Reynolds, E. Santos, and M. Barbacid. 1982. A point mutation is responsible for the acquisition of transforming properties of T24 human bladder carcinoma oncogene. *Nature (Lond.)*. 300:149.
4. Taparowsky, E., Y. Suard, O. Fasano, K. Shemiju, M. Goldfarb, and M. Wigler. 1982. Activation of the T24 bladder carcinoma transforming gene is linked to a single amino acid change. *Nature (Lond.)*. 300:762.
5. Chang, E., M. Furth, E. Scolnick, and D. Lowy. 1983. Tumorigenic transformation of mammalian cells induced by a normal human gene homologous to Harvey murine sarcoma virus. *Nature (Lond.)*. 297:479.
6. Slamon, D., J. DeKernion, I. Verma, and M. Cline. 1984. Expression of cellular oncogenes in human malignancies. *Science (Wash. DC)*. 224:256.
7. Thor, A., P. Hand, D. Wunderlich, A. Caruso, R. Muraro, and J. Schlom. 1984. Monoclonal antibodies define different *ras* gene expression in malignant and benign

- colonic disease. *Nature (Lond.)*. 311:562.
8. Koss, L. G. 1979. Mapping of the urinary bladder. *Hum. Pathol.* 10:533.
 9. Feinberg, A., B. Vogelstein, M. Droller, S. Baylin, and B. Nelkin. 1983. Mutations affecting the 12th amino acid of *c-Ha-ras* oncogene product occur infrequently in bladder cancer. *Science (Wash. DC)*. 220:1175.
 10. Fujita, J., O. Yoshida, Y. Yuasa, J. Rhim, M. Hatanaka, and S. Aaronson. 1984. *Ha-ras* oncogenes are activated by somatic alterations in human urinary tract tumours. *Nature (Lond.)*. 309:464.
 11. Nagy, B., W. Frable, and W. Murphy. 1982. Classification of premalignant urothelial abnormalities. *Pathol. Annu.* 17:219.
 12. Mostofi, F. K., L. H. Sobin, and H. Torloni. 1973. Histological typing of urinary bladder tumors. In *International Histological Classification Tumors*. World Health Organization, Geneva. pp. 15–34.
 13. Hand, P. H., A. Thor, D. Wunderlich, R. Muraro, A. Caruso, and J. Schlom. 1984. Monoclonal antibodies with a predetermined specificity detect activated *ras* gene expression in human mammary and colon carcinomas. *Proc. Natl. Acad. Sci. USA*. 81:5227.
 14. Hsu, S. M., M. Raine, and H. Fanger. 1981. Use of avidin-biotin peroxidase complex (ABC) in immunoperoxidase techniques: A comparison between ABC and unlabeled antibody (PAP) procedures. *J. Histochem. Cytochem.* 29:557.
 15. Fidler, I., and I. R. Hart. 1982. Biological diversity in metastatic neoplasma: origins and implications. *Science (Wash. DC)*. 217:998.
 16. Willingham, M., I. Pastan, T. Shih, and E. Scolnick. 1980. Localization of the *src* gene product of Harvey strain of MSV to plasma membrane of transformed cells by electron microscopic immunocytochemistry. *Cell* 19:1005.
 17. Martin, B. V. 1972. Cell replacement and differentiation in transitional epithelium: A histological and autoradiographic study in the guinea pig bladder and ureter. *J. Anat.* 112:433.
 18. Campisi, J., H. Gray, A. Pardee, M. Dean, and C. Sonnenshein. 1984. Cell cycle control of *c-myc* but not *c-ras* expression is lost following chemical transformation. *Cell* 36:241.
 19. Goyette, M., C. Metropoulos, P. Shank, and N. Fauso. 1983. Expression of a cellular oncogene during liver regeneration. *Science (Wash. DC)*. 219:510.
 20. Brawn, P. 1984. The relationship between noninvasive papillary lesions and invasive bladder carcinoma. *Cancer (Phila.)*. 43:620.
 21. Bergkvist, A., A. Ljungqvist, and G. Moberger. 1965. Classification of bladder tumors based on cellular pattern: preliminary report of a clinical pathological study of 300 cases with a minimum followup of eight years. *Acta Chir. Scand.* 130:371.