

THE INFLUENCE OF ISOAGGLUTININS ON THE
FINAL RESULTS OF HOMOPLASTIC TRANS-
PLANTATIONS OF ARTERIES.*

By RAGNVALD INGEBRIGTSEN, M.D.

(From the Laboratories of The Rockefeller Institute for Medical Research,
New York.)

PLATES 16 AND 17.

Several investigators have reported that the functional results after homoplastic transplantation of arteries are excellent. But the microscopical examination of the transplanted segment, when made a long time after the operation, has given conflicting impressions as to the value of the transplantation. In several cases Carrel¹ found that after three to five months, not only the elastic framework, but even the muscular fibers of the median coat were in good condition.² Borst and Enderlen,³ on the other hand, observed a disappearance of the muscular fibers and a substitution of the transplanted segment by the connective tissue of the new host, just as in heteroplastic transplantation. Yamanouchi also found a degeneration of the segment when this was examined seventy-four days after the operation.

It is, of course, possible that differences in the technique of these operations may be responsible for the lack of uniformity in the results. But it is also possible that biological differences in the two animals concerned in each experiment were in some cases so great that they prevented the survival of the transplanted pieces.

It is not yet known why homoplastic transplantation does not usually succeed as well as autoplasmic. But in the experiments which

* Received for publication, April 23, 1912.

¹ Carrel, A., *Jour. Exper. Med.*, 1910, xii, 460.

² Capelle, A., *Berl. klin. Wchnschr.*, 1908, xlv, 2012. Capelle, Stich, Ward, and Wood had corresponding results, but their examinations of the segment were made within a somewhat shorter interval after the implantation.

³ Borst and Enderlen, *Deutsch. Ztschr. f. Chir.*, 1909, xcix, 54.

are published here, I have attempted to solve part of the problem, and even if the result is a negative one, it may still be of some interest.

In animals of the same species normal hemolysins or cytolysins have not been found, which may explain the biological differences in the individuals, and be made responsible for the disintegration and death of the homoplastic transplanted piece of tissue. We may conceive of the development of immune bodies under these conditions, but there is no evidence of their existence. Agglutination is the only serological reaction that is normally present between the serum of certain individuals and the red blood cells of others. This phenomenon has been rather thoroughly studied during the last few years, and the importance of the isoagglutinins in practical medicine has been increased by the development of direct transfusion of blood from man to man, as a routine measure.

Normal isoagglutinins of human red blood cells were discovered independently by Landsteiner⁴ and Shattock in 1900, and Landsteiner showed that all specimens of human blood could be divided into three groups according to the way in which they agglutinate. To these three groups a fourth was added by other investigators.⁵ Landsteiner then assumed that the four groups were explained by the existence of two different agglutinins, one of which was present in group 2, another in group 3, both in group 1, and none in group 4. Epstein and Ottenberg⁶ and von Dungern and Hirschfeld have discovered the interesting fact that the isoagglutinins are transmitted by heredity and follow the Mendelian law. Grouped isoagglutinins have been found also among lower animals. Ottenberg and Friedmann⁷ found grouped agglutinins in rabbits and cattle.

I have tried now to determine if the isoagglutinins exert any influence upon the final results of homoplastic transplantation of arteries.

⁴Landsteiner, K., *Wien. klin. Wchnschr.*, 1901, xiv, 1132; *München. med. Wchnschr.*, 1902, xlix, 1905.

⁵Landsteiner, K., and Leiner, K., *Centralbl. f. Bakteriol., Orig.*, 1905, xxxviii, 548.

⁶Epstein, A. A., and Ottenberg, R., *Proc. N. Y. Path. Soc.*, 1908, viii, 117; *Arch. Int. Med.*, 1909, iii, 467.

⁷Ottenberg, R., and Friedmann, S. S., *Jour. Exper. Med.*, 1911, xiii, 531.

First, I tried to find isoagglutinins in dogs, but without success. The same result is reported by Hektoen.⁸ After several fruitless experiments, that were hampered by the tendency of dog blood to lake, I began to work with cats.

The blood of forty cats was examined in four series, each of which contained ten animals, and the serum of each cat was tested against the red cells of all the other cats in the same group. In these experiments the technique described by Epstein and Ottenberg was used. One volume of a 5 per cent. suspension of erythrocytes in isotonic salt solution was mixed with two volumes of serum in capillary pipettes. The pipettes were incubated at 38° C. for two hours and then put in an ice box for twenty-four hours. Each series was in that way examined twice. The results are recorded in the following tables.

		Serum.									
		1	2	3	4	5	6	7	8	9	10
Blood Cells.	1	—	—	—	—	—	+	—	—	—	—
	2	—	—	—	—	—	+	—	—	—	—
	3	—	—	—	—	—	—	—	—	—	—
	4	—	—	—	—	—	+	—	—	—	—
	5	—	—	—	—	—	—	—	—	—	—
	6	—	—	—	+	—	—	—	+	—	—
	7	—	—	—	—	—	+	—	—	—	—
	8	—	—	—	—	—	+	—	—	—	•
	9	—	—	—	—	—	+	—	—	—	—
	10	—	—	—	—	—	+	—	—	—	—

		Serum.									
		11	12	13	14	15	16	17	18	19	20
Blood Cells.	11	—	—	—	—	—	—	—	—	—	—
	12	—	—	—	—	—	—	—	—	—	—
	13	—	—	—	—	—	—	—	—	—	—
	14	—	—	—	—	—	—	—	—	—	—
	15	—	—	—	—	—	—	—	—	—	—
	16	—	—	—	—	—	—	—	—	—	—
	17	—	—	—	—	—	—	—	—	—	—
	18	—	—	—	—	—	—	—	—	—	—
	19	—	—	—	—	—	—	—	—	—	—
	20	—	—	—	—	—	—	—	—	—	—

⁸ Hektoen, L., *Jour. Infect. Dis.*, 1907, iv, 297.

		Serum.									
		21	22	23	24	25	26	27	28	29	30
Blood Cells.	21	—	—	—	—	—	—	—	—	—	—
	22	—	—	—	—	—	—	—	—	—	—
	23	—	—	—	—	—	—	—	—	—	—
	24	—	—	—	—	—	—	—	—	—	—
	25	—	+	—	—	—	—	—	—	—	—
	26	—	—	—	—	—	—	—	—	—	—
	27	—	—	—	—	—	—	—	—	—	—
	28	—	—	—	—	—	—	—	—	—	—
	29	—	+	—	—	—	—	—	—	—	—
	30	—	—	—	—	—	—	—	—	—	—

		Serum.									
		31	32	33	34	35	36	37	38	39	40
Blood Cells.	31	—	—	—	—	—	+	—	—	—	—
	32	—	—	—	—	—	—	—	—	—	—
	34	+	—	—	—	—	+	—	—	—	—
	35	—	—	—	—	—	+	—	—	—	—
	36	—	—	—	—	—	—	—	—	—	—
	37	—	—	—	—	—	—	—	—	—	—
	38	+	—	—	—	—	+	—	—	—	—
	39	—	—	—	—	—	—	—	—	—	—
	40	—	—	—	—	—	—	—	—	—	—

The reaction was recorded as positive (+) only when, after macroscopical inspection, the agglutination was plainly seen on the first as well as on the second examination. In two or three cases the agglutination was very strong and occurred some minutes after the mixture had been made; but usually it was not marked until the next day; *i. e.*, after twenty-four hours in the ice chest.

As may be seen in the tables, the instances of agglutination are distributed among the cats without the slightest possibility of arranging the individuals in groups having the same characteristics.

In some of these cats a segment of the carotid artery (two centimeters long) of one was transplanted to the carotid of the other. In these operations I followed closely the technique described by Carrel. Fourteen transplantations were made; in five of them there was a positive agglutination test between the two animals, and in nine of them the agglutination test was negative. After the segment had been taken out, it was washed in Ringer's solution and then kept in vaselin at 38° C. until it was put in the new host, one half to three fourths of an hour later.

The operation and the convalescence in these fourteen cases were successful and uneventful. Infection and bleeding did not occur.

All of the fourteen transplanted segments were removed from the cat three months after they had been transplanted and were then examined microscopically. Of the five cats in which the agglutination test was positive, three had ideal functional results, and of the nine animals in which the agglutination tests were negative five had ideal functional results with good pulsation and no thrombosis of the artery. In the other six cases there was thrombosis of the artery and of the transplanted segment.

That thrombosis occurred in such a large percentage of the cases is not astonishing and is explained perfectly upon mechanical grounds. As the carotid artery in my cats was only one millimeter in diameter, the slightest stenosis or lack of approximation in suturing produced complete thrombosis of the whole lumen of the vessel.

I shall describe only the experiments in which the functional results were good, as it is not possible to draw conclusions of value from the microscopical examination of thrombosed arteries. Although the muscular fibers with which we are here especially concerned are exposed in thrombosed arteries to the blood serum of the new host and for this reason may show changes due to chemical influences or lack of proper nourishment, I have discarded them in these experiments since the muscular fibers in a thrombosed artery are inactive, and also are under abnormal conditions, both biologically and functionally.

INTERAGGLUTINATION POSITIVE.

Experiment 1.—January 25, 1912. From cat 25 a segment of the carotid artery 2 cm. long was taken and transplanted to the carotid artery of cat 22. The serum of cat 22 agglutinated the red cells of cat 25.

April 22. At the operation good pulsation was present in the carotid but there were some adhesions between the segment and the pneumogastric nerve. The segment was removed.

Microscopical Examination.—Adventitia and periadventitia were thickened, and richly vascularized. The median coat was of normal thickness, the muscular fibers and their nuclei were present in normal number and their appearance was quite normal. With Weigert's stain the elastic framework appeared normal. The internal coat was not thickened (figure 1).

Experiment 2.—December 14, 1911. A segment of the carotid artery of cat 1 was taken and transplanted to the carotid artery of cat 6. The serum of cat 6 agglutinated strongly the red cells of cat 1.

March 16. At the operation good pulsation was present in the carotid but the transplanted segment was bound by slight adhesions to the surrounding tissues. The segment was taken out.

Microscopical Examination.—The adventitia was thickened, richly vascularized, and contained several more lymphocytes than usual. The median coat was only half its normal thickness. All the muscular fibers and their nuclei had disappeared and the elastic framework layers were lying close to each other; the median coat contained nothing but elastic fibers. The internal coat was very much thickened (figure 4).

Experiment 3.—December 14, 1911. A segment of the carotid artery of cat 6 was transplanted to the carotid of cat 8. The serum of cat 6 agglutinated strongly the red cells of cat 8, and the serum of cat 8 agglutinated the cells of cat 6 only a little less strongly.

March 17, 1912. At the operation good pulsation was present in the carotid. There was no thrombosis, but adhesions were found between the segment and the internal jugular vein and the pneumogastric nerve. The segment was taken out.

Microscopical Examination.—The adventitia was thickened, and richly vascularized. The median coat was of normal thickness. In its outer layers the muscular fibers and their nuclei were normal in number and appearance. In its inner portion the fibers seemed a little atrophied and had taken only slightly the protoplasmic stain of Van Gieson. The nuclei had largely disappeared. There was no increase of the connective tissue; the elastic framework was normal; and the internal coat was slightly thickened.

INTERAGGLUTINATION NEGATIVE.

Experiment 4.—December 9, 1911. A piece of the carotid artery of cat 18 was transplanted to cat 19. Between these two cats the agglutination test was negative.

March 8, 1912. At the operation good pulsation was present in the carotid but there were adhesions to the vagus and the internal jugular vein. The segment was taken out.

Microscopical Examination.—The adventitia was considerably thickened, and consisted partly of thick hyaline connective tissue bundles. Around the small vessels, aggregations of lymphocytes were seen. The median coat was thin and flattened. Almost all of the muscular fibers and their nuclei had disappeared. The elastic framework layers were lying close to each other, and the internal coat was covered by a thin layer of amorphous fibrin.

Experiment 5.—January 4, 1912. A piece of the carotid artery of cat 4 was transferred to cat 9. The agglutination test between these two cats was negative.

April 3. At the operation good pulsation was felt in the carotid but there were adhesions to the surrounding tissue. The segment was taken out.

Microscopical Examination.—The adventitia was thickened and richly vascularized. The inner layers were sclerotic. The median coat was a little thinner than normally. In the inner portion the muscular fibers had disappeared. In the outer portion they were still present in almost normal number.

The fibers were atrophied, their nuclei were not very distinctly stained, and their outlines were not sharp. The elastic framework was normal. In the internal coat there were three to four layers of connective tissue cells; in other places the internal coat was not thickened.

Experiment 6.—January 3, 1912. A piece of the carotid artery of cat 11 was transplanted to cat 12. The agglutination tests between these animals were negative.

April 5. At the operation good pulsation was felt in the carotid but there were adhesions between the segment and the surrounding tissue. The segment was taken out.

Microscopical Examination.—The adventitia was much thickened and richly vascularized in the outer layers; the inner layers were partly sclerotic. The median coat was of normal thickness. In the outer layers there were a normal number of muscular fibers, but in the inner layers these had partly disappeared. The elastic framework was normal. The internal coat was a little thickened and had three to four layers of connective tissue cells.

Experiment 7.—January 9, 1912. A piece of the carotid artery of cat 14 was transplanted to the carotid artery of cat 15. The agglutination tests between these two animals were negative.

April 14. At the operation good pulsation was felt in the carotid but there were adhesions to the internal jugular vein and the pneumogastric nerve. The segment was taken out.

Microscopical Examination.—The adventitia was greatly thickened. The median coat was thin and flattened and consisted almost exclusively of the elastic framework, the muscular fibers having disappeared for the greater part. The internal coat was slightly thickened by the development of very thin elastic fibers.

Experiment 8.—January 11, 1912. A piece of the carotid artery of cat 24 was transplanted to the carotid artery of cat 26. The agglutination tests between these two animals were negative.

April 13. At the operation good pulsation was felt in the carotid but there were adhesions to the surrounding tissue. The segment was taken out.

Microscopical Examination.—The adventitia was thickened, but the median coat was thinner than normally. Many of the muscle fibers had disappeared; the elastic framework was normal, and the internal coat was a little thickened.

The sections of the arteries were stained with Van Gieson's stain, with Weigert's elastic tissue stain, and with hematoxylin and eosin.

Results.—In all of the transplanted arteries examined three months after transplantation, there was a thickening of the external coat and a persistence of the elastic fibers of the median coat. Further I found in most of the cases a more or less pronounced thickening of the internal coat.

Very often the external coat had thickened until it was three times its normal size. The new layers of connective tissue had the appearance of cicatrizing tissue; the external coat was somewhat infil-

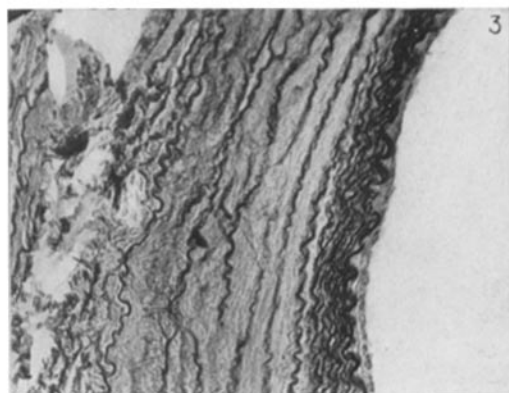
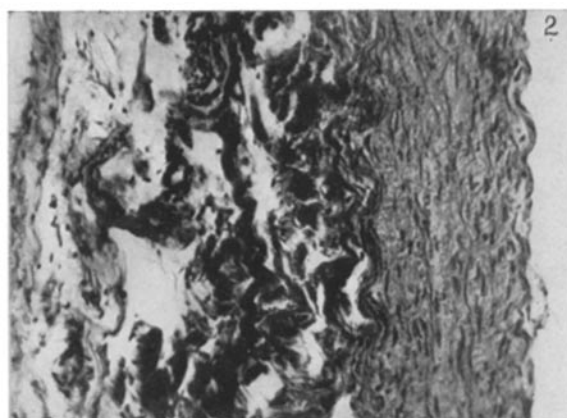
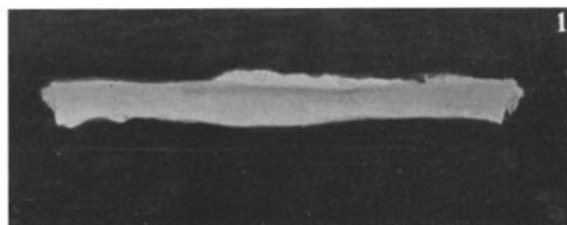
trated by round cells and many small vessels were seen, in the walls of which lymphocytes were aggregated. The bundles of connective tissue were thick, and the inner layers were partly hyaline and sclerotic.

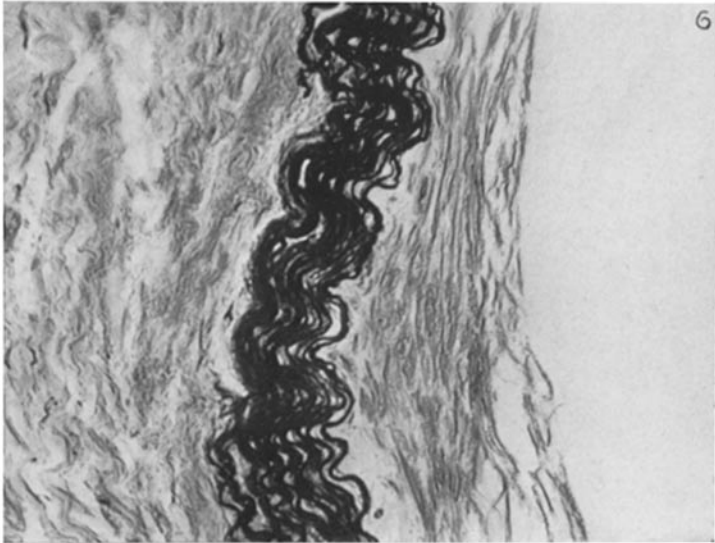
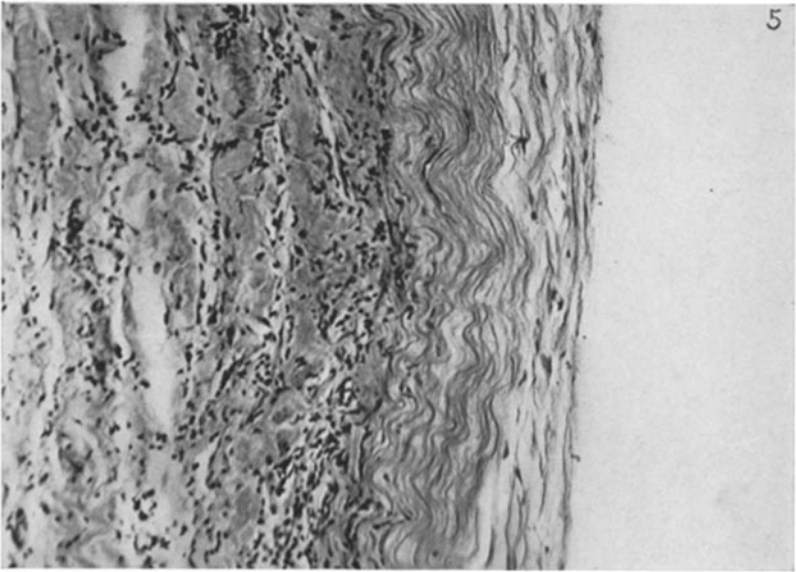
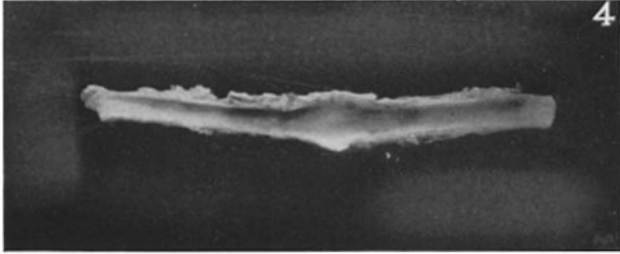
The elastic framework of the median coat was always found in good condition; splitting of the fibers or the formation of granules was not observed. The appearance of sections stained by Weigert's elastic tissue stain, however, was influenced by the presence or absence of the muscle fibers. If all of the muscle fibers had disappeared, the elastic fibers and layers were pressed together and lay closely to each other without any tissue between them. The median coat as a whole was very thin (figure 2). If, on the other hand, the muscle fibers were present, the elastic framework had quite a normal appearance (figure 3). In no case was a proliferation of cells of any kind, or a formation of new tissues within the median coat observed. In most of the cases the smooth muscle fibres of the median coat had partly disappeared.

There were some few features of interest. In the first group of transplantations (three experiments with positive interagglutination) the muscle fibers were apparently quite normal in appearance and number in experiment 1, and also perhaps to a less extent in experiment 3, while in experiment 2 these fibers had completely disappeared (figures 1, 2, and 3). Experiments 1 and 2 are within the same group and yet are at opposite extremes as far as the muscular fibers are concerned. Experiment 2 was the one in which the isoagglutination was strongest, but that this coincides with the most complete disappearance of muscular fibers must be considered accidental, because the other two experiments in the same group show muscular fibers in a very good condition.

In the second group (five experiments, in which interagglutination was negative) the results in the different experiments corresponded more closely. Here most of the muscular fibers, but not all had disappeared, and as a general feature it was observed that they had disappeared in the inner layers of media, while they were still present in the outer.

The thickening of the internal coat went parallel with the disappearance of the muscle fibers of the median coat; the strongest





increase was seen in experiment 2 where all of the muscle fibers had disappeared. In experiment 1 where all of the muscle fibers were present, the internal coat was thickened but little (figures 1 to 6).

CONCLUSIONS.

The results in the group in which there was interagglutination differ in no striking way from those obtained in the group in which there was no interagglutination. It may be concluded, therefore, that the presence of isoagglutinins is of no importance for the final results of the homoplastic transplantation of arteries. From the conflicting evidence of the survival of muscular fibers in one case and their disappearance in many other cases, it may be concluded further that between animals of the same species there are unknown biological differences that prevent, in most instances, the survival of homoplastic transplanted arteries, although a survival does occur in some cases.

EXPLANATION OF PLATES.

PLATE 16.

FIG. 1. Gross appearance after three months of a segment of a carotid artery transplanted from cat 25 to cat 22. Agglutination test positive.

FIG. 2. Transverse section of the segment. Internal coat not thickened. The median coat has the normal number of muscle fibers and nuclei. The external coat is somewhat thickened. Van Gieson's stain.

FIG. 3. Transverse section of the same specimen. Internal coat slightly thickened here. Weigert's elastic tissue stain.

PLATE 17.

FIG. 4. Gross appearance after three months of a segment of a carotid artery transplanted from cat 6 to cat 1. Agglutination test positive. The suture lines can hardly be seen.

FIG. 5. Transverse section of the transplanted segment. The internal coat is very thick. The median coat is thin without muscle fibers. The external coat is very thick and infiltrated by round cells. Van Gieson's stain.

FIG. 6. Transverse section from the same specimen. Weigert's elastic tissue stain.