

THE SPORADIC OCCURRENCE IN CARDIAC MUSCLE OF ANOMALOUS Z BANDS EXHIBITING A PERIODIC STRUCTURE SUGGESTIVE OF TROPOMYOSIN

DON W. FAWCETT. From the Department of Anatomy, the Harvard Medical School, Boston, Massachusetts 02115

Shy et al. (10) described the case of a 4 yr old girl suffering from a familial, nonprogressive weakness of the proximal muscles of the extremities. Upon biopsy the muscle fibers were found to contain elongate, rodlike bodies with a fibrillar structure and a fine periodic cross-striation. This condition was considered to be a new congenital myopathy and was given the name "nemaline myopathy," a term intended to be descriptive of the characteristic thread or rodlike inclusions found in biopsies. Several other cases have since been reported (Engel et al., reference 1; Gonatas et al., reference 3; Price et al., reference 8; Spiro and Kennedy, reference 11), and further study of electron micrographs has shown that, in addition to the rodlike inclusions, the Z bands often exhibit fusiform expansions up to several times the normal width of this band. These unusually broad Z bands are reported to exhibit a pattern of fine, transverse striations, ~ 175 A apart, similar to those seen in the inclusions.

Because this form of pathology of skeletal muscle is now attracting considerable attention, both among students of muscle fine structure and among clinicians who consider it to be pathognomonic of nemaline myopathy, it is thought to be of some importance to describe a similar disturbance of Z band structure observed some time ago in certain fibers of the right ventricular papillary muscle in the hearts of aging but otherwise healthy cats.

The occasional observation of periodic structure in the Z band casts doubt upon one of the interpretations of its normal organization and provides further support for the suggestion that at least part of the tropomyosin of striated muscle is localized in the Z band.

OBSERVATIONS

The structures described here were encountered in the course of studies on the normal fine structure of the cardiac muscle in three large tomcats. The age of the animals was not known but, from the abundance of lipochrome pigment in the myo-

cardium, they were judged to be several years old. The tissue, fixed in phosphate-buffered 1% osmium tetroxide, was embedded in Epon, and thin sections of the blocks were stained with uranyl acetate and lead citrate.

In the myocardium of three animals, cells were occasionally observed in which many of the Z bands were of variable width and irregular shape (Fig. 1). All the other bands were of normal breadth and appearance. The defect involved many but not all of the sarcomeres throughout the length of the cell. Neighboring cells were usually entirely normal. In the affected cells some Z bands were of the usual dimensions, 600–800 A, while others were as much as 1μ in length. In some instances a Z band was of normal size for part of its transverse extent but greatly enlarged for the remainder of the width of the myofibril (Fig. 2). The broadening of the Z band was not at the expense of the I filaments, inasmuch as the broad, irregular regions of the Z bands were flanked by half I bands only very slightly narrower than would be expected were the Z bands of normal size. Thus, if measured from the edge of the Z band, the sarcomere length was within normal limits. However, the interposition of a Z band, 0.5–1.0 μ long, tended to put the A bands out of lateral register with those of neighboring myofibrils having Z bands of normal width. At high magnification the anomalous Z bands exhibited a fine cross-striation with a regular repeating period of ~ 200 A (Fig. 1, inset). The images of these Z bands bear a very close resemblance to published electron micrographs of sections of tropomyosin crystals which also have regular cross-striations with a period of about 200 A (Hodge, reference 4).

DISCUSSION

There can be no doubt that the naturally occurring broad Z bands reported here are the same as those previously reported in cases of nemaline myopathy. There are, however, discrepancies in




FIGURE 1 An electron micrograph of an anomalous cardiac muscle cell of the right ventricular papillary muscle of a cat shows Z discs of highly variable width. In all other respects the muscle fiber appears entirely normal. At high magnification (see inset) the abnormal Z bands exhibit a regular cross-striation with a period of about 200 Å. In the upper part of the inset, several lines have been superimposed on the dark, transverse striations of the micrograph to aid the reader in recognizing the repeating period in the Z band. $\times 33,000$.

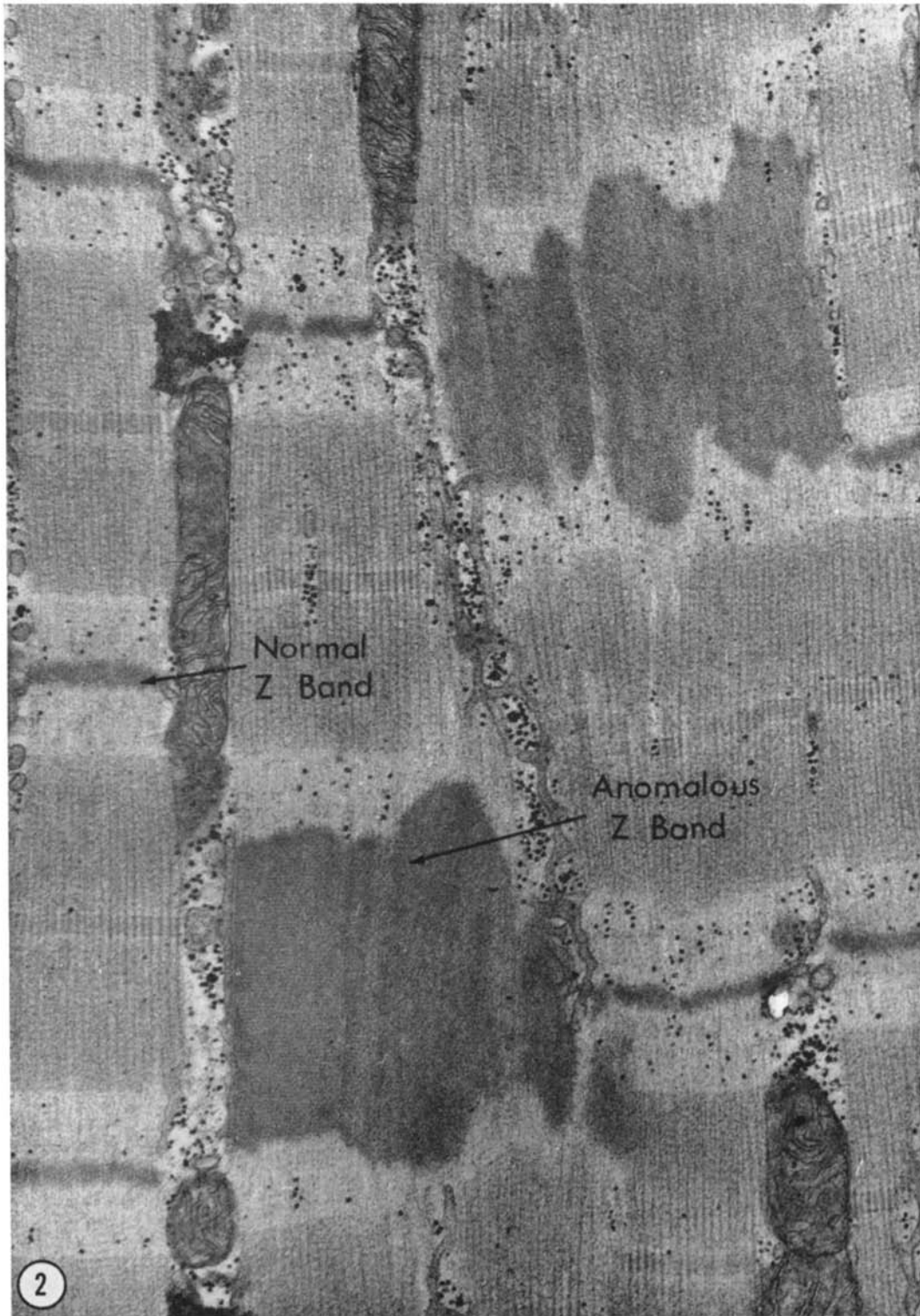


FIGURE 2 A portion of a muscle fiber in which certain of the Z bands are of normal dimensions while others are nearly as long as the A bands. These unusual Z bands found occasionally in cardiac muscle of cats are apparently identical with those reported in the human disease, nemaline myopathy. $\times 33,000$.

the reported length of the repeat period. Values of ~ 145 – 175 Å reported for nemaline myopathy are considerably less than the ~ 200 Å reported here. The explanation for these differences is not clear, but there are several possibilities. The measurements may have been affected by differences, from one study to another, in shrinkage during dehydration, compression effects related to differences in direction of cutting with respect to the fiber axis, or slight obliquity of the plane of section. All the papillary muscles in the present study were fixed in the stretched condition. Whether this could affect the length of the period in the Z band is not known. In any case, the observations reported here establish that at least one of the defining characteristics of the human heritable disease nemaline myopathy, namely the abnormally broad Z bands exhibiting periodic fine structure, is not confined to this condition but can occur in occasional cardiac muscle fibers of apparently normal cats. Therefore, this structural aberration cannot be regarded as a specific genetically determined defect of human skeletal muscle development.

Huxley in 1963 (5) published micrographs of very thin crystals of tropomyosin that form under certain conditions *in vitro* and present an approximately square lattice with a unit cell about 200 Å on a side, which bears a rather striking resemblance to the pattern seen in transverse sections through the Z band of striated muscle. Unfortunately, in the present study, no cross-sections through anomalous Z bands were encountered and all of the figures are therefore of longitudinal sections. Although the repeat period is approximately the same, the images of the present study are not comparable to those of Huxley since his micrographs provide no information on the repeat of his tropomyosin crystals in the third dimension which would most likely correspond to longitudinal sections of the Z bands. However, Hodge in 1959 (4) examined thin, presumably longitudinal, sections of tropomyosin crystals prepared under conditions somewhat different from those used by Huxley and also reported a 200 Å period. The similarity in measured length of the period and the very striking resemblance between his micrographs and those of the anomalous Z bands reported here can surely be regarded as additional suggestive evidence for the occurrence of tropomyosin in the Z bands of striated muscle.

The findings reported here have further inter-

esting implications for interpretation of the structural organization of the Z disc. It is now accepted that the I filaments do not continue through the Z line, but opinions differ as to how they terminate there. The relationship of the I filaments in successive sarcomeres also remains obscure. In transverse sections, the actin filaments near the Z disc are observed to be arranged in square array. The two sets of I filaments approaching the disc from opposite sides are not in register but are offset so that the filaments on one side of the Z line are opposite the centers of the squares whose corners are defined by the filaments of the other set (6). According to Knappeis and Carlsen (7) each actin filament approaching the Z band is continuous with four slender Z filaments that diverge and pass diagonally through the band to connect with four other actin filaments approaching the Z band from the other side. The oblique orientation of the Z filaments connecting the two offset arrays of actin filaments is believed to account for the characteristic zigzag appearance of the Z band in longitudinal sections of muscle.

Franzini and Porter (2) have raised the following objections to this interpretation. The Z filaments do not appear appreciably thinner than the I filaments as would be expected if they arise by dissociation and branching of subunits of the I filaments. Moreover, the apparent continuity of the I filaments with four Z filaments would suggest that the I filaments are made up of four subunits, whereas the electron microscopic and X-ray diffraction evidence on isolated actin filaments establishes the presence of only two subunits in each filament. Neither of these objections would hold if the Z-filament lattice were assumed to be a distinct structural entity to which the actin filaments are merely attached. Nevertheless, Franzini and Porter (2) have felt it necessary to offer an alternative interpretation of the zigzag configuration of the Z disc observed in longitudinal sections. They question the reality of the Z filaments and suggest instead that the Z disc is composed of a sheet or membrane of more or less amorphous material into which the I filaments are inserted. The zigzag configuration of the disc is considered by them to represent a section of this Z membrane drawn up into conical or pyramidal peaks at the points of insertion of the two opposing sets of actin filaments. The present observations facilitate a choice between these competing interpretations, for it would be

difficult to account for the broad cross-striated Z bands described here on the basis of deformation by traction on a membrane or sheet. The present findings, therefore, seem to favor the interpretations of Knappeis and Carlsen (7) or of Reedy (9). It seems likely that the anomalous Z bands of nemaline myopathy and those described here in cardiac muscle are a consequence of excessive production of Z substance, probably containing tropomyosin, and result from rearrangement of Z fila-

ments and their lateral association to form broad cross-striated bands instead of the lattice typical of the normal Z disc.

Research supported by research grant GM-06729 from the Institute of General Medical Sciences, National Institutes of Health, United States Public Health Service.

Received for publication 20 July 1966, and in revised form 7 September 1967.

REFERENCES

1. ENGEL, W. K., T. WANKO, and G. M. FENICHEL. 1964. Nemaline myopathy: second case. *Arch. Neurol.* 11:22.
2. FRANZINI-ARMSTRONG, C., and K. R. PORTER. 1964. Z-disc of skeletal muscle fibrils. *Z. Zellforsch. Mikroskop. Anat.* 61:661.
3. GONATAS, N. K., G. M. SHY, and E. H. GODFREY. 1966. Nemaline myopathy: the origin of nemaline structures. *New Engl. J. Med.* 274:535.
4. HODGE, A. J. 1959. Fibrous proteins of muscle. *Rev. Mod. Phys.* 31:409.
5. HUXLEY, H. E. 1963. Electron microscopic studies on the structure of natural and synthetic protein filaments from striated muscle. *J. Mol. Biol.* 7:281.
6. HUXLEY, H. E. 1965. Structural evidence concerning the mechanism of contraction in striated muscle. In *Muscle*. W. H. Paul, E. E. Daniel, C. M. Kay, and G. Monckton, editors. Pergamon Press, Inc., New York. 5-29.
7. KNAPPEIS, G. C., and F. CARLSEN. 1962. Ultrastructure of Z-disc in skeletal muscle. *J. Cell Biol.* 13:323.
8. PRICE, H. M., G. B. GORDON, C. M. PIERSON, T. L. MYUSAT, and J. M. BLUMBERG. 1965. New evidence for excessive accumulation of Z-band material in nemaline myopathy. *Proc. Natl. Acad. Sci. U. S.* 54:1398.
9. REEDY, M. K. 1964. Discussion on article by J. Hanson and J. Lowy. *Proc. Roy. Soc. (London) Ser. B.* 160:458.
10. SHY, G. M., W. K. ENGEL, J. E. SOMERS, and T. WANKO. 1963. Nemaline myopathy: new congenital myopathy. *Brain.* 86:793.
11. SPIRO, A. J., and C. KENNEDY. 1965. Hereditary occurrence of nemaline myopathy. *Arch. Neurol.* 13:155.