

## A STUDY OF EPIDERMAL FIBRILS.

By R. L. THOMPSON, M. D.

(Associate Professor of Pathology, St. Louis University.)

(From the Pathological Laboratory, St. Louis University Medical Department).

PLATE XXIII.

When the epidermis\* is appropriately stained delicate fibrils can be seen in the stratum filamentosum. These fibrils go out from the protoplasm of the cells in different directions and across the intercellular lymph spaces to enter neighboring cells, so that all the cells of this layer are bound together by a delicate fibre system. The departure of the fibrils from the cells gives them the appearance of a thorn-like border whence they have derived the name "prickle" cells. These fibrils, which have been termed intercellular bridges, present in their middle part a slight enlargement, which is known as the Ranvier-Bizzozero nodule. They are not confined wholly to the stratum filamentosum but also may be seen joining together many of the basement cells. In addition to these connecting fibrils there may be seen in the stratum germinativum longer, thicker, more deeply staining protoplasmic fibrils, which run parallel to the long axis of the

\* In the human epidermis seven layers are recognized by Ehrmann and Fick (*Einführung in das mikroskopische Studium der normalen und kranken Haut*. Wien, 1905). From below upward they are designated as follows: 1. Stratum germinativum. 2. Stratum filamentosum. 3. Stratum granulosum. 4. Stratum intermedium. 5. Stratum lucidum. 6. Stratum corneum. 7. Stratum disjunctum. The lower cells (stratum germinativum) are placed perpendicular to the corium; they have large, oval, vesicular nuclei with considerable chromatin; the shape of the cells varies from that of a cube to that of a slender high cylinder; they are closer together than in the layer above but are separated by narrow lymph channels. This layer passes insensibly into the stratum filamentosum, the cells becoming larger and more polygonal in shape; the nuclei are larger, rounder, and do not stain so deeply as the nuclei of the basal cell row. The channels between the cells are wider than below. Above this layer the cells are flatter and show granules of kerato-hyalin and finally become fused together and disintegrate. They need not be further described as only the lower two layers are to be considered in this paper.

cells. These fibrils frequently are distinctly spiral in form. They may follow the contour of the nucleus and be wholly within the cell or they may lie at the edge of the cell or in the lymph space between the cells. They appear to be wholly distinct from the fibrils first described. In the normal epidermis these latter fibrils are few and they may be wholly absent in many sections. It is in certain pathological conditions, however, that these fibrils assume importance and offer the basis for the present study.

Among the numerous articles that have appeared concerning these fibrils only the more important need be noted.

In 1863, Schroen<sup>1</sup> described in the rete Malpighii of the epidermis "scalariform striæ," which he considered a part of the cell membrane "with pores to let in nourishment." Max Schultze,<sup>2</sup> in 1864, observed "projections" from the cells of the mesial zone of the epidermis and was the first to apply to these cells the name of "prickle (*Stachel*) cells." He believed that these spines "gripped one another as bristles do when two brushes are pressed together." An important contribution was made by Bizzozero<sup>3</sup> (1871), who first noted the minute thickenings or nodules on these spines. These nodes he considered to be the point of union of two fibrils "welded together end on end." Ranvier<sup>4</sup> (1879) also studied these fibrils and said, "The cells of the rete Malpighii are not individual but are united by protoplasmic filaments. Each of these filaments is the result of the union of two filaments end on end, and the nodule is the result of their union." The nodule Ranvier further considered to be an elastic organ permitting easy enlargement of spaces destined for circulation of lymph between the cells. In 1882, Ranvier<sup>5</sup> published a second article, in which he described these fibrils as "filaments of union absolutely continuous," instead of being two fibrils united end on end.

Up to this time all discussion as to epithelial fibres had centred about these protoplasmic "bridges" or "spines" of the rete Malpighii. In 1889, Herxheimer,<sup>6</sup> by aid of the then new Weigert fibrin stain, described a new variety of fibril which he found running parallel to the long axis of the cells of the lower layers of the epithelium (stratum germinativum). He did not reach a conclusion concerning the significance of these fibrils, but Eddowes,<sup>7</sup> working in Unna's laboratory, came to the conclusion that these Herxheimer fibrils were only fibrin-filled lymph spaces. A year later, Kromayer<sup>8</sup> turned his attention to these fibrils. He used a modification of the Weigert stain which apparently resulted in a better picture than Herxheimer had obtained. Kromayer considered these fibres to be true protoplasmic fibrils, and not artifacts. In addition to the Herxheimer fibrils he also described a special fibril (*Haftfaser*) extending into the corium and possibly serving to join the corium to the epidermis. Some of the fibrils Kromayer described as having a corkscrew shape.

Kromayer's views were strongly opposed by various investigators. Beneke<sup>9</sup> believed these fibrils to be only a part of the cell membrane. Schütz<sup>10</sup>

considered Kromayer's fibres to be only the well-known "Ranvier" fibres altered by the staining method used. This author also considered Herxheimer's fibres to be an artifact. In the same year Herxheimer and Müller,<sup>11</sup> by aid of Weigert's neuroglia stain, reached the conclusion that these basal fibres represented the cuticular membrane of the cells and that the fine protoplasmic fibrils might be differentiated protoplasm.

Rabl<sup>12</sup> (1897) investigated these fibrils and considered the spiral form of the Kromayer fibrils an artifact. Rabl believed that the fibrils were formed by the coalescence of numerous finer fibrils which through shrinkage became a compact, broad fibre. Kromayer,<sup>13</sup> in a later paper, defended the "corkscrew" fibre, which he considered a distinct fibril in no way to be considered a part of the cell membrane. Herxheimer<sup>14</sup> also devoted a later paper to these fibrils which he described as being produced from a certain specific part of the cell protoplasm.

Unna<sup>15</sup>, who has contributed several articles on these fibrils, in a recent paper devoted in great part to a consideration of a new stain gives us some excellent pictures of the various fibrils of the epidermis. Unna believes that the Herxheimer and similar fibrils are a part of the general fibre system.

It will be seen from the foregoing that there is still considerable dispute regarding the nature and significance of these fibrils. Although at first some observers considered the basement fibrils as artifacts, the later observers agree that they are true fibrils. The spiral form, however, that certain fibres assume is considered by some artificial. There is a dispute as to whether the fibres are a product of the protoplasm of the epithelial cells. By some they are considered merely the differentiated cuticular membrane, by others a condensation of the fibrillar ground substance of the cells. Moreover, it is a disputed question whether these fibrils are all a part of one general system, or whether the various fibrils are to be considered separate and distinct. While the fibrils of the basement layer are described in conditions incident to epithelial proliferation there seems to be no stress laid on the relation of fibre production to cellular activity.

The different views regarding these fibrils may be accounted for, in part at least, by the somewhat complicated technic by which they have been studied. Previously the Weigert fibrin stain or some of its modifications, such as the Kromayer stain, or Unna's method have been used for their demonstration. All these methods are, however, extremely complicated, and admit

of good results only after considerable practice. Fischel<sup>16</sup> has recently described a modification of the Kromayer stain that shortens the process somewhat, but is still far from simple.

For the demonstration of these fibrils the phosphotungstic acid hematoxylin stain,\* as described by Mallory<sup>17</sup> for fibroglia fibrils, was used. Two methods were employed in the examination of tissues, as follows:

*Method A.*—1. Fix in Zenker's fluid; small pieces of skin are stretched out on filter paper and placed in the fluid immediately after excision.

2. Transfer celloidin or paraffin sections from water to a one-fourth per cent. aqueous solution of permanganate of potassium for from five to ten minutes; wash in water; place in a five per cent. solution of oxalic acid for from fifteen to thirty minutes; then wash thoroughly in water.

3. Stain in phosphotungstic acid hematoxylin for from twelve to twenty-four hours; wash quickly in water; dehydrate in alcohol; clear in xylol, and mount in xylol balsam.

*Method B.*—1. Fix freshly excised pieces in four per cent. formaldehyde (ten per cent. formalin). 2. Stain frozen sections, without mordanting, in phosphotungstic acid hematoxylin for from thirty minutes to four hours.

3. Immerse in water, alcohol, xylol, and xylol balsam as before.

For routine study the Zenker-fixed material was used and in most cases both paraffin and celloidin sections made. By this method the epidermal fibrils are stained a deep blue. The intercellular connective-tissue fibrils of the corium are pale brownish red. The nuclei of the cells are stained blue.

In addition to the sections that were prepared as above, frozen sections were made by Method B and carried along for the purpose of comparison. These sections were a considerable help in the study. When properly stained by this method everything in the section with the exception of the epidermal fibrils is a pale brownish red, while the fibrils are a deep blue. This gives a contrast that is not obtained by Method A. The objection to this method is, however, that at times there is inadequate fixation, and therefore loss of fibrillar structure, which the Zenker-

\* It is necessary to use a well ripened stain to get good results. Mallory suggests the addition of an oxidizing agent, such as a small amount of peroxide of hydrogen, if the solution does not stain. In this work a stain somewhat over a year old was used. The staining time, as given here, may have to be prolonged if a less intense stain is used.

fixed material does not suffer. I can account for this only by the fact that the quality of commercial formaldehyde solutions cannot be depended on. If one could feel certain of the fixation, the simplicity of this technic, the quicker action of the stain, and the better contrast in the sections, would make it commendable. It is at any rate essentially practical for a rapid demonstration of epidermal fibrils in freshly excised tumors of the skin.

In the course of variola diagnosis in which both the above methods were employed, these fibrils of the epidermis were first noted. This simple technic, which seemed to obviate as far as possible all artifacts and to permit a fairly strict construction of the pictures obtained, seemed so well adapted to their study that a systematic effort was made to obtain various skin sections, which might offer some points of interest to our knowledge of the epidermal fibre system. In common with many other histologic and pathologic problems it was assumed that a preliminary study of these fibrils in animals would be of service in their final interpretation. Herxheimer (*loc. cit.*) has stated that in the animals which he examined (rabbit, rat, and guinea-pig) the long fibrils of the basal cells were wanting.

By permission of Mr. Frank Hagenbeck and by assistance of Dr. R. B. H. Gradwohl, to whom I wish to express my indebtedness, I was enabled to obtain skin sections from a number of the animals in the Hagenbeck zoological collection. Sections of skin from twelve animals were examined.

In regard to the cells of the epidermis of these animals it may be said that usually the different layers as described in human epidermis can be made out. There may be, however, a poor development of any one of the layers. Some animals show a sudden transition from stratum germinativum to stratum granulosum, with little development of the polygonal cells of the stratum filamentosum. Others show the polygonal cells extending to the corium with only occasional suggestion of cells of a columnar type in the stratum germinativum. In regard to the fibres, however, there is a considerable divergence, especially in certain of the animals, from the picture seen in human epidermis. In

all the animals excellent pictures are obtained of the connecting fibrils of the stratum filamentosum. They appear more prominently than they do in similarly stained sections of human epidermis. It is in the stratum germinativum that the difference between animal and human skin and among the skins of the various animals examined is to be noted. This difference is in the development of the fibrils of the basement layer and therefore a separate description of these fibrils follows:

*Kangaroo (Macropus major)*.—Only an occasional fibril is seen, extending from the corium to the upper pole of the nucleus in one of the lower rows of cells. The cells of the basement row are not distinctly columnar in this animal.

*Puma (Felis concolor)*.—Basement fibrils are rarely seen. Epithelial cells are flattened and the epidermis is only two or three cell layers deep. This skin was taken from a young animal.

*Tapir (Tapirus indicus)*.—There is better development of the cells than above, and quite a number of short, sometimes wavy, fibrils are present in and between cells of the basement row.

*Fat-tailed sheep (Ovis aries steatopyga)*.—The epidermis here is poorly developed, but an occasional wavy fibril may be seen, usually lying at the edge of the cell.

*Water deer (Hydropotes inermis)*.—Several fields in the section show groups of the fibrils both within and at the edge of the lower cells. Occasionally a fibril extends into the second cell row.

*Guanaco (Auchenia huanaco)*.—In general the fibrils are absent, but about the hair follicles, especially, occasional well developed fibrils are seen. One cell in mitosis shows two fibrils embracing the nucleus on either side.

*Angora (Capra ancyrana)*.—In this skin numerous fibrils can be seen both in and between the cells of the basement row, some extending into the corium and some extending into the mesial zone of flattened cells. Many of these fibrils are of a distinct corkscrew shape. They lie for the most part at the edge of the cells. Some are in lymph spaces between the cells.

*Camel (Camelus dromedarius)*.—This skin was taken from a young animal and shows fair fibre development. The fibrils are seen only in certain parts of the section. The lower cells are usually flat rather than columnar, and certain fibres can be seen running parallel to the corium instead of perpendicular to it as is usually the case.

*Axis deer (Rusa indica)*.—In certain areas a few fibrils are seen, rarely extending above the second cell row. The fibrils here lie for the most part at the cell edge.

*Llama (Auchenia llama)*.—There is even better development here of the basement fibrils than in the section last described. The fibrils are practically everywhere present but certain areas show especially thick grouping. Some of the fibres are quite broad, and are for the most part straight, or rather,

lightly curved, in conformity with cell contour. They appear most frequently at the edges of the cells.

*Zebra* (*Equus montanus*) (Fig. 1).—Here the fibres are still more prominent and quite generally distributed. They may be seen both within and at the edges of the basement cells. Some of the fibrils run through the cells of the second row and end in the third row of cells. Very distinct spiral and corkscrew forms may be seen.

*Elephant* (*Elephas africanus*) (Fig. 2).—The cells of the epidermis are here somewhat crowded together, due apparently to the pressure of the thick, horny layer. The basement fibrils are everywhere present and more strongly developed than in any of the other sections. Where these fibrils approach the cells above there is a suggestion of their unity with the fibrils of this layer which will be discussed later on.

Fibrils appear in the lower cells of the epidermis in certain animals and in general vary in length and thickness. They lie usually at the edge of the cell, appearing at times as a thickened cell membrane. In places they are more or less detached from the cell. They are usually straight or slightly curved, but sometimes assume a distinct spiral form. The lower ends of the fibrils may be in contact with the corium. Sometimes a fibril extends into the corium for a short distance. There is no evidence, however, that these fibrils serve in any way to join the epidermis to the corium. The fibrils are usually limited to the length of the lower row of cells, but sometimes extend well up into the second cell row. In all these animals, excellent pictures are obtained of the fibrils of the stratum filamentosum ("bridges").

I have also found in the skin of *Necturus* well developed spiral fibres almost completely surrounding the nucleus of each cell of the basement row (Fig. 3). These fibrils are sometimes seen in the cells of the next higher row, but not so well developed. They are situated well in the protoplasm of the cell in the lower row and approach the periphery of the cell when seen in the next row. While there are no "bridges" in the skin of *Necturus*, these fibres seem to differentiate themselves into a substance that joins together the cells of the upper layers of the epidermis.

Returning to human skin, the fibrils joining together the cells of the stratum filamentosum in conditions apart from normal will first be considered. Increased distinctness of these fibrils

may be seen in human epidermis where the cells are somewhat separated by fluid, as in varying conditions of oedema. In such situations these fibrils may be seen joining together the cells, not only in the stratum filamentosum, but in the stratum granulosum above and the stratum germinativum below. That is, in situations that admit of a proper view of all the cells of the epidermis they are seen to be joined together from top to bottom by delicate fibrils that extend some distance into the cells.

The histologic importance of these fibrils, which are so prominent in both human and animal epidermis, may be emphasized by the fact that I have found them reproduced in skin islets of teratomata exactly as they appear in normal epidermis.

In addition to these fibrils, which are commonly termed the intercellular bridges, there may be seen in the conditions of oedema above described, especially if the section is taken somewhat distant from the edge of a granulating wound of the skin (Fig. 4) or from the edge of a vesicular lesion such as is found in variola and vaccinia, in addition fine or coarse fibrils, intracellular or in part free from the cell, that are not noticeable in the normal epidermis. These larger fibrils run perpendicularly to the corium and sometimes extend a short distance into it. Some of them are quite long, extending into the second or third row of cells. The end to end juncture of certain of the cells of these rows is seen to be affected by these fibrils. The appearance of these fibrils in this situation and their distribution to the cells above the basement row suggests a unity of the two apparently separate sets of fibrils that have been described.

This suggestion of the unity of these apparently different fibrils above noted, is emphasized in a section taken from the new growing epithelium near the ulcerating edge of an epithelioma of the lip where there is very rapid epithelial proliferation (Fig. 5). This section shows in the stratum germinativum a luxuriant growth of the long protoplasmic fibrils. Not all these fibrils, however, are in the protoplasm. From the rapid pushing up of the epithelium many are freed from the cell, either wholly or in part, and lie in the space between the cells, or lie just at the edge of the cells as an apparent membrane. Some of the



fibrils are quite long, extending upwards a distance of several cells. Occasionally a fibril is seen extending a short distance into the corium. A considerable number of the fibrils have the spiral form that is frequently described. In the stratum filamentosum we find numerous cells joined together by these fibrils. Some are joined end on end but frequently the fibrils deviate and form also a side to side juncture, or again they partially deviate and join the end of one cell to the side of another. Where these fibrils have fully differentiated themselves into the connecting fibrils of the stratum filamentosum they are longer, more irregular, and thicker than the "bridges" in normal epidermis. This is to be expected in newly formed tissue where compensatory growth is always a hypercompensation at first. Moreover, these fibrils do not show the central nodes (Ranvier-Bizzozero nodules) that are prominent later on, and this fact would suggest that the nodes were incident to the shrinkage of the fibres. Everywhere in the section there is the irregularity which is evidence of youth and is comparable to the irregularity of young connective-tissue fibrils. The evenness possessed by structures further removed from adolescence has been attained in no place in the section.

The proof of the unity of these fibrils that is evident in this situation is not confined wholly, however, to situations that show separation of the cells, but may be found under opposite conditions, namely with compression of the cells incident to increased cornification, occurring in association with more or less rapid proliferation of epithelium. Papillomata of the skin (warts) offer material for the further consideration of these fibrils

Under pressure from the increased development of the stratum corneum (Fig. 6) the fibrillar groundwork of the epithelium is very conspicuous. There is only slight separation of the cells and consequent shortening and crowding together of the connecting fibrils. The perpendicular fibrils are very distinct and are best seen in the basement row of epithelial cells where they present a brush-like border to the corium. They are not limited to the lower row or rows of cells, but may also be seen extending into the layer of polygonal cells where they either continue as

perpendicular fibrils or branch off and become the so-called "bridges" of this layer. The unity of the fibre system is everywhere apparent.

Still greater degrees of compression emphasize the fibrillar structure of the epidermis but may be too great to admit a close following of the fibrils. Such a section is seen in epidermis taken from the thickened palm of a laborer (Fig. 7) following amputation for extensive phlegmon of the arm. Instead of distinct cells connected by fibrils there is an apparent moulding together of the cell protoplasm into a solid mass, in which the situation of the nuclei, which have more or less completely disappeared, is represented by round or oval empty spaces. In thin, properly stained sections, this apparently solid protoplasmic mass is seen to possess a fibrillar structure. The fibres are largest and most dense around the nuclear spaces, and it seems reasonable to suppose that the appearance is due to a massing together of the various fibres into what appears to be a deeply staining membrane around the nuclear space such as would naturally be formed when the cells are crowded together. This picture is emphasized by rapidity of growth, and the fibrillar structure is lost except in the basement cells where the edges present a distinct brush-like border to the corium. Not only under the conditions which have just been mentioned is there proof of the unity of fibrils, but in the skin of the elephant previously described, a picture is presented (Fig. 2) suggesting unity of fibrils in the absence both of the separation of cells noted in the first description and the marked compression incident to the processes last described. Here the epidermis is in a state of normal equilibrium. There is not the irregularity incident to rapid proliferation and overgrowth. Consequently, transitional forms of these fibrils are not so numerous as in the more unstable situations. Nevertheless, the unity of the two forms of fibrils is more clearly suggested than in the human epidermis when under normal conditions fibrils are found only in the stratum filamentosum.

The detailed consideration of the relation of these fibrils to malignant growths of epithelial origin has been omitted, as

not enough material was at hand to make a complete study of them. The greatest development of these fibrils, however, was seen in a rapidly growing squamous cell carcinoma of the tonsil. In this tumor there was the type of epithelial proliferation usually associated with this form of growth. Most of the mass consisted of irregular strands and nests of epithelial cells with very little connective-tissue stroma between the cell masses. These cell masses consisted of an outer zone of columnar cells, a mesial zone of polygonal cells, and a centre of flattened (in places cornified) epithelial cells. Throughout the section fibrils could be seen extending through certain cells of the outer zone and extending into and connecting the cells of the mesial zone. These fibrils differed in no way from the fibrils previously described. Arising apparently in the columnar cells, they serve to join together long rows of cells corresponding to those of the stratum filamentosum of normal epidermis. The irregular cell development of the tumor gave bizarre arrangements of fibrils, so that exaggerated reproductions of the process seen in Fig. 5 are apparent in discrete areas throughout the section. This reproduction of fibrils in squamous cell carcinoma, whereby the finer mechanism of epithelial-cell growth can be observed, would leave no doubt of the origin of these tumors if the point should be in question. It seems possible, therefore, that a further study of these fibrils may show them to be of importance in the identification or the grouping of tumors derived from squamous epithelium, since, where growth is most rapid, fibrils are most prominent.

From a general consideration of these specimens it is seen that in all sections of skin certain fibrils are present, which serve to bind together the cells of the epidermis, and are best seen in the stratum filamentosum where the cells are larger and paler and somewhat separated by lymph channels. These fibrils in normal skin are comparatively uniform and arranged with considerable regularity. In conditions of epithelial new growth these fibrils lose their regularity and uniformity, extending in places through several cells and branching off in various directions. Their increased prominence seems to be in direct

ratio to rapidity of cell production. They can be traced in such conditions to fibrils in the stratum germinativum, with which they are in many instances directly continuous. These basement fibrils, which are practically wanting in normal human epidermis, are present in larger numbers in rapidly proliferating epidermis and are seen in many of the lower vertebrates.

Possibly the most important deduction to be drawn from the foregoing study of epidermal fibre production is that it establishes a relationship between the epidermal fibre system and the fibre system of other tissues, namely nervous, muscular, and connective-tissue structures.

We are now familiar with the fibrils of neuroglia cells, thanks especially to the work of Weigert and of Mallory; these cells are embryologically at least related to the cells of the epidermis, since both are of ectodermal origin. It has been shown by Southard<sup>18</sup> that in certain inflammatory processes of the cerebellum there is a change in the neuroglia cells, "such that numerous fibrils are thrown out which are roughly proportional to the number of cells present normally in the reacting area."

Recently, Mallory<sup>19</sup> discovered in connective tissue a hitherto undescribed fibril which he named the fibroglia fibril. These fibrils are produced by connective-tissue cells and are to be found normally in certain situations, but are most abundant in rapidly growing connective tissue, such as granulation tissue and the connective-tissue stroma of rapidly proliferating carcinoma. I have noted that those granulating ulcers of the skin that show the most marked production of epidermal fibrils also show, in the connective tissue below, large numbers of fibroglia fibrils.

It has been shown by Heidenhain<sup>20</sup> that muscle cells possess, in addition to their internal fibrils, certain peripheral fibrils which have been termed myoglia fibrils. These fibrils are, however, remarkably sensitive to post-mortem change, and it is doubtful if their full significance is yet understood. Quite recently fibrils in epithelial cells have been described by Wolbach.<sup>21</sup> He found in a carcinoma of the bladder fibrils varying

in diameter, sometimes one and sometimes several to a cell, running longitudinally in the protoplasm of the cell.

#### CONCLUSIONS.

In certain animals, in addition to the protoplasmic fibrils of the stratum filamentosum that are present normally in human epidermis, there are well developed fibrils in the cells of the stratum germinativum. These fibrils are present in the human epidermis only under conditions of increased cell activity.

These fibrils, that are prominent in the stratum germinativum of human epidermis under conditions of increased cell activity, seem to increase in direct ratio to rapidity of cell production.

The differentiation of these fibrils of the stratum germinativum into the finer fibrils which connect the cells of the stratum filamentosum can be observed under proper conditions of growth and therefore there should be no separation of the fibrils into different groups with various names.

This process of fibre production by the cells of the human epidermis is analogous to increased fibre production by various other cells under similar conditions, and may be of importance in identifying or classifying new growths of epithelial origin.

#### BIBLIOGRAPHY.

1. Schroen, cited by Schütz, *Archiv f. Derm. u. Syph.*, 1896, xxxvi, 112.
2. Schultze.—*Virchow's Arch.*, 1864, xxx, 260.
3. Bizzozero.—*Cent. f. d. med. Wissensch.*, 1871, ix, 482.
4. Ranvier.—*Compt. rend. de l'Acad. des Sci.*, 1879, lxxxix, 667.
5. Ranvier.—*Compt. rend. de l'Acad. des Sci.*, 1882, xcvi, 1374.
6. Herxheimer.—*Arch. f. Derm. u. Syph.*, 1889, xxi, 645.
7. Eddowes.—*Monatsch. f. prak. Derm.*, 1890, xi, 89.
8. Kromayer.—*Arch. f. Derm. u. Syph.*, 1890, xxii, 87. *Arch. f. mik. Anat.*, 1892, xxxix, 141.
9. Beneke.—Ref., *Monatsch. f. prak. Derm.*, 1894, xix, 498.
10. Schütz.—*Arch. f. Derm. u. Syph.*, 1896, xxxvi, 111.
11. Herxheimer and Müller.—*Arch. f. Derm. u. Syph.*, 1896, xxxvi, 93.
12. Rabl.—*Arch. f. Derm. u. Syph.*, 1897, xli, 3.
13. Kromayer.—*Monatsch. f. prak. Derm.*, 1897, xxiv, 449.
14. Herxheimer.—*Arch. f. mik. Anat.*, 1899, liii, 510.
15. Unna.—*Monatsch. f. prak. Derm.*, 1903, xxxvii, 289, 337. *Deutsch. med. Ztg.*, xxiv, 809.

16. Fischel.—*Cent. f. all. Path. u. path. Anat.*, 1905, xvi, 593.
17. Mallory.—*Jour. of Med. Research*, 1905, xiii, 116.
18. Southard.—*Jour. of Med. Research*, 1905, xiii, 487.
19. Mallory.—*Jour. of Med. Research*, 1903, x, 334.
20. Heidenhain.—*Ergebnisse der Anat. u. Entwickl.*, 1898, viii, 3.
21. Wolbach.—*Jour. of Med. Research*, 1905, xiii, 425.

## EXPLANATION OF PLATE XXIII.

Fig. 1.—From epidermis of zebra. Well developed fibrils are present both within and at the edges of the basement cells; some are of spiral form. Cells of the second layer are compact and joined by closely set protoplasmic fibrils, the ends of which are lost in the protoplasm of the cells.

Fig. 2.—From epidermis of the elephant. Perpendicular fibrils of the basement cell layer are prominent. The fibrils of the second layer are long, and irregular, reach the nucleus in places, and show distinct Ranvier-Bizzozero nodules.

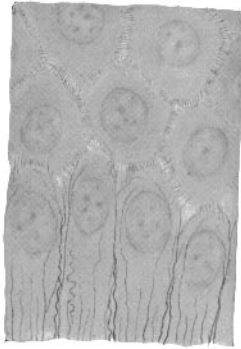Fig. 3.—Protoplasmic fibrils in basement cells of *Necturus*.

Fig. 4.—Œdema of skin with some proliferation of epithelium. A few of the long fibrils appear in the basement cells. Finer fibrils join all the cells (stratum germinativum and stratum spinosum). Ranvier-Bizzozero nodules are prominent.

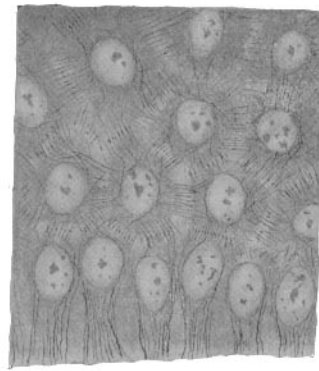
Fig. 5.—Rapidly growing epidermis adjacent to ulcerating edge of carcinoma of lip. There is rich fibril production and the development of finer fibrils, connecting the cells of the mesial zone, from the long coarse fibrils of the basement cells is apparent. There are no Ranvier-Bizzozero nodules.

Fig. 6.—Papilloma of skin.

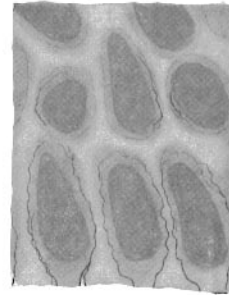
Fig. 7.—Palm of laborer showing excessive production of fibres.



*Fig. 1*




*Fig. 2*



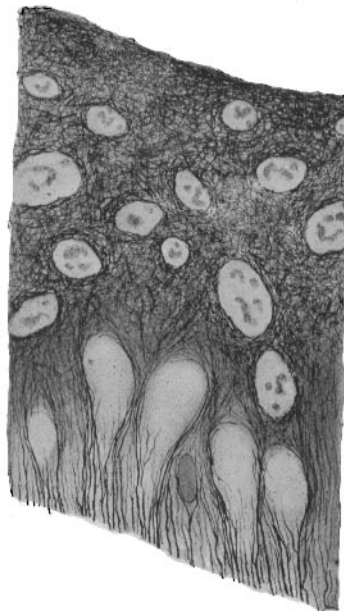
*Fig. 3*



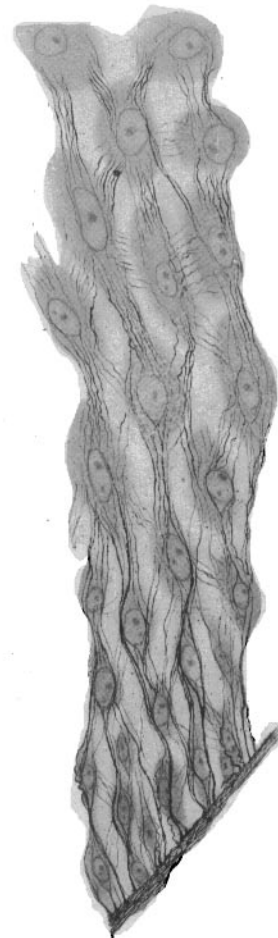
*Fig. 4*



*Fig. 6*



*Fig. 7*



*Fig. 5*