

VITAMIN C IN RELATION TO EXPERIMENTAL POLIOMYELITIS

WITH INCIDENTAL OBSERVATIONS ON CERTAIN MANIFESTATIONS IN
MACACUS RHEBUS MONKEYS ON A SCORBUTIC DIET

By ALBERT B. SABIN, M.D.

(From the Laboratories of The Rockefeller Institute for Medical Research)

PLATES 30 AND 31

(Received for publication, December 21, 1938)

Data have recently been presented to show that the administration of natural vitamin C during the incubation period of experimental poliomyelitis is capable of modifying the course of the disease and of preventing paralysis in a considerable number of *Macacus rhesus* monkeys.

With the Aycock strain of the virus and the intracerebral route of inoculation, Jungeblut (1, 2) found that 77 of 243 (31.3 per cent) vitamin C-treated monkeys escaped paralysis, as compared with only seven of 136 (5.2 per cent) untreated animals. When synthetic vitamin C was used, no significant effect was obtained since only eleven of 101, or 10.2 per cent, failed to develop paralysis. With the M.V. virus (special strain used exclusively for nasal instillation for several years and obtained from the writer) instilled intranasally Jungeblut (2) reported that only one of twenty monkeys treated with 5 to 25 mg. of natural vitamin C daily (optimum dose in intracerebral experiments) showed no paralysis, while among ten animals treated with 50 to 100 mg. daily nine escaped paralysis; fifteen untreated monkeys all became paralyzed.

Since any substance exerting such an effect on experimental poliomyelitis might be a most useful therapeutic agent, it was deemed desirable to determine whether or not these results could be reproduced.

Methods

The strain of M.V. virus, the technique of nasal instillation, and other details which contribute to the constancy of infection (nearly 100 per cent in over 100 monkeys) by the nasal route were described in a recent communication (3).

The infecting dose was 1 cc. of a 5 per cent suspension of virus for each nostril on two occasions at an interval of 4 to 6 hours. When the second dose is omitted the number of monkeys which succumb may be reduced by half, indicating that the dosage employed is just within the range of that required to infect successfully all monkeys (provided the virus is fresh or has not been in glycerol much longer than a month). Two preparations of vitamin C, natural and synthetic,¹ were used. The vitamin was dissolved in distilled water just before using and the injections were given subcutaneously. When 400 mg. of the synthetic crystalline preparation was administered in a single daily dose, it was neutralized with NaOH just before using. The vitamin was administered immediately after nasal instillation of the virus and once daily thereafter until the outcome was clearly apparent.

Effect of Vitamin C on Disease Induced by Nasal Instillation of Virus

Thirty-six monkeys were used in the first test. They were on a vitamin C-adequate diet (oranges, bananas, bread, and milk) for at least 9 days before virus instillation, during which time their rectal temperatures were recorded daily as an aid in the interpretation of any subsequent febrile reaction. All monkeys were instilled at the same time with a pool of poliomyelitic cords which had been kept in 50 per cent glycerol for 3 months. Virus of this age was used with the hope that less than 100 per cent of the control animals would succumb. Ten monkeys were untreated; six received at the time virus was first instilled and daily thereafter 5 mg. of natural vitamin C; ten, 100 mg. of natural C; and ten, 100 mg. of synthetic, crystalline cevitamic acid.

The results recorded both in Chart 1 and Table I show that vitamin C neither modified the course of the disease nor prevented paralysis: 80 per cent of the untreated monkeys and 90 per cent of the treated ones developed paralysis. With these data at hand, Dr. Jungeblut's advice was sought and a similar experiment was carried out jointly in his laboratory. In a group of forty monkeys, among which ten were controls and thirty were treated with varying amounts of vitamin C, only one monkey, a treated one, escaped paralysis.

Influence of Preliminary Diet

In an attempt to find an explanation for the discrepancy between the present and the reported (1, 2) results, it appeared that vitamin C may perhaps be effective only at the time it is being taken up by depleted tissues. If that were the case, one might expect no effect in monkeys which had been in the laboratory on an adequate vitamin

¹ Kindly supplied by Merck and Company.

C diet for some time prior to the experiment (as was the case in the present tests), while in monkeys whose store of vitamin C was depleted a beneficial result may perhaps be obtained. This possibility was submitted to experiment.

Forty-six monkeys, selected for their excellent physical condition and nutrition, were obtained in a single lot on Jan. 4, 1938, from one dealer who stated that

TABLE I
Effect of Vitamin C on Experimental Poliomyelitis

Series	Preliminary diet	Vitamin C given daily following nasal instillation of virus	Number of monkeys	Number developed paralysis
I	Vitamin C <i>adequate</i> for at least 9 days before test	None	10	8
		5 mg. natural	6	5
		100 " "	10	9
		100 " synthetic	10	9
II	Vitamin C <i>adequate</i> for at least 21 days before test	None	6	6
		100 mg. natural	7	7
		400 " synthetic	7	7
	Vitamin C <i>deficient</i> for 21 days before test	None	5	4
		100 mg. natural	7	7
Total untreated.....			21	18 (86 per cent)
Total treated.....			47	44 (94 per cent)

they had arrived in a single shipment on Dec. 28, 1937, and that during the voyage, as well as in his own establishment, their diet included oranges and other fresh fruits. Twenty-one of these monkeys were placed on the regular laboratory diet (bread, pasteurized milk, oranges, and bananas) and at the end of 3 weeks only one died, the remaining twenty being healthy and well nourished. The other twenty-five monkeys were put on the following vitamin C-inadequate diet:

Milk (boiled with a constant stream of compressed air for 1 hr.)	250 cc.
Granulated sugar	15 gm.
Cod liver oil	15 cc.
Whole wheat bread	80 gm.
Peanuts	<i>ad lib.</i>

The indicated amounts were those allowed daily for each monkey. The diet was only partly consumed due to the monkeys' dislike for cod liver oil and when it was found that they were not thriving, it was changed on the 12th day to pasteurized whole milk with added cane sugar and 2 drops of drisdol (crystalline vitamin D in propylene glycol) per monkey, white bread, and peanuts; the new diet was completely consumed. At the end of 3 weeks thirteen of the twenty-five monkeys had died in a manner to be described in a subsequent section.

On Jan. 25, 1938, *i.e.*, at the end of 3 weeks on their respective diets, all the monkeys were given virus intranasally. Of the twenty which had been on the vitamin C-adequate diet, six served as controls, seven received 100 mg. of natural vitamin C daily, and seven others were given 400 mg. crystalline synthetic vitamin C daily at Dr. Jungeblut's suggestion, who believed from his unreported experiments that the synthetic vitamin might be effective when administered in larger amounts. Of the twelve remaining monkeys which were on the vitamin C-deficient diet, five served as controls and seven were given 100 mg. of natural vitamin C daily.

The results recorded in Table I and Chart 2 show no effect of vitamin C in either group. Of the thirty-two monkeys all but one developed paralysis and that one was in the untreated control group which had been fed with the vitamin C-deficient diet.

Some Manifestations in Monkeys on a Scorbutic Diet

Since hitherto few monkeys have been used in vitamin C studies, it may be of interest to record some of the more striking manifestations among the *rhesus* monkeys which were on a scorbutic diet in the present investigation. That which attracted most attention was the death of thirteen of twenty-five monkeys between the 9th and 18th days after they had been put on the scorbutic diet, while among the twenty-one monkeys on the regular diet all remained well during the same period.

Postmortem examination revealed evidence of acute infections in most of the fatal instances—five had non-tuberculous, lobar pneumonia with complete consolidation of one or more lobes; three, hemorrhagic enterocolitis; one, an erysipelas-like infection of the face; and in four there were no gross pathological changes other than emaciation; the monkeys that died with pneumonia were all well nourished (see Chart 3). While none of the monkeys showed any definite clinical or gross pathological evidence of scurvy, there was, nevertheless, microscopic evidence of early scurvy in the ribs and lower ends of the femurs of some of them.

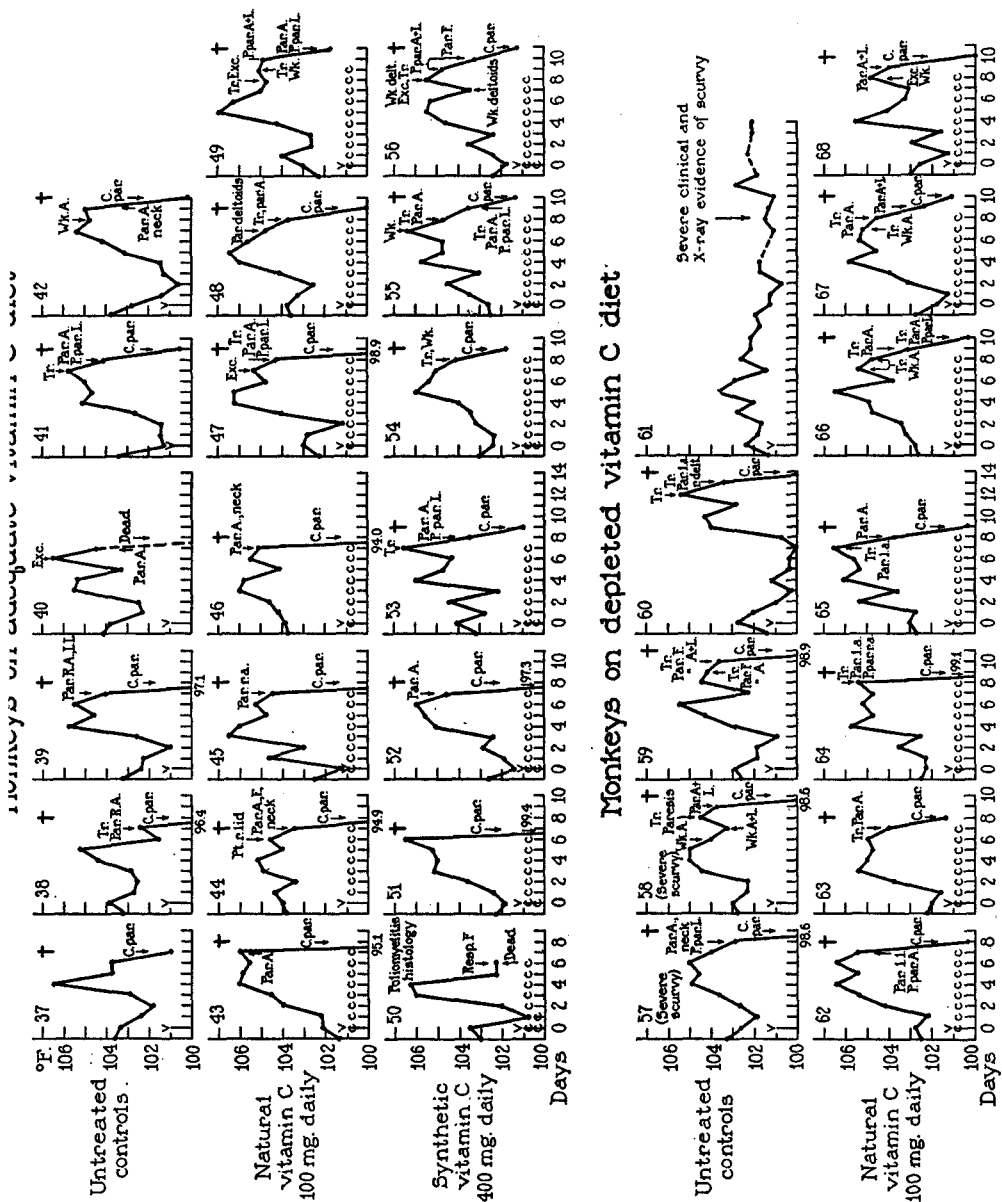


CHART 2. Influence of preliminary diet on subsequent effect of subcutaneous injections of vitamin C on the course of experimental poliomyelitis.

The increased susceptibility to spontaneous infection among guinea pigs on scorbutic diets and among human beings with scurvy has been noted by several investigators. It is also interesting that the infections observed by Höjer (4) and others in guinea pigs on vitamin C-deficient diets were chiefly of the upper respiratory tract and pneumonia, septicemia, and enterocolitis. The present observations on monkeys, which correspond so closely to those on guinea pigs, derive special significance from the practically total absence of acute infec-

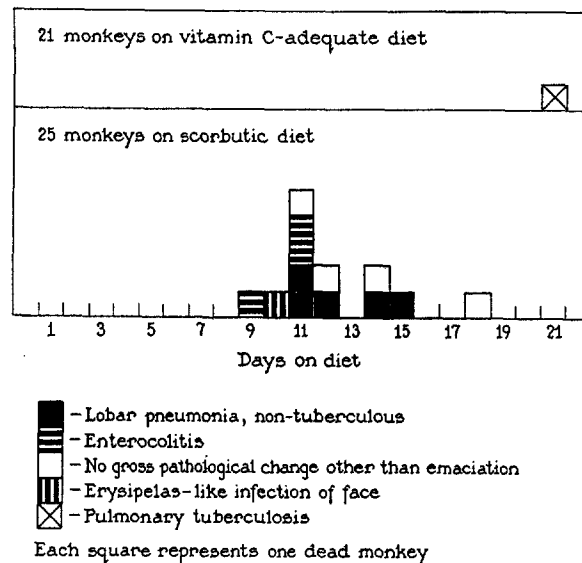


CHART 3. Mortality in relation to diet in a single colony of *rhesus* monkeys.

tion among the other twenty-one monkeys of the same group which were receiving the regular diet.

The twelve remaining monkeys all received poliomyelitis virus 3 weeks after the beginning of the vitamin C-deficient diet. Clinical, x-ray, or postmortem evidence of scurvy was found among three of the five monkeys whose diet was not supplemented by vitamin C, but not among the seven which received 100 mg. of natural vitamin C daily.

Two of these three showed their first signs of scurvy at the end of the 4th week after the beginning of the diet and during the course of poliomyelitic infection.

Monkey 58 first exhibited edema of the eyelids which became discolored the following day from spontaneous hemorrhages; there were also some sponginess and subgingival hemorrhage about three teeth. While there was no other external hemorrhage, the tourniquet test applied to the upper extremity yielded a large crop of petechiae on the arm and forearm distal to the tourniquet. There was a peculiar clumsiness of the upper and lower extremities (recorded as weakness) for at least 2 days before the onset of the characteristic nervous signs of poliomyelitis, apparently as a result of subepiphyseal fractures which were found at autopsy. The lower ends of both femurs and the upper ends of both tibiae and humeri showed varying degrees of fracture, periosteal separation, and subperiosteal hemorrhage (Figs. 1 and 2). "Mushrooming" of some of the ribs at the costochondral junctions could be discerned by palpation, as well as by x-ray, which also revealed "cupping," loss of calcium, and focal trabecular disintegration (Figs. 4 and 5). Outside the skeleton there was a striking reaction in the abdomen where there was considerable hemorrhage in the wall beneath the parietal peritoneum as well as large, subcapsular blood clots around both kidneys (Fig. 3). The writer has not found reference to hemorrhages in these sites and it is quite probable that they were the result of the method used in catching the monkeys, which involves grasping the animal by the small of the back. Monkey 57 showed gross changes only in the lower ends of both femurs (epiphyseal inflections) and by x-ray in some of the ribs. Monkeys 59 and 60 showed no gross scorbutic changes. Monkey 61 exhibited no evidence of poliomyelitic infection. On the 42nd day after the beginning of the diet, it had questionable gingival changes and also some difficulty in climbing; on the 43rd day both the upper and lower eyelids were edematous, and the gums were red and spongy about the incisor teeth. 2 days later the eyelids were hemorrhagic; it had lost the use of its right arm and could climb only with the greatest difficulty. The tourniquet test was positive on two occasions; it was negative in six normal monkeys. The monkey appeared ill, was disinclined to move, but it was quite evident that the loss of function in the extremities was due to spontaneous fractures—bony crepitus was clearly elicited—rather than to nervous involvement. X-ray revealed fractures with displacement at the lower ends of both femurs (Figs. 8 and 16); scorbutic changes were also apparent in the upper ends of the humeri and in the ulna at the wrists (Figs. 12 and 14). On completion of the 4 weeks of observation following the instillation of virus (*i.e.*, 49 days of deficient diet), 1 gm. of the crystalline, synthetic cevitamic acid used for treatment of the other monkeys was given subcutaneously to monkey 61. The following day the hemorrhage and edema of the eyelids had disappeared, the tourniquet test was negative, and the monkey appeared much improved. Smaller doses of vitamin C continued to be given daily and within 4 to 5 days it regained the use of its extremities and x-rays taken 10 days later showed repair of the fractures with calcification of what must have been extensive subperiosteal hemorrhages about the femurs, humeri, one ulna, and costochondral junctions (Figs. 7, 9, 11, 13, 15, and 17). These x-ray findings were confirmed at autopsy.

In correlating the manifestations in monkeys with the changes seen in human scurvy, it should be noted that the age of the monkeys used in these studies is equivalent to that of 10 to 13 years in human beings calculated on the basis of the development of ossification centers and the open epiphyses. The bony changes observed here correspond closely to those seen in scorbutic children. In so far as the high incidence of acute infections can be attributed to the inadequate diet, it is noteworthy that the increased susceptibility to spontaneous infection developed before any gross signs of scurvy had appeared. The impression was gained that in the investigation of certain problems relative to vitamin C deficiency *rhesus* monkeys might be used more advantageously than guinea pigs.

DISCUSSION AND SUMMARY

In the experiments reported in the present communication it was found that vitamin C, both natural and synthetic preparations, had no effect on the course of experimental poliomyelitis induced by nasal instillation of the virus. The objection cannot be raised that too large an amount of virus was used, since recent studies (3) on the fate of the nasally instilled virus indicated that all but an undetectable amount of it is swallowed and disappears from the nasal mucosa within 3 hours or less, and that none is demonstrable in the central nervous system before the 3rd day. Vitamin C administration was begun immediately after the instillation of virus and if it were capable of exerting any effect on the virus or the tissues it could have done so even before multiplication of virus had begun. Monkeys whose store of vitamin C was depleted reacted in the same way as those receiving an adequate diet. There is no apparent explanation for the difference between these results and those reported earlier by Jungeblut (1, 2).

During the present investigation it was found that monkeys on a scorbutic diet died of spontaneous acute infections, chiefly pneumonia and enterocolitis, while their mates receiving an adequate diet remained well. The surviving monkeys on the scorbutic diet developed the osseous and other changes of human scurvy, and the vitamin C used in this study was shown to produce healing and calcification in the bones as well as to check the edema and hemorrhagic diathesis.

BIBLIOGRAPHY

1. Jungeblut, C. W., *J. Exp. Med.*, 1937, **65**, 127.
2. Jungeblut, C. W., *J. Exp. Med.*, 1937, **66**, 459.
3. Sabin, A. B., and Olitsky, P. K., *J. Exp. Med.*, 1938, **68**, 39.
4. Höjer, J. A., *Acta paediat.*, suppl., 1924, **3**, 8, quoted by Perla, D., and Marmorston, J., *Arch. Path.*, 1937, **23**, 543.

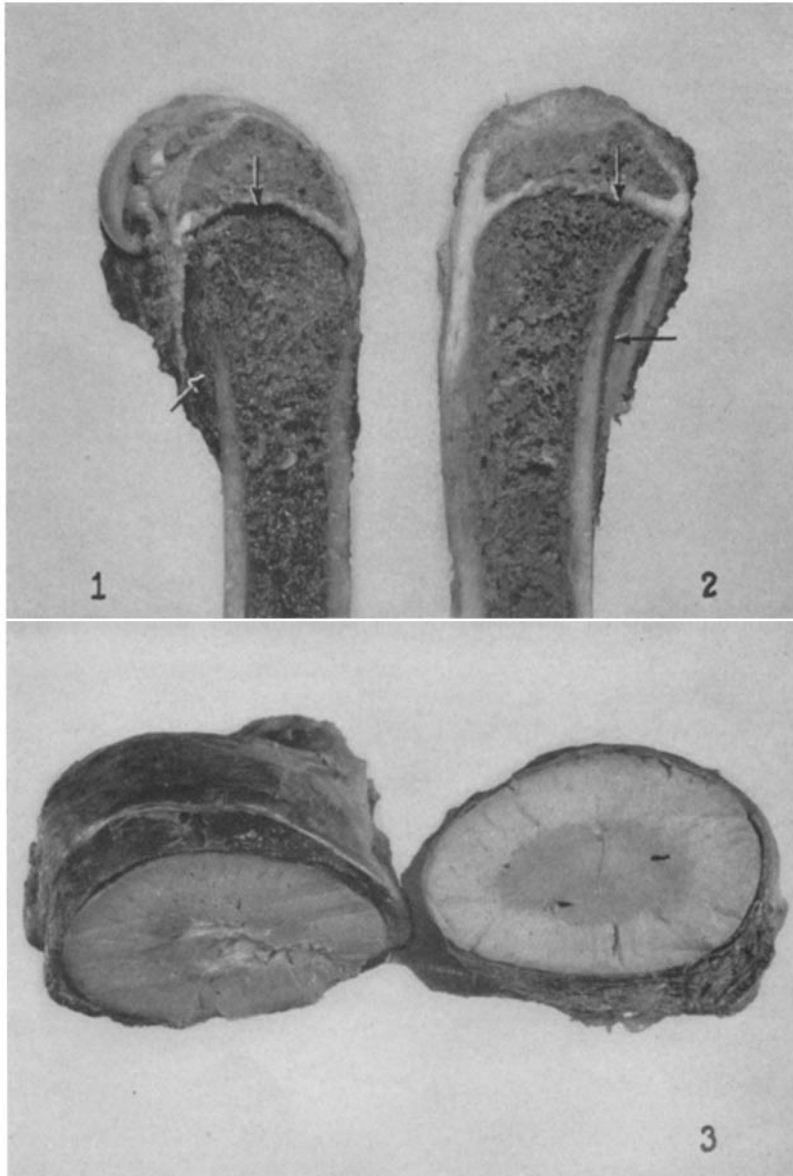
EXPLANATION OF PLATES

PLATE 30

FIG. 1. Lower end of femur of scorbutic monkey (M 58). Arrows point to subepiphyseal fracture and subperiosteal hemorrhage. $\times 2$.

FIG. 2. Upper end of tibia of M 58. Note separation of periosteum from shaft without hemorrhage, in addition to subepiphyseal fracture. $\times 2$.

FIG. 3. Subcapsular perirenal hemorrhage in M 58. $\times 2$.



Photographed by Joseph B. Haulenbeck

(Sabin: Vitamin C in relation to poliomyelitis)

PLATE 31

FIG. 4. Ribs of normal monkey. Note the almost straight line between the bone and cartilage. $\times 2$.

FIGS. 5 and 6. Ribs of two scorbutic monkeys. Arrows point to "mushrooming" and "cupping" of costochondral junction and to foci of trabecular disintegration. $\times 2$.

FIG. 7. Ribs of scorbutic monkey (M 61) 10 days after vitamin C. Note rosary formed by calcification of subperiosteal hemorrhage in all the fixed ribs with the exception of the upper three, suggesting the rôle of the respiratory movements in the causation of these changes. Actual size.

FIG. 8. Right knee of M 61 just before vitamin C therapy. Arrow points to fracture and displacement at lower end of femur; note also the light zone of diminished calcification.

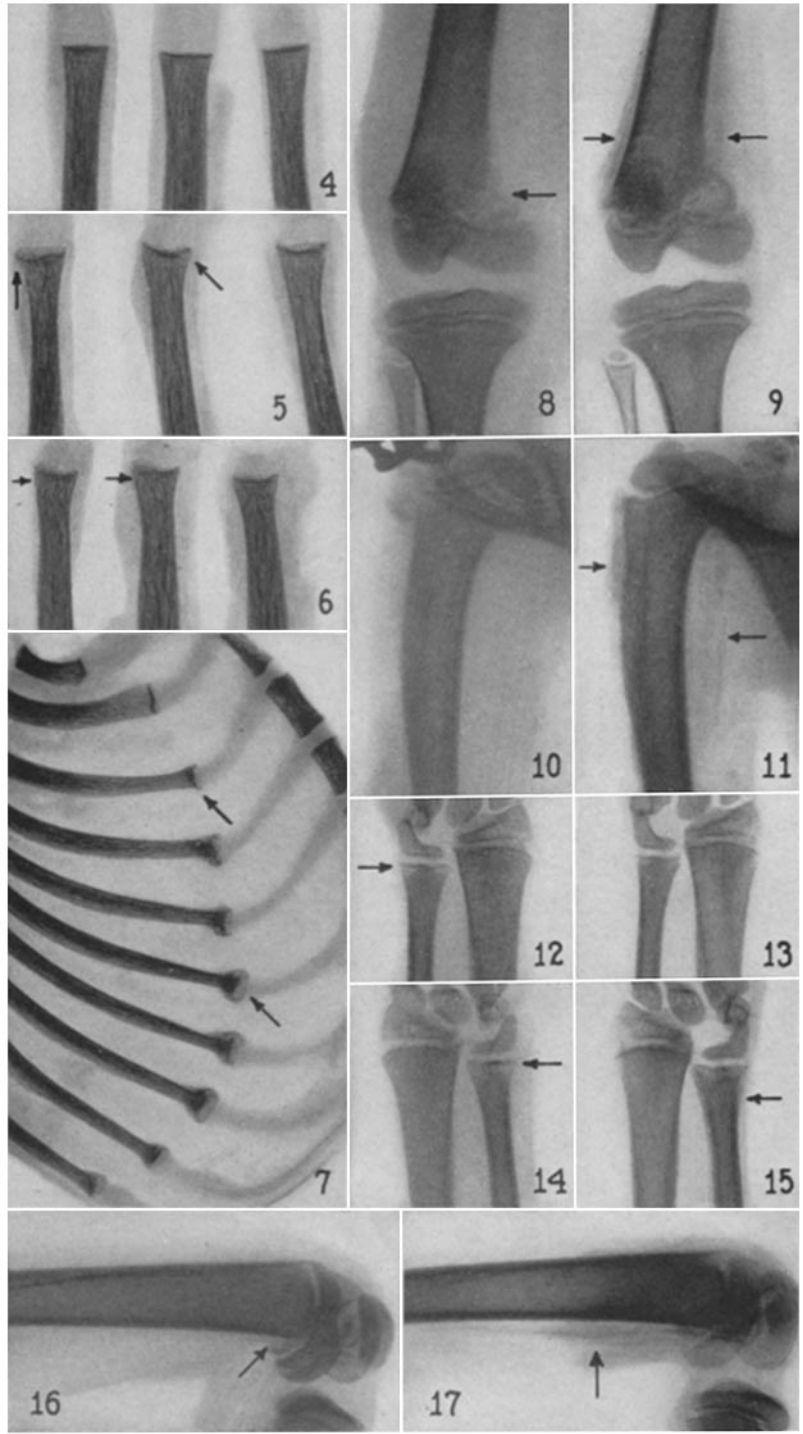
FIG. 9. Same knee 10 days after beginning of vitamin C therapy. Arrow points to calcified subperiosteal hemorrhage.

FIGS. 10 and 11. Right humerus (M 61) before and 10 days after vitamin C. Arrows in Fig. 11 point to calcified subperiosteal hemorrhage.

FIGS. 12 and 13. Right wrist (M 61) before and 10 days after vitamin C. Arrow points to the more marked zone of decalcification in the ulna prior to vitamin C.

FIGS. 14 and 15. Left wrist (M 61) before and 10 days after vitamin C. Arrow in Fig. 15 points to calcified subperiosteal hemorrhage.

FIGS. 16 and 17. Left knee (M 61) before and 10 days after vitamin C. Arrow in Fig. 16 points to fracture with displacement in femur and that in Fig. 17 to calcified subperiosteal hemorrhage.



Photographed by Joseph B. Haulenbeck

(Sabin: Vitamin C in relation to poliomyelitis)