

STUDIES ON AN UNCOMPLICATED CORYZA OF THE
DOMESTIC FOWL

VI. COCCOBACILLIFORM BODIES IN BIRDS INFECTED WITH THE CORYZA
OF SLOW ONSET

By JOHN B. NELSON, Ph.D.

(From the Department of Animal and Plant Pathology of The Rockefeller Institute
for Medical Research, Princeton, N. J.)

PLATE 38

(Received for publication, January 2, 1936)

In the preceding paper evidence was presented that the coryza of slow onset is a stable entity which is apparently unaffected by long continued serial passage in susceptible fowl (1). It cannot be established as an independent disease, however, until its etiology is elucidated. The only pertinent information concerned the bacterium *Hemophilus gallinarum* which, it has been shown, is not present in the nasal exudate of infected fowl (1). Maintenance of the coryza of slow onset was, accordingly, continued by serial passage and an effort made to determine its causative agent.

The Bacteriological Examination of Exudate

The cultivation of exudate from birds infected with the coryza of slow onset on blood agar plates revealed no bacteria which had not been previously isolated. The organisms which were encountered colonized freely on open as well as on sealed plates and also grew vigorously in fluid media enriched with blood. The bacteria which were most frequently met with fell into three groups, namely: diphtheroids, Gram-positive cocci, and Gram bacilli. There was no uniformity in their appearance from bird to bird and the pure growth of a single species was rarely observed. They were usually few in number during the first week or two after the onset of symptoms, increased as the coryza progressed, and became very numerous late in the disease. In some cases, however, exudate from the orbital sinuses, which

subsequently proved to be infective, failed to show colony formation on either sealed or open blood agar plates. As the result of past experience with these bacteria it can be stated that all of them are secondary invaders and of no direct etiological significance.

In the routine performance of autopsies on infected birds a presumptive appraisal of the bacterial flora of exudate was made by direct films which were Gram stained. If the films showed no or few bacteria the exudate in addition to being plated was also cultured in fluid horse blood at the base of slanted nutrient agar. In some cases the plates showed no growth, nor did the solid portion of the slant culture but the fluid portion of the latter contained a minute Gram organism which will subsequently be referred to as the X bacillus.

The X bacillus is an extremely small organism, 0.5μ or less in diameter. It is tentatively designated a bacillus but it might equally well be called a coccus for the cells are predominantly spherical and only occasionally elongated. It is Gram-negative and non-motile. The cells are almost invariably grouped in clumps which may become large and compact comprising innumerable units. Growth in a fluid nutrient medium containing blood is slow and scant. Characteristic clumps are usually present on the 2nd day and regularly on the 3rd day, after incubation at 37°C . The clumps are never numerous and their detection may require considerable searching. After the 3rd day degenerative changes, which may be accompanied by swelling, set in and the cells begin to lose their sharpness of outline. Recently isolated cultures have failed to colonize on open or sealed blood agar plates. After repeated transfers, however, pin point colonies may be produced on the surface of both plates. One strain of the bacillus which has been carried through 80 biweekly or weekly subcultures still fails to colonize.

For a brief period it was believed that the X bacillus was of some etiological significance since it was found that the initial culture of one strain was infective for normal birds. This view was soon shown to be erroneous. Subcultures of this strain were innocuous as were the primary cultures of other strains. The infectivity of the single culture was probably due to the presence of exudate in the material which was injected as it was later observed that primary cultures containing exudate which was culturally sterile would occasionally infect normal birds. Isolation of the X bacillus was, moreover, irregular; in all only 8 cultures were obtained, an incidence of roughly 10 per cent.

The Filtration of Exudate

Since there was no indication that a cultivable bacterium was directly concerned in the etiology of the coryza of slow onset, attention was directed to the filterable viruses. Exudate from affected birds was, accordingly, filtered through Berkefeld V candles and the filtrate tested for infectivity.

The exudate was removed from the interior nasal passages of 2 or more infected fowl, thoroughly mixed with approximately 10 cc. of nutrient bouillon, and filtered through Berkefeld V candles (3.5 cm.). 3 separate filtrations were made. In 2 instances the suspensions were passed through candles known to be impermeable to *Hemophilus gallinarum*. In one instance the exudate mixture was divided into two portions; one of which was filtered through a similarly impermeable candle and one through a candle which failed to hold back the test organism. All of the filtrates were tested for sterility by adding a 0.5 cc. portion to an equal volume of defibrinated horse blood at the base of a nutrient agar slant. None of the filtrate cultures showed either macroscopic or microscopic evidence of growth. The exudate was cultured on blood agar plates prior to filtration and in each case showed numerous colonies of miscellaneous bacteria. The filtrates were tested for infectivity by the intranasal injection of 0.5 cc. portions in normal fowl, which were 2-3 months of age. A similar portion of unfiltered exudate was also tested in each case. Unless the injected bird showed a discharge at an earlier time it was kept under observation for at least 4 weeks. It was then autopsied and the nasal tract examined.

The results of the filtration experiments are summarized in Table I. The three groups of birds which were injected with exudate filtered through candles impermeable to *Hemophilus gallinarum* all remained normal during the period of observation and at autopsy, 33 to 42 days after injection, showed no indication of a nasal involvement. The 3 birds which received unfiltered exudate showed a nasal discharge after 12 to 14 days. One of the 2 birds which were injected with exudate filtered through a candle which was permeable to *Hemophilus gallinarum* showed a nasal discharge on the 27th day after injection. At autopsy, on the following day, a large amount of mucopurulent exudate was found in the nasal passages and a smaller amount in both orbital sinuses. 2 blood agar slant cultures made from the left sinus showed no growth macroscopically or microscopically. The 2nd bird failed to show a nasal discharge but at autopsy on the 33rd day a

quantity of mucopurulent exudate was found in the right orbital sinus. This exudate was also culturally sterile. Normal fowl which were injected with exudate from these 2 birds, Nos. 11 and 12, showed a nasal discharge on the 21st and 25th day, respectively.

The Microscopic Examination of Exudate

In the microscopic examination of films made directly from exudate it had been noted that minute coccobacilliform bodies were often

TABLE I
The Infectivity of Filtered Exudate

No. of exudate	Type of filter	No. of bird	Material injected	Result of injection
1	Impermeable V	1	Filtered exudate	Normal 33 days
		2	“ “	“ 33 “
		3	Unfiltered exudate	Nasal discharge 14th day
2	“ “	4	Filtered exudate	Normal 36 days
		5	“ “	“ 36 “
		6	Unfiltered exudate	Nasal discharge 12th day
3 A	“ “	7	Filtered exudate	Normal 42 days
		8	“ “	“ 42 “
		9	“ “	“ 42 “
		10	Unfiltered exudate	Nasal discharge 12th day
3 B	Permeable V	11	Filtered exudate	“ “ 27th “
		12	“ “	Sinusitis at autopsy on 33rd day

present, being particularly conspicuous in exudate which did not contain the usual secondary bacteria (2). These bodies were frequently arranged in aggregates which were morphologically indistinguishable from those characterizing the X bacillus in culture. It was soon apparent, however, that the coccobacilliform bodies which were present in films could not be identical with the bacillus obtained in cultures. As more attention was paid to the detection of these bodies it was found that they were almost invariably present in films, whereas the X bacillus was only rarely isolated in cultures.

The coccobacilliform bodies are minute immobile cells which may be found as single or double units and in aggregates varying from a few cells up to large compact masses of innumerable units. In shape they are commonly spherical but may be slightly elongated, appearing as extremely short bacilli. In size they are generally under 0.5μ and may be so minute that they are barely visible. In exudate removed early in the disease the bodies are usually quite uniform in size. Their detection in films requires a rather intense stain. For routine purposes the Gram stain, counterstaining for several minutes with carbolfuchsin diluted 1:4 with water, has proved highly satisfactory. The individual cells stain deeply and stand out sharply. The bodies are also well stained by Victoria blue. Giemsa stain has given less satisfactory results. The outline of the individual bodies tends to be fuzzy and they may be confused with precipitated material. The color with Giemsa is a purplish shade.

The most favorable time for the detection of the coccobacilliform bodies is during the first week after the appearance of a nasal discharge. Later in the disease they tend to be obscured by secondary bacteria which may be present in large numbers. The bodies are predominantly extracellular regardless of the stage of the disease. They may also be found intracellularly, chiefly in polynuclear leucocytes but occasionally in epithelial cells. They vary greatly in numbers even when films are made shortly after the onset of the nasal discharge. If the exudate is mucopurulent in nature, with numerous leucocytes, the bodies are commonly well distributed throughout the film, generally extracellular, and in small groupings. Occasionally large cloud-like masses of the bodies may be observed. In some cases, however, they are scarce in such films and their detection may require considerable searching. In the thick catarrhal type of exudate which contains many epithelial cells but few leucocytes they are always present in small numbers. In such exudate the bodies are sometimes found within epithelial cells but this is a rare occurrence. In the lacrimal ducts they may be present in considerable numbers in the absence of leucocytes. The detection of the bodies in older cases of coryza which show large numbers of miscellaneous bacteria in the nasal canals and in the orbital sinuses may often be made from the lacrimal duct films which usually contain relatively few secondary bacteria. Well defined bodies have been found in the lacrimal ducts as long as 2 months after the onset of symptoms.

Cells similar to the coccobacilliform bodies have not been found in

films from the nasal mucosa of normal fowl, or in the exudate from birds infected with cultures of *Hemophilus gallinarum*. They are found so regularly in the exudate from birds affected with the present strain of coryza that they have come to be regarded as characteristic of it as is the prolonged incubation period. In addition to their presence in birds infected by intranasal injection they have also been found regularly in birds which have acquired a coryza by direct contact. That they are not peculiar to this particular strain of the coryza of slow onset is indicated by their detection in birds affected with 2 other strains. These particular strains were obtained originally, in the spring of 1935, from naturally infected fowl and were for some time maintained by serial passage. Coccobacilliform bodies have also been found in birds infected with what was supposedly a pure strain of the coryza of rapid onset, but which in all probability was a mixture of the two types of coryza.

All attempts to grow the coccobacilliform bodies in artificial media have been unsuccessful. Infective exudate, known to be free from bacteria, has been cultivated under aerobic and anaerobic conditions at 37° and 42°C. using both solid and fluid media enriched with a variety of substances as defibrinated blood, serum, amniotic fluid, and yeast extracts. Save for the occasional isolation of the X bacillus no indication of growth has ever been noted. The bodies have, however, been cultivated in fertile eggs and in tissue cultures employing chick embryo tissue. The latter observations which are still incomplete will be considered in a separate report.

DISCUSSION

Etiological analysis of the coryza of slow onset has been retarded by the prolonged incubation period which has necessitated the observation of experimental birds for long periods of time. It was soon evident that the cultivable bacteria were of no direct causal significance. *Hemophilus gallinarum* was readily excluded since it was never isolated from nasal exudate. The different species of free growing bacteria which were isolated from the nasal tract could all be regarded as secondary invaders. The so called X bacillus was ruled out as an etiological factor by reason of the rarity of its isolation and the failure of subcultures to infect.

Filtration experiments indicated that the infective agent of the coryza was incapable of traversing the usual Berkefeld V filters but that it could pass through a V filter which was permeable to *Hemophilus gallinarum*. This observation suggested that the causative factor was either a virus of large size or a bacterium of small dimensions. The usual but not invariable association of polynuclear leucocytes with the coryza, even during the early days of the disease, tended to contraindicate a virus as the causal agent. Accordingly, attention was focused on certain minute coccobacilliform bodies which had been noted in films made directly from exudate.

The present report has dealt with the characteristics of these bodies, emphasizing their almost invariable detection in stained films, their extracellular predominance, and their apparent inability to grow in or on artificial media. The etiological significance of such an agent, which cannot be cultivated by the usual bacteriological methods, is difficult to establish. The present evidence concerning its relation to the coryza of slow onset is largely circumstantial but will be supported, in a later communication, by more concrete evidence gained by a study of the coccobacilliform bodies in fertile eggs and in tissue cultures.

The actual nature of the coccobacilliform bodies is undetermined. Morphologically they bear a resemblance to the elementary bodies of vaccinia and other virus diseases. It is of interest in this connection that Gibbs has recently reported the association of a filterable virus with an infectious fowl coryza (3). He found that the infective agent would pass through a collodion membrane with a pore size of 0.135μ but was held back by a membrane with a pore size of 0.082μ (4).

The coccobacilliform bodies are also morphologically suggestive of the rickettsiae. This group of infective agents possesses a number of characters in common with the elementary bodies. Resistance to physical and chemical agents, immunity relationships, antibody production, and particularly growth in an arthropod host are factors which serve to differentiate the known examples of these two groups but in general, however, they are not sharply separated. With an unknown infective agent it may be difficult to decide whether it should be classified with the filterable viruses, the rickettsiae, or neither. This situation which arose in connection with psittacosis, the causal factor

of which has been classified as a filterable virus (elementary body), a rickettsia, and a bacterium, is again encountered in the present instance. In the case of the coccobacilliform bodies it may prove to be of significance that their morphological features, which are distinctive, are similar to those of a cultivable bacterium isolated from the same source.

SUMMARY

Minute coccobacilliform bodies have regularly been found in the nasal exudate of fowl infected both by injection and by contact with the coryza of slow onset. These bodies are commonly less than 0.5μ in diameter and are predominantly extracellular. They have consistently failed to grow in artificial media. They are held back by Berkefeld V filters which are impermeable to *Hemophilus gallinarum* but may pass through filters which are permeable to the test organism.

The coccoid bodies are morphologically similar to a cultivable non-infective bacterium which may occasionally be isolated from exudate of the infected fowls.

BIBLIOGRAPHY

1. Nelson, J. B., *J. Exp. Med.*, 1936, **63**, 509.
2. Nelson, J. B., *Science*, 1935, **82**, 43.
3. Gibbs, C. S., *Science*, 1935, **81**, 345.
4. Gibbs, C. S., *J. Bact.*, 1935, **30**, 411.

EXPLANATION OF PLATE 38

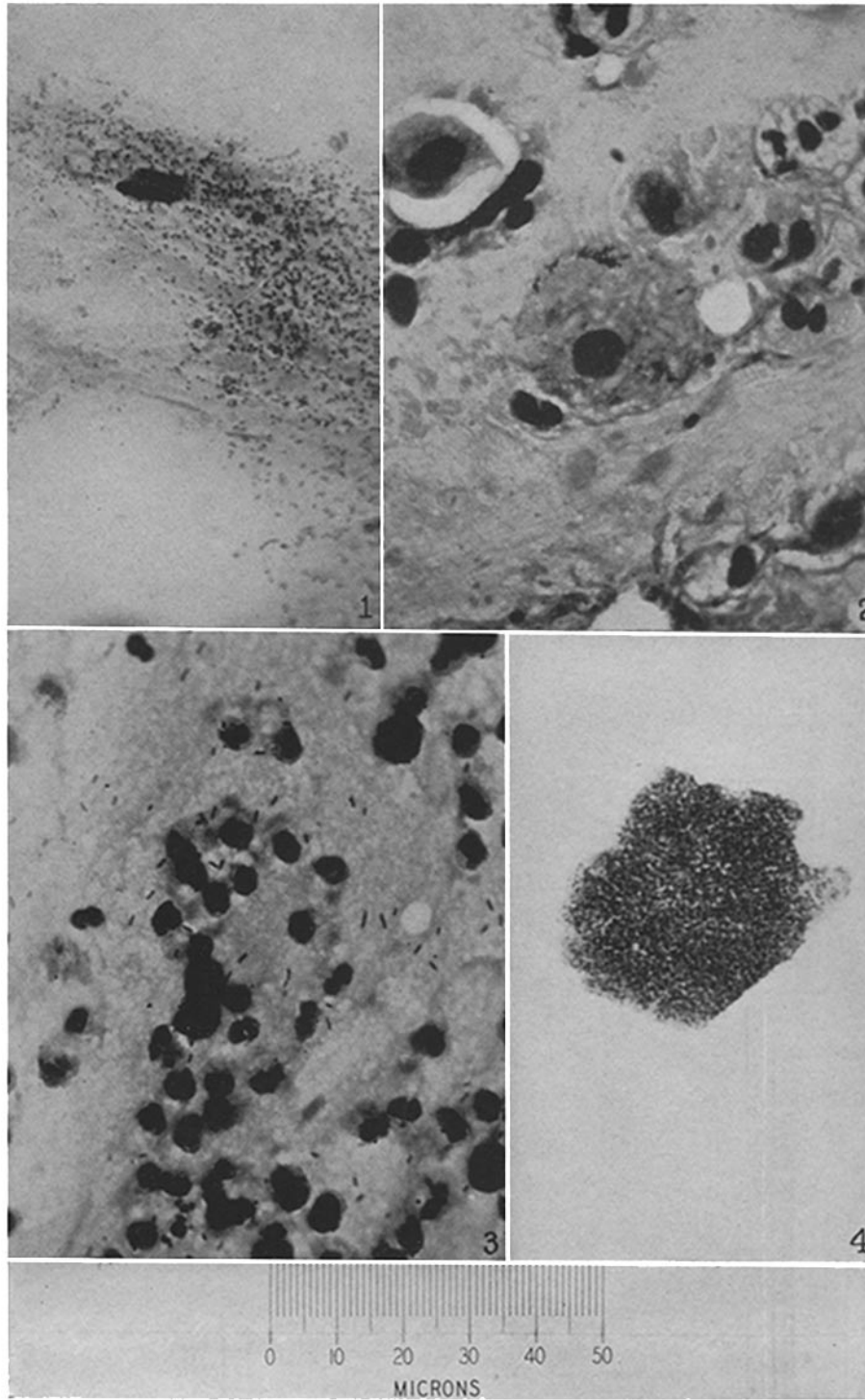
The preparations were all stained with Gram's method and magnified 920 diameters.

FIG. 1. Nasal exudate from a bird infected with the coryza of slow onset showing a cloud-like grouping of extracellular coccobacilliform bodies.

FIG. 2. Nasal exudate from a bird infected with the coryza of slow onset showing an epithelial cell containing several compact groupings of coccobacilliform bodies.

FIG. 3. Nasal exudate from a bird infected with a pure culture of *Hemophilus gallinarum* showing bacilli and leucocytes. The camera has reproduced a number of specks which were not conspicuous microscopically.

FIG. 4. Fluid from a 48 hour old blood agar slant culture of the X bacillus showing a compact clump of bacilli.



Photographed by J. A. Carlile

(Nelson: Uncomplicated coryza of domestic fowl. VI)