

## NERVE ENDINGS IN NUTRITIONAL MUSCULAR DYSTROPHY IN GUINEA PIGS

BY W. M. ROGERS, PH.D., A. M. PAPPENHEIMER, M.D.,  
AND MARIANNE GOETTSCHE, PH.D.

(From the Departments of Anatomy and Pathology, College of Physicians and  
Surgeons, Columbia University, New York)

PLATES 20 AND 21

(Received for publication, April 2, 1931)

In a previous article (1), dealing with nutritional muscular dystrophy in guinea pigs and rabbits, it was stated that no significant alterations were found in the central nervous system or larger peripheral nerve trunks. The question as to a possible primary degeneration of the muscular nerve endings was left for further study. The following observations indicate that the nerve endings are preserved even though the muscle fibers are profoundly altered.

### *Technique*

The method selected after comparison with several others was devised by one of the authors (2) and should be applied as follows:<sup>1</sup>

1. Fixation in Bouin's picro-aceto-formol—3 days or longer.
2. 70 per cent alcohol, many changes until most of the picric acid has disappeared,—24 hours or longer.
3. 2 per cent solution of ammonia in 80 per cent alcohol—24 hours.
4. 2 per cent solution of ammonia in 90 per cent alcohol—24 hours.
5. Absolute alcohol—2 hours, clear in chloroform, xylol, or cedar oil.  
The tissue is then embedded in paraffin in the usual manner. Sections are cut at 10 to 30  $\mu$ . After deparaffinizing, the slides remain in 90 per cent alcohol containing 1 per cent of ammonia for 3 hours.
6. Rapid rinsing in distilled water.
7. 40 per cent silver nitrate for 2 to 4 hours.
8. Rinse quickly with distilled water.

---

<sup>1</sup> We wish to thank Miss Marie Norkus for her assistance in developing and applying this technique.

9. 20 per cent acid or neutral formol is poured upon slide and allowed to remain for 5 minutes, followed by 5 per cent formol for 1 minute. Pour off without rinsing.

10. Diammoniacal silver solution which has been heated to 30–55°C. is poured *over* the slide which is held at an incline. Then more of this solution is poured *on* the slide which is placed horizontally under the microscope so that the liquid does not run off. Allow this to remain until the neurites are stained black while the section as a whole is a golden brown. The diammoniacal silver solution is made as follows:

To 4 cc. of 20 per cent silver nitrate add several drops of ammonium hydrate (28 per cent) to precipitate the silver. Then, with constant shaking, continue adding ammonium hydrate drop by drop until the precipitate is redissolved. Following this, add 1 drop of ammonium hydrate to every 2 cc. of the original 20 per cent solution of silver nitrate. To this add 4 cc. of distilled water.

11. Rinse in distilled water.

12. Tone with solution of gold chloride made as follows:

1 gm. gold chloride to 300 cc. distilled water. Add 50 drops of glacial acetic acid to every 5 cc. of gold chloride solution. Allow sections to stay in the toning solution for 10 to 15 minutes. The acetic acid bleaches the connective tissue.

13. Wash with distilled water.

14. Reduce the gold in 1 per cent oxalic acid for about 5 minutes, or until the sections become purple.

15. Fix in 5 per cent sodium hyposulfite for about 5 minutes.

16. Wash in running water or in several changes of water on the slide. Failure to wash well often causes stains on the sections.

17. Dehydrate; clear in carbol-xylol, then xylol, and mount in balsam.

Using this method, the nerve terminals are brought out with great clarity against the purplish muscle fibers, in which the striations are distinctly shown.

As is seen in Fig. 1, even the finest axons are impregnated, and can be followed to their terminations. They appear to end upon the surface of muscle fibers which have undergone complete hyaline necrosis. Such neurites show no obvious differences from those leading to normal muscle fibers.

Although it might seem probable that the complete disintegration and disappearance of the muscle fibers would lead to regressive changes in the nerve terminals, we have found no evidence that such is the case. On the contrary, beautifully preserved neurites, with terminal pads, may be seen amongst the columns of proliferative muscle nuclei (Figs. 2 and 3), and in the fat and connective tissue

which separates the still intact muscle fibers. It seems certain that the nerve terminals persist even after the fibers which they supply have undergone resorption and have been replaced by adipose and fibrous tissue.

It seems unnecessary in this note to review the rather contradictory literature upon the normal and pathological structure of the nerve endings in the muscles. The work upon the normal histology of motor nerve terminals has recently been summarized by Okamura (3). Tsunoda (4) has described swelling and increased tortuosity, followed by atrophy of the terminal branches and of the end-net of the axis cylinder, in experimental polyneuritis of the pigeon. We could find no similar changes in our preparations.

#### CONCLUSION

The nutritional muscle dystrophy of guinea pigs and rabbits is primarily a degeneration of the muscle fibers and is not associated with visible alterations of the peripheral nerves or their motor terminals.

#### BIBLIOGRAPHY

1. Goettsch, M., and Pappenheimer, A. M., *J. Exp. Med.*, 1931, **54**, 145.
2. Rogers, W. M., *Anat. Rec.*, 1931, **49**, 1.
3. Okamura, C., *Z. ges. Anat., 1. Abt.*, 1929, **91**, 519.
4. Tsunoda, T., *Virchows Arch. path. Anat.*, 1928, **267**, 413.

#### EXPLANATION OF PLATES

##### PLATE 20

FIG. 1. *a, b, c.* Guinea Pig 121. 145 days on Diet 11. Quadriceps femoris muscle. Rogers' stain. Preparation by Dr. Abner Wolf. Coarse and fine (sympathetic?) nerve fibers are seen to end upon the surface of the necrotic fibers.

##### PLATE 21

FIG. 2. Guinea Pig 115. 137 days on Diet 13 plus orange juice. Quadriceps femoris muscle showing loss of fibers, replacement of them by fat, multiplication of muscle nuclei, and persistence of neurites amongst the cell columns.

FIG. 3. Same muscle. Intact terminal arborizations in degenerated area. Oil immersion.

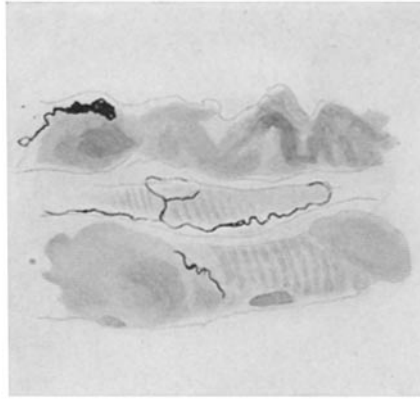

FIG. 1 *a*

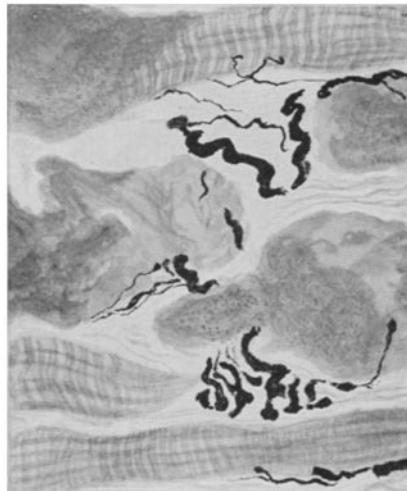

FIG. 1 *b*



FIG. 1 *c*

(Rogers *et al.*: Nerve endings in muscular dystrophy)

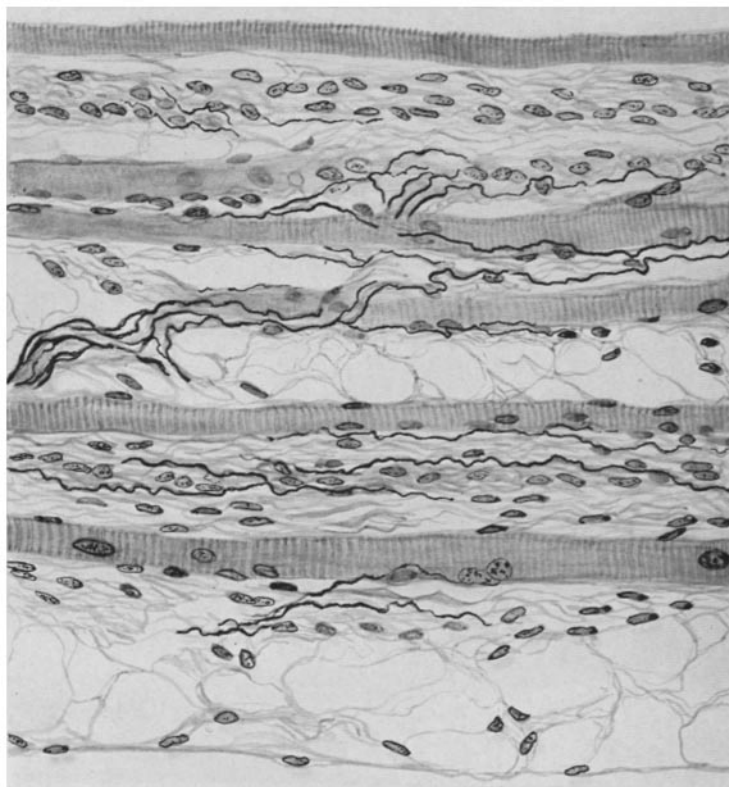


FIG. 2

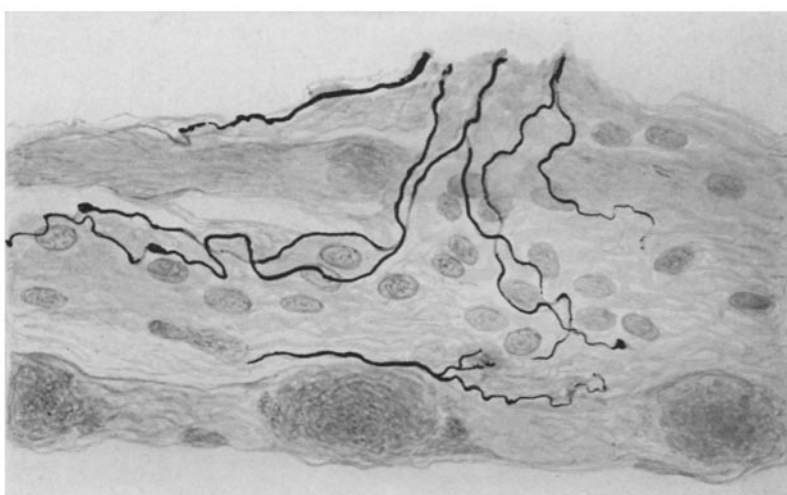


FIG. 3

(Rogers *et al.*: Nerve endings in muscular dystrophy)