

A CASE OF GENERAL GASEOUS EMPHYSEMA WITH GAS CYSTS IN THE BRAIN FORMED AFTER DEATH AND DUE TO BACILLUS MUCOSUS CAPSULATUS, WITH A CONSIDERATION OF THE GAS-PRODUCING PROPERTIES OF CERTAIN MEMBERS OF THIS GROUP IN THE CADAVERS OF ANIMALS.

BY W. T. HOWARD, JR., M. D.

(From the Pathological Laboratory of Lakeside Hospital, Cleveland, O.)

PLATE X.

My attention was directed to this subject by the following case:

M. D., female, white, aged 40 years, was admitted to Lakeside Hospital, service of Dr. H. S. Upson, December 24, 1898. On admission she was comatose and never regained consciousness. Her pulse was 108 to the minute, regular and rhythmic. Her respirations were of the Cheyne-Stokes type, apnœa lasting twenty seconds. The extremities were cold and cyanotic; the skin was cool and moist. Examination of the chest and abdomen showed nothing abnormal. There was incontinence of urine, and no urine could be obtained on catheterization; hence examination was impossible. Her friends stated that she was in the habit of taking large quantities of morphine. She died eight hours after admission. The clinical diagnosis was morphine poisoning.

No swelling or subcutaneous emphysema of the chest or other part of the body was noticed during life. Immediately after death the body was placed in the refrigerator, kept constantly at 30° F.

*Autopsy.—Anatomical Diagnosis:* General gaseous emphysema of the subcutaneous tissues, the heart, blood-vessels, liver, spleen and kidneys. Gas cysts of the brain. Septicæmia due to *B. mucosus capsulatus* (aërogenes group). Fatty degeneration and cloudy swelling of the heart, liver and kidneys. Chronic interstitial nephritis. Ulceration of the stomach and ileum.

The autopsy was begun 24 hours after death. The body was 157 cm. long, very cold; rigor mortis present. The skin over the posterior por-

tions of the body was of a deep purplish hue. The skin and subcutaneous tissues of the face, neck and chest were markedly swollen, and tympanitic on percussion. On section, the skin and subcutaneous tissues were crepitant to the touch and separated from the underlying structures. The subcutaneous and muscular tissues of the chest, neck and face were enormously distended with gas and marked emphysematous crackling was elicited on pressure. The circumference of the chest just above the mammæ was 108 cm. The head was of ordinary size, the scalp thick and firmly adherent. There were no wounds, contusions or abrasions about the face or head. The skull was of ordinary thickness. The dura mater showed no changes. All the sinuses contained dark fluid blood in which were a great number of large and small gas bubbles.

The meningeal vessels, both arteries and veins, contained a great number of gas bubbles. The veins were markedly congested. In the pia-arachnoid there were numerous small gas blebs. The cerebral convolutions were normal. The surfaces of the cerebrum and of the cerebellum showed no changes. There was no exudation, either serous or purulent, upon or in the pia-arachnoid. The structures at the base of the brain appeared normal.

On section the cerebrum was firm (frozen) and moderately congested throughout. The cortex cerebri appeared normal. In the internal capsule and in the lenticular nuclei, there were a large number of nearly round and oval gas cysts, varying from one to twelve millimetres in diameter. Near the centres of both cerebellar lobes, there were similar gas cysts varying from one to four millimetres in diameter. These cysts had perfectly smooth walls. The cerebellum was moderately congested. The pons and medulla both appeared normal on section. The arteries at the base were not thickened and appeared normal.

The spinal vertebræ were normal. Between the dura and the pia-arachnoid were a large number of large and small gas bubbles.

The extremities were free from œdema and emphysema. The abdomen was markedly swollen, measuring 105 cm. in circumference at the level of the umbilicus. The subcutaneous tissue was resonant on percussion, but no crackling was elicited. The peritoneal cavity and the intestines were distended with gas. The sternum, mediastinum and pleuræ were normal. Both lungs were voluminous, and showed small gas blebs under the pleuræ. On section the lungs were markedly congested, but crepitant throughout. Gas bubbles were expressed from the larger pulmonary blood-vessels. The trachea, larynx, and mouth were normal. The pericardium was normal.

The heart weighed 240 grammes. The myocardium was pale and lustreless, and here and there gas cysts of varying size, surrounded by hyperæmic zones, were seen. All the cavities contained dark red fluid blood with gas bubbles. The valves and orifices were normal. The coronary arteries and veins contained small gas bubbles.

The diaphragm was of a pale yellowish hue and felt soapy to the touch, while on section small gas bubbles were seen.

The liver was of ordinary size. The capsule was for the most part smooth. At the under surface of the right lobe, near the gall-bladder, small gas bubbles were found just beneath the peritoneum. On section the liver was rather longer than usual, and had a pale yellowish-gray appearance, with a soapy sensation to the touch. All the visible blood-vessels contained gas bubbles, but the typical appearance of "Schaum-leber" was not present. The bile-ducts and gall-bladder were normal. The tissues about the gall-bladder contained small gas bubbles.

The spleen weighed 175 grammes. The capsule contained small gas bubbles. On section the organ was of a dark red color, soapy to the touch, and contained a large number of small gas bubbles.

The two kidneys were of the same size and presented the same general appearances. Together they weighed 325 grammes. The capsules were slightly adherent, the surfaces smooth. The cortices were pale and of ordinary thickness. Both the cortex and the medulla contained small gas cysts. Small gas bubbles were found in the pelves and in the veins. The adrenals and the pancreas were negative. The mucous membrane of the œsophagus was soft and easily removed with the finger. The stomach was of ordinary size. The mucous membrane was markedly congested. Near the cardiac end there were several small ulcers, with indurated bases and edges. Just above the ileo-cæcal valve three Peyer's patches were the seats of small ulcers presenting firm borders. The mucous membrane of the colon and rectum was congested.

The ovaries and tubes were embedded in a mass of adhesions, but presented no changes of special interest.

The bladder, ureters, lymph glands, and the arteries were negative.

The venæ cavæ, the jugular, axillary, portal, hepatic, splenic, renal, and other abdominal veins contained gas bubbles.

**HISTOLOGICAL EXAMINATION OF HARDENED SECTIONS.**—*Central nervous system.*—The veins and capillaries of the pia-arachnoid, the sulci and the cerebral cortex contained great numbers of polymorphic bacilli, which were in some places seen also in the media and adventitia and in small numbers in the surrounding tissue. The bacilli in the vessels were

so numerous that the blood corpuscles were completely displaced. There was no inflammatory reaction. The ganglion cells stained well and there was no evidence of degeneration of the cortical tissue. Plate X, Figure 1 shows a cerebral vessel filled with bacilli.

The veins and capillaries of the pia-arachnoid over the pons, medulla and spinal cord contained great numbers of polymorphic bacilli. In the spinal meninges the vessels were dilated and crowded with bacilli. Some of the vessels were widely distended with gas and a varying number of bacilli were seen near the intima. In some places bacilli were found free in the tissues of the pia-arachnoid.

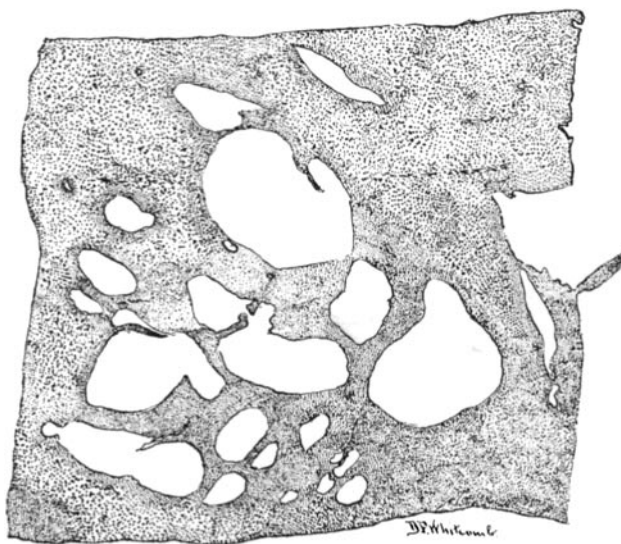

FIG. A.—Gas cysts in the brain.

Sections through the internal capsules and the lenticular nuclei showed large open spaces with regular walls (Fig. A). The tissues were pushed aside by the gas without any necrosis or liquefaction. The cells of the surrounding tissues stained well and appeared normal. There was entire absence of the cell degeneration about the gas cysts, described by Reuling and Herring<sup>1</sup> in their case of gas cysts of the brain. Along the walls of all the gas cysts polymorphic bacilli were seen in varying, and often in great numbers. In the neighborhood of the cysts, the veins and often the small arteries were filled with bacilli. Some of these vessels terminated in the gas cysts. Some, if not all of these cysts had their

<sup>1</sup> *Bulletin of the Johns Hopkins Hospital*, 1899, x, p. 62.

origin in dilatation or rupture of blood-vessels containing bacilli and gas.

In sections through the lateral ventricles the ependyma appeared normal.

The gas cysts in the cerebellum (Fig. B) were identical with those in the cerebrum.

In the internal capsules, lenticular nuclei, and cerebellum many of the veins and capillaries and some of the small arteries were crowded with small polymorphic bacilli. Some of the vessels of the cortex cerebri and of the pons and medulla contained bacilli. The spinal cord was free from gas cysts and its blood-vessels contained no bacilli. No degenerative changes were made out in the brain, pons, medulla, or cord. The ganglion cells were well preserved and stained well.

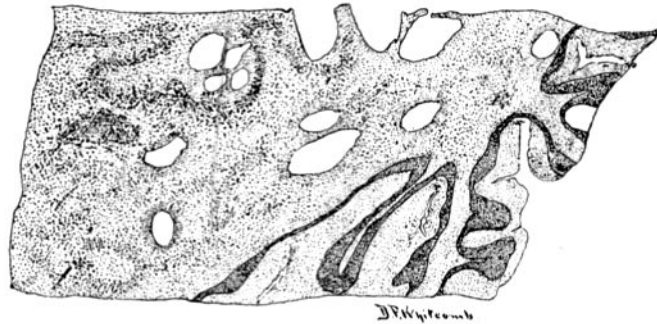

FIG. B.—Gas cysts in the cerebellum.

*Heart.*—In sections of the heart muscle the nuclei stained faintly and the cytoplasm took the eosin poorly. In some places the striation was indistinct and in others entirely lost. There were areas of marked segmentation of the muscle cells. In a number of small scattered areas the muscle tissue was broken up into a granular amorphous material. Many arteries, veins and capillaries were completely filled with polymorphic bacilli, which were also often found free in the tissues near the blood-vessels.

A large number of small smooth-walled gas cysts were found in the heart muscle. Along the margins of these cysts and in the neighboring tissues bacilli were present in large numbers.

*Lungs.*—Sections from both lungs showed marked œdema and congestion of the air vesicles, which often contained great numbers of polymorphic bacilli. The blood-vessels were congested, and contained a few bacilli. No gas cysts were seen.

*Liver.*—The interlobular connective tissue was increased in amount and in many places had encroached very much upon the liver lobules. In many of the interlobular spaces there was round-celled infiltration. There was no congestion of the blood-vessels. Fatty degeneration and cloudy swelling of the liver cells were marked and widespread. In many places the liver cells took the stain poorly, while in others they stained diffusely with eosin. The nuclei could not be made out. Some sections showed a number of gas holes, some of which were evidently due to dilatation of the central veins of lobules. The cysts varied very much in size.

Numerous bacilli were seen in the blood-vessels, especially in the intra-lobular capillaries and the branches of the hepatic vein. Many capillaries were widely dilated and contained no blood corpuscles but numbers of bacilli.

*Spleen.*—In the pulp there were few cells that were well preserved. The nuclei did not stain and the outlines of the cells were destroyed. Many cells did not take the eosin stain. The whole tissue had a peculiar amorphous appearance. A few of the Malpighian bodies were preserved. Here and there a few cells containing fat droplets were seen. The red blood corpuscles in the pulp and vessels were poorly preserved. There was no increase of polymorphonuclear leukocytes. No typical gas cysts were found in the spleen. Many of the blood-vessels contained myriads of polymorphic bacilli, the lumina of some being completely filled with them.

*Kidneys.*—The epithelial cells of the convoluted tubules were swollen and granular. The nuclei of many of the cells did not stain. The glomerular capillaries were congested. There was slight chronic interstitial nephritis, with well-marked chronic passive congestion. The large capsular veins and the arteries, veins and capillaries throughout the kidneys contained great numbers of polymorphic bacilli, the lumina of many of the vessels being completely filled with them. Bacilli were found in large numbers in the tissues, usually in the neighborhood of blood-vessels and within tubules. In many places the tubules were widely distended, forming gas cysts.

*Stomach.*—The superficial epithelium was lacking in many places. There was marked atrophy of the gastric tubules with round-celled infiltration of the mucosa. In sections through the ulcers only the deeper portions of the glands remained and sometimes both the glands and the muscularis mucosæ had disappeared. The submucosa was greatly thickened by a newly-formed granulation tissue rich in cells and blood-ves-

sels. The cells were fibroblasts, plasma cells and small round cells. A few polymorphonuclear leukocytes, but no eosinophilic cells were seen. No giant cells and no epithelioid cells were found. There was no special infiltration of cells about the blood-vessels and no caseation. Scattered through this granulation tissue, especially in the superficial portions, there were many polymorphic bacilli, quite similar to those found in other organs. No forms so large and thick as *Bacillus aërogenes capsulatus* were seen here or elsewhere in the organs. In some sections the veins of the submucosa were crowded with bacilli. The muscularis and serosa were normal.

Sections of the *small intestine* showed loss of the superficial epithelium with disintegration of the mucosa in places. In these areas the nuclei and cytoplasm did not stain and the cell outlines were lost. In this material there were numbers of bacilli similar to those found in the organs. The lymphoid tissue showed hyperplasia. In some places in the ileum the submucosa was infiltrated with plasma cells, but there was no granulation-tissue formation similar to that described in the stomach. No caseation and no giant cells were demonstrable. In one place near one of these areas the veins and capillaries were filled with bacilli.

Sections made from the subcutaneous fatty tissue of the neck showed a large number of larger and smaller round or oval gas spaces, the walls of which were lined with bacilli. There were no signs of inflammatory reaction. The tissues about these spaces were pushed aside and compressed. Bacilli were found in large numbers free in the tissue and in the small arteries, veins and capillaries.

Similar changes were found in sections of the pectoral muscles in which gas cysts were numerous. Many of the muscle cells had lost their striation, and in some the nuclei did not stain. Many bacilli were found in the tissues, blood-vessels and gas cysts.

**BACTERIOLOGICAL EXAMINATION.**—Smear preparations made at the time of the autopsy from the emphysematous subcutaneous tissue, the heart's blood, the lungs, liver, spleen, kidneys, cerebrospinal meninges, and brain, all showed great numbers of polymorphic bacilli, which occurred as almost round, oval, and short stout forms with rounded ends, and long thin filaments. They varied from 0.5 to 3 or even 5  $\mu$  in length, and were rarely more than 0.3 or 0.4  $\mu$  thick. Many were encapsulated. The capsules stained well by Welch's method. No thick bacilli resembling *B. aërogenes capsulatus* were seen, although careful search was made. Cultures were made from the subcutaneous tissue, the heart's blood, the liver, spleen, kidneys, lungs, brain, cerebral and spinal

meninges, upon blood-serum slants, and in glycerine-agar Petri plates. The cultures from each source, treated both aërobically and anaërobically, were kept in the incubator for twenty-four hours. Anaërobiosis was obtained by the use of Novy's jars.

In all the cultures, both blood-serum slants and Petri plates, the same microörganism grew abundantly and in pure culture. All the Petri plate cultures, both aërobic and anaërobic, showed a large number of round, raised, moist, smooth, opaque, greyish-white colonies. The deep colonies were small, irregular, finely granular, and of a deep brown color, when magnified fifty times. The superficial colonies were large (1 to 2 or 3 mm. in diameter), tended to spread, and microscopically showed irregular, greyish borders, with dark brown centres and a homogeneous appearance.

Cultures and coverslip preparations from all the plates showed the same organism, a polymorphic bacillus similar in all respects to those described in the fresh organs. No large thick bacilli were found in any of the cultures.

In the blood-serum slant cultures the colonies ran together forming a luxuriant spreading growth, in which it was difficult to separate individual colonies. The growth in these tubes was raised, moist, polished and porcelain-like. The water of condensation was cloudy. The growth stuck to the inoculating needle when it was removed from the culture, forming a ropy, mucus-like thread. Careful search failed to disclose any thick bacilli. Morphologically the bacilli in the blood-serum slants were identical with those found in the plate cultures and in the fresh organs.

Further study of this organism, found in pure culture in the subcutaneous tissues, brain, cerebrospinal meninges and other organs, gave the following results: Agar slants after 24 hours in the incubator, or 48 hours at room temperature, showed a luxuriant raised greyish-white, polished, porcelain-like growth, usually with serrated edges. Glycerine and glucose-agar slants gave the same growth. In both these media stab cultures showed abundant gas formation with splitting of the media. Gas bubbles were seen on the surface of the water of condensation, which was cloudy. On coagulated blood serum the growth was like that on agar; but here, in addition to appearing on the water of condensation, gas bubbles were also seen on the growth on the surface of the medium. Liquefaction of the medium did not occur.

On plate- and slant-cultures on gelatine the growth was similar to that on agar, though not so luxuriant. Gelatine was not liquefied. In stab cultures the growth occurred in the form of fine greyish-white colonies



along the track of the needle, with a flattened "nail-head" growth on the surface. Gas production did not occur in plain nutrient gelatine, but appeared in gelatine containing sugars.

On potato there was an abundant growth, best marked on the lower two thirds of the medium, where it was moist and of greyish-brown color. The upper third of the growth was usually dry and granular. The moist lower portion of the growth was porcelain-like and usually spread. Gas formation occurred in the growth, both on the medium and in the water about the potato.

In bouillon the growth was rapid and luxuriant, diffusely cloudy, with a white pellicle covering the surface. At the bottom of the tube there was a copious, greyish-white sediment, which, on shaking, was broken up into a stringy viscid mass.

In bouillon containing sugars abundant gas formation took place.

In Dunham's peptone solution there was a copious growth without indol formation. Blue litmus milk after 24 hours at body temperature had a pink tinge without coagulation. After 48 hours the medium was white with firm coagulation.

The organism was non-motile and stained readily and uniformly with the usual aniline stains. It decolorized slowly when treated by Gram's method. Spore formation did not occur. Capsule formation was sometimes seen in blood-serum cultures, and was constant in the blood and tissue juices of animals dying after inoculation with the bacillus.

*Pathogenesis.*—White mice died in 12 hours after inoculation with small doses of bouillon, blood-serum, or agar cultures either subcutaneously or intraperitoneally. The bacillus was found at the seat of inoculation, in the blood and in the various organs.

Guinea-pigs were killed within the same time by either subcutaneous or intraperitoneal inoculation. In the peritoneal cavity there was an excess of lymph containing peritoneal cells and leukocytes. Many of these cells enclosed bacilli, a large proportion of which were capsulated.

Rabbits succumbed to small doses (0.25 to 0.5 cc.) of a bouillon culture administered either intravenously or intraperitoneally. Capsulated bacilli were found in the blood and various organs. No gas formation took place in the body during life, but when the animal was kept in a warm place after death, gas was formed.

Rabbits inoculated intravenously with 0.5 cc. of a 24-hour old bouillon culture of the bacillus, killed five minutes afterwards and put in the incubator at body temperature, showed general subcutaneous gaseous emphysema, with gas cavities in the heart, blood-vessels, liver, spleen,

kidneys and free gas in the abdominal cavity with the bacillus in pure culture in the various organs. During the autopsy rabbits were inoculated intravenously with heart's blood, and with blood and tissue juice from the subcutaneous tissues of the chest, and killed. After remaining for 24 hours in a warm place (25 to 30° C.) they were found enormously swollen. At autopsy there was general gaseous emphysema of the subcutaneous tissues and typical "Schaumorgane." Careful examination of coverslip preparations failed to show the long and short thick forms of *B. aërogenes capsulatus*. There were, instead, great numbers of bacilli morphologically identical with those inoculated. Many capsulated forms were seen.

From the above it is seen that in this case there was septicæmia followed by general gaseous emphysema of the body, the latter developing in all probability after death, caused by an organism belonging to the group *B. mucosus capsulatus*.

I have compared the bacillus of this case with my *B. mucosus capsulatus* of hæmorrhagic septicæmia in man<sup>2</sup> and with three other similar bacilli obtained at autopsies during the past winter, and can find no differences, which would seem sufficient to warrant an attempt at the formation of a new class.

This bacillus is practically identical with my bacillus of hæmorrhagic septicæmia except that it gives up the stain more readily when treated by Gram's method. It is an active gas producer in sugar bouillon. When grown in one per cent glucose, saccharose, or lactose bouillon for 48 hours, gas displaces 60% of the medium in the upright arm of the fermentation tube in the case of glucose, 70% with saccharose, and 62% with lactose bouillon. It also produces a large amount of acid, the amount of normal NaOH solution required to neutralize 1 cc. of a 48-hour-old bouillon culture being for glucose bouillon cultures  $\frac{1}{3}$  cc., for saccharose or lactose cultures  $\frac{1}{2}$  cc.

The tabulated results of a comparative study of the gas and acid production of the bacillus of this case, of similar bacilli obtained at autopsies during the winter, and of my bacillus of hæmorrhagic septicæmia in human beings are given below. For convenience the bacilli

<sup>2</sup> *Journal of Experimental Medicine*, 1899, iv, p. 149.

will be styled No. 34 (the bacillus of the present case), No. 45, No. 46, No. 68 (the numbers of the autopsies from which they were obtained), and H. S. (my bacillus of hæmorrhagic septicæmia in man). Autopsy No. 45 was a case of general arteriosclerosis, with thrombosis of the pulmonary artery and pulmonary infarctions, with *B. mucosus capsulatus* in the lungs. No. 46 was a case of chronic ulcerative colitis and proctitis with abscess of the left thigh, and a fistulous track communicating with the colon; thrombosis of the pulmonary artery and purulent bronchitis. *B. coli communis* was obtained in cultures from the colon, the abscess of the thigh, and the heart's blood, liver, and spleen, while *B. mucosus capsulatus* grew in pure culture from the lungs. Autopsy No. 68 was a case of sarcoma of the right frontal lobe of the cerebrum, and acute croupous pneumonia. *B. mucosus capsulatus* was obtained in pure culture from the affected lung and the pleura, and also from the uterus. Bacillus H. S. was obtained from the heart's blood and organs of a case of hæmorrhagic septicæmia.<sup>3</sup> In none of these cases, except No. 34 (the present case), was there gaseous emphysema.

TABLE OF COMPARATIVE GAS PRODUCTION IN SUGAR BOUILLON.

Bacillus.	1% glucose bouillon.	1% saccharose bouillon.	1% lactose bouillon.	
No. 34	60%	70%	62%	The per cent refers to the ratio of liquid displaced by gas in the upright arm of the fermentation tube.
H. S.	65%	73%	50%	
No. 45	60%	75%	80%	
No. 68	30%	70%	61%	

TABLE OF COMPARATIVE ACID PRODUCTION IN SUGAR BOUILLON.

Bacillus.	1% glucose bouillon.	1% saccharose bouillon.	1% lactose bouillon.	
No. 34	1/13	1/20	1/20	Fractions represent amount, expressed in cc., of normal NaOH solution required to neutralize 1 cc. of bouillon culture.
H. S.	1/13	1/25	1/15	
No. 45	1/30	1/25	1/15	
No. 68	1/25	1/30	1/25	
No. 46	1/30	1/30	1/20	

Strong<sup>4</sup> after an elaborate study of various capsulated bacilli, based more especially upon their gas and acid production in glucose, saccharose and lactose bouillons, divides them into two groups: (1) the Friedländer group, comprising *B. pneumoniæ* Friedländer, *B. ozænæ* Fasching, *B. sputigenus crassus*, Bacillus Wright and Mallory, and

<sup>3</sup> See reference No. 2.

<sup>4</sup> A Study of the Encapsulated Bacilli, *Journal of the Boston Society of the Medical Sciences*, 1899, iii, p. 185.

possibly *B. rhinoscleromatis*, in which gas-production is most abundant with saccharose, slightly less with glucose, scanty or entirely absent with lactose; slight or no acid formation with lactose; and no coagulation of milk; and (2) the *aërogenes* group with "more abundant and constant gas formation on all three media; rapid coagulation of milk; and equal amounts of acid formation on all three sugars."

A glance at the tables shows that all four of our bacilli belong to the latter group.

In order to test the relative gas-producing properties of these bacilli in the animal body, rabbits were inoculated intravenously with 48-hour old glucose bouillon cultures of each bacillus. All the rabbits died within 24 hours, without any development of gaseous emphysema during life.

A second group of rabbits were inoculated intravenously, each with 1 cc. of a 24-hour old glucose bouillon culture, which was followed in a few minutes by an intravenous inoculation of 2 cc. of a 20 per cent solution of glucose in sterile distilled water. The rabbits were killed five minutes later and put in the incubator for eight hours, after which time there had developed a slight subcutaneous emphysema, most marked in rabbits inoculated with bacillus 34, and bacillus H. S. The rabbits were all kept sixteen hours longer in a hood at 28° C., when they were found very much swollen. At autopsy they all showed very much the same changes. The subcutaneous tissues of the chest, neck and axillæ were ballooned up and gave distinct emphysematous crackling on pressure. There was usually slight emphysema of the tissues of the abdominal wall and of the thighs. The abdomen was distended with gas. In all the animals the liver was dark greyish-brown in color, soft, and very friable, with emphysematous crackling on pressure, and a peculiar soapy sensation to the touch. The livers were disintegrating. The heart contained dark red blood with a few gas bubbles. Small gas bubbles were sometimes seen in the myocardium. The lungs were distended with gas and well preserved. The spleen showed no special changes. The kidneys showed a few gas cavities, and on pressure gas bubbles escaped from the blood-vessels. In the kidneys of the H. S. rabbit the gas cavities were especially well marked (Plate X, Fig. 2).

A third set of rabbits received intravenous inoculations of 1 cc. of one per cent lactose bouillon cultures of bacilli and a few minutes later 1 cc. of a 10 per cent solution of lactose in sterile distilled water. These

animals were killed five minutes afterwards and treated in the same manner as the second set. At the end of 24 hours they showed subcutaneous gaseous emphysema, and the same visceral changes described for the second set.

The first set of animals (those killed in twenty-four hours by intravenous inoculation of glucose bouillon cultures of the bacilli, but receiving no sugar injection) after remaining in a hood kept at 28° C. for twenty-four hours were very much swollen. The subcutaneous tissues contained considerable gas. Gas was also present in the peritoneal cavity, in the heart and blood-vessels, liver and kidneys. The liver had the same appearances as described for the rabbits inoculated with glucose and lactose. In these animals the gas formation was distinct, but not so abundant as in animals receiving glucose or lactose solutions before death. In several rabbits the stomach wall had ruptured.

In the animals receiving lactose the gas formation was most marked and in these there was a strong odor of putrefaction. The muscles of the chest and thigh were beginning to soften, and on section a thin dark brown juice escaped. Two control rabbits killed at the time of the above experiments and kept under the same conditions for thirty-six hours showed no gas production.

At the autopsies on these animals the bacilli inoculated were recovered in pure culture from the subcutaneous tissues and the heart, lungs, liver, kidneys, in both coverslip preparations and in cultures, both aerobic and anaerobic cultures being made. As a further precaution coverslip preparations were stained by Gram's method. The organisms obtained on the coverslips decolorized completely by Gram, with the exception of the bacillus H. S. By these precautions *B. aërogenes capsulatus* was excluded as a post-mortem invader in these experiments.

**HISTOLOGICAL EXAMINATION.**—Portions of the heart, lungs, liver, spleen, kidneys, muscle, and subcutaneous tissues of the axillæ from each of the various rabbits were hardened in formalin, sectioned and stained with eosin and methylene blue. Very much the same changes were found in the various organs.

The muscle fibres of the heart stained diffusely with eosin; the striæ were lost, and there was segmentation of many of the muscle cells. Only a few nuclei of muscle cells took the blue stain. The cells of the vascular walls usually stained. Large numbers of bacilli were seen in every field of the microscope. They were usually in capillaries and small veins, but were sometimes found free in the tissues. In the sections from the lactose rabbit, a few small gas cysts were found. The lungs

were well preserved and the cells stained well; the blood-vessels and many of the alveoli contained great numbers of bacilli. Some of the alveoli were distended to five or six times their ordinary size and about their margins bacilli were found. The livers showed most marked changes. In most sections the outlines of the liver lobules were entirely lost and the capillary walls had disappeared. There were very few well preserved liver cells in any of the sections. The liver cells were fused together into rows or columns of homogeneous material, in which no nuclei and no cell structure could be made out. These rows and columns were separated by small spaces, corresponding to the capillary spaces. In these large numbers of bacilli were seen. There were no well-defined gas cysts, but the tissue contained a number of irregular spaces. In some sections, especially in those from 46 (lactose), the portal veins were well preserved, and contained red blood cells and bacilli.

The kidneys were fairly well preserved and the nuclei and cell bodies stained well. In all the kidneys, however, in scattered areas, the nuclei of the epithelial cells of the tubules and the cells of the glomeruli refused the stain, while the cytoplasm stained diffusely with eosin and had a granular, coagulated appearance, resembling that of coagulative necrosis. In some places, however, the cells had fused together and presented a homogeneous appearance. In the areas of cellular change the capillaries contained large numbers of bacilli. Most of the veins and nearly all the capillaries contained bacilli in varying numbers. In some sections, as was especially well shown in the kidney of the rabbit inoculated with bacillus H. S. and lactose solution, well marked gas cysts from a pin's point to one or two millimetres in diameter were found. The tissues about these cysts were pushed aside and compressed and large numbers of bacilli were found along their walls. The subcutaneous tissue and muscle collapsed on removal from the body, so that no gas cysts were found in sections made from them. These tissues, however, contained great numbers of bacilli. The bacilli found in the various organs of these animals were apparently of the same species. They varied very much in length, from short oval, almost round forms to threads 6 to 8  $\mu$  in length. The long forms were thinner than *B. aërogenes capsulatus*, and usually had square ends.

Reuling and Herring<sup>5</sup> have reported a case of cavities in the brain produced by *B. aërogenes capsulatus*. The identification of

<sup>5</sup> *Bulletin of the Johns Hopkins Hospital*, 1899, x, p. 62.

this bacillus in their case depended upon the morphological appearances of the organism in the hardened sections and upon the lesions in the tissues. The cysts were not discovered until after the brain had been hardened in formalin; hence cultures and animal experiments were not made.

In the case of gas cysts with abscess of the brain and cerebrospinal meningitis, and general gaseous emphysema, reported by me,<sup>6</sup> the causal relation of *Bacillus aërogenes capsulatus* was established by coverslip preparations, cultures, animal experiments and sections of the hardened tissues.

In view of the present case one cannot agree with Reuling and Herring in concluding that *B. aërogenes capsulatus* was necessarily the cause of the lesions in the two cases of "holes in the brain" with cysts in the heart, lungs, liver, and kidneys, described by Savage and White<sup>7</sup> as cases of "universal cystic degeneration." In the light of our present knowledge, however, it is almost certain that the cysts in these cases were due to the agency of gas-producing bacteria, and probably, on account of its common occurrence in this rôle, to *Bacillus aërogenes capsulatus*.

#### SUMMARY.

In the case reported in this article there was septicæmia with special localization of the microorganisms in the brain, with gas cysts of the brain and general gaseous emphysema due to *Bacillus mucosus capsulatus* (*aërogenes* group).

The bacillus isolated from the organs of this case, as well as other members of the *aërogenic* group of *Bacillus mucosus capsulatus* can cause general gaseous emphysema in the cadavers of rabbits, either with or without the intravenous injection of sugar before the animal is killed, the gas, however, being most abundant and rapidly formed in the former case.

It is not impossible that some of the published cases of gaseous emphysema in which a bacteriological examination was not made,

<sup>6</sup> *Bulletin of the Johns Hopkins Hospital*, 1899, x, p. 66.

<sup>7</sup> *Trans. Path. Soc. London*, 1883, xxxiv, p. 1.

may have been due to members of the *Bacillus mucosus capsulatus* group.

Dr. Welch has called my attention to the possibility that diabetes may have existed in the case reported in this article. As no examination of the urine could be made, this possibility must be admitted. There is evidence that certain bacteria incapable of producing gas in tissues and organs of the body under other conditions may do so in diabetics on account of the presence of an abundance of sugar.

DESCRIPTION OF PLATE X.

Fig. 1.—Photograph showing *B. mucosus capsulatus* in a cerebral blood-vessel.

Fig. 2.—Photograph showing gas-cysts and masses of bacteria (*B. mucosus capsulatus*) in rabbit's kidney.



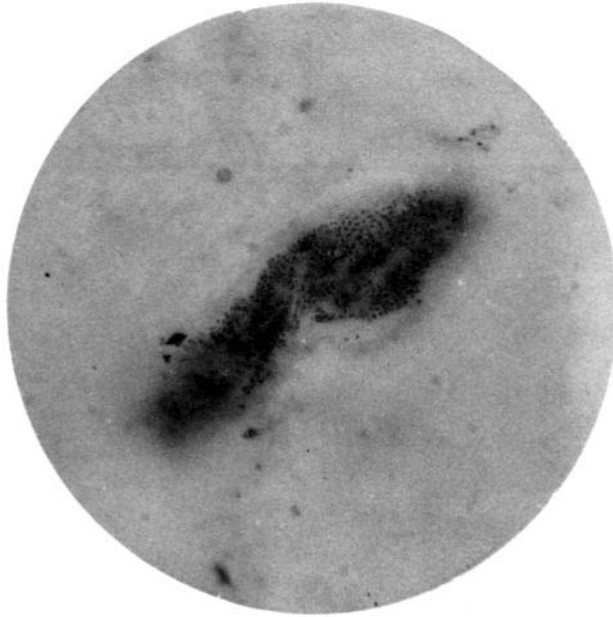


FIG. 1.

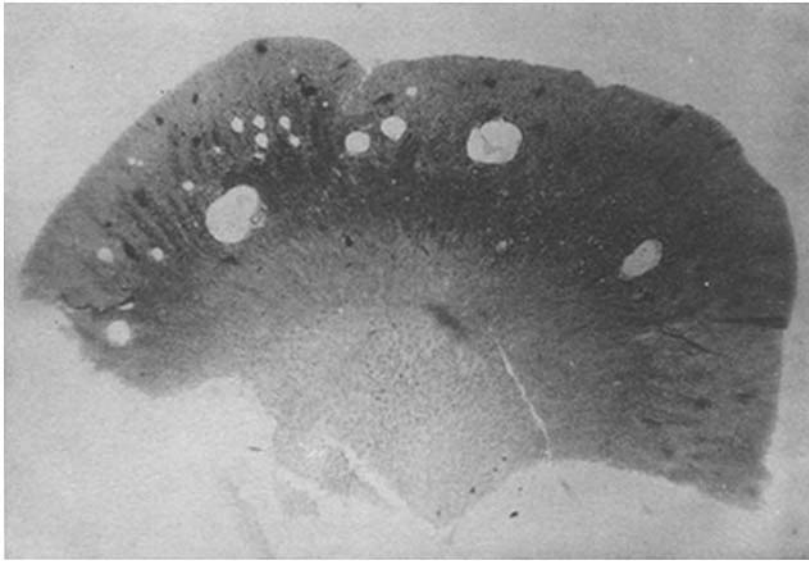


FIG. 2.