

THE EFFECT OF ALCOHOL ON THE REPRODUCTIVE TISSUES.

By ADA HART ARLITT, PH. D., AND H. GIDEON WELLS, M.D.

(From the Departments of Psychology and Pathology of the University of Chicago and the Otho S. A. Sprague Memorial Institute, Chicago.)

PLATES 57 TO 60.

(Received for publication, July 24, 1917.)

That alcohol may produce distinct anatomical changes in the testicles of those who use it in excess has been observed from time to time by pathologists for many years, and yet this fact does not seem to be widely known or generally taken into account in considering the effects of alcoholism.

HISTORICAL.

As long ago as 1837, Rösch¹ described degenerative changes in the testicles of alcoholics, and Lancereaux described parenchymatous degeneration of the seminal tubules. In 1877 Schlemmer² discussed the effects of alcoholism on the testicles, and noted that it often caused fatty degeneration of the seminal epithelium, decrease in the number of spermatozoa, and pigmentation of the seminal fluid. Rheinstaedter³ (1879) and Curschmann⁴ attributed loss or decrease in testicle function to chronic alcoholism, the former stating that in his experience excessive beer drinking had a greater effect than wines or distilled liquors.

Busch⁵ (1882) studied the testicles in 100 consecutive autopsies of adult males and found 27 without spermatozoa, 39 with few, and 34 with many. Although phthisis and other chronic diseases furnished many cases of azoospermia, he observed that this condition occurred frequently in alcoholics, especially when associated with cirrhosis.

¹ Rösch, cited by Forel.¹³

² Schlemmer, A., *Vrtljschr. gerichtl. Med.*, 1877, xxvii, 444.

³ Rheinstaedter, cited by Busch.⁵

⁴ Curschmann, cited by Busch.⁵

⁵ Busch, A., *Z. Biol.*, 1882, xviii, 496.

In 1898 Simmonds⁶ reported the study of 1,000 male bodies, of which 125 showed azoospermia. As previously observed by Busch, Simmonds found chronic diseases responsible for many cases, the incidence of azoospermia in cancer cases being 7 per cent, in chronic nervous diseases 14 per cent, in phthisis 18 per cent, while of the chronic alcoholics 60 per cent had no spermatozoa. Of all autopsied males, 5 per cent were sterile through the use of alcohol, as against 3.3 per cent from genital diseases. He also found that mechanical occlusion of the seminal tract, even of years' duration, seldom causes atrophy of the testicles or absence of spermatozoa in the tubules.

Bertholet⁷ (1909) made a report of the findings in 75 bodies of men dying at from 15 to 91 years of age, of whom 39 were habitual drinkers. Of the 39 alcoholics, only 2 had testicles that did not show atrophy of the parenchyma and sclerosis of the stroma. The most marked change occurred in alcoholics who died of tuberculosis or cirrhosis. Of the two alcoholics without atrophy, one was a man but 24 years old, and the other died of an acute intestinal obstruction. Bertholet describes the changes in detail. Generally the testicles are noticeably small and firm, because of atrophy of the epithelium and increase in the fibrous tissue. The spermatogonia are highly atrophic, the nuclei cannot be stained distinctly with hemalum, and it is impossible to distinguish between spermatocytes and spermatids, because they are all in the resting stage and show no mitosis or spermatozoa production. The cells of Leydig, on the other hand, seem to be increased in size, number, and staining intensity of the cytoplasm. The basal membrane is much thickened by concentrically arranged lamellæ and spindle cells; there is also an increase in the connective tissue between the tubules, with sometimes a slight round cell infiltration. The atrophy and azoospermia was complete in 24 of the 37, including 7 who died of cirrhosis; in but 4 was the change of only insignificant degree. Although similar changes of slight degree were found in non-alcoholics, the advanced changes were seen only in those who drank heavily. Even in senility the atrophy and fibrosis were less marked than in the alcoholics.

Since the reports of Simmonds and Bertholet, a few other papers have appeared corroborating their observations in all essentials, although not all investigators on alcoholism have considered the sex cells. Thus Fahr,⁸ in his study of the anatomical changes in 309 alcoholics, makes no mention of the generative tract or the occurrence of changes in these tissues in the guinea pigs that he subjected to experimental alcoholism.

Weichselbaum and Kyrle⁹ (1912) have furnished one of the best contributions to this subject, having carefully studied the testicles of 67 habitual alcoholics. They entirely support Simmonds' and Bertholet's conclusion that chronic

⁶ Simmonds, *Berl. klin. Woch.*, 1898, xxxv, 806.

⁷ Bertholet, E., *Centr. allg. Path. u. path. Anat.*, 1909, xx, 1062.

⁸ Fahr, *Verhandl. deutsch. path. Ges.*, 1909, xiii, 162.

⁹ Weichselbaum, A., and Kyrle, J., *Sitzungsber. Akad. Wien.*, 1912, cxxi, 51.

alcoholism constantly causes retrogressive changes in the testicles independent of senility or chronic diseases, even to the point of complete loss of the seminal epithelium. Also they corroborate the observation that the most marked changes occur in the testicles in alcoholism with cirrhosis. They too find that tuberculosis and cancer may produce similar changes, usually of mild degree, but alcoholism of itself produces marked changes without the coexistence of any other disease. Their paper contains a detailed description of the histological changes observed.

Because of the repeated observation that alcoholics with cirrhosis show especially marked changes in the testicles, Schopper¹⁰ investigated the effect of liver injury on the testicles. He found that animals (rabbits, dogs, and rats) from which a large portion of the liver had been removed, or in which the liver had been injured by exposure to Roentgen rays, exhibited marked changes in the testicles. These changes consisted in a cessation of spermatogenesis, transudation into the interstitial tissue, desquamation of the epithelial cells with formation of multinucleated cells, and even complete loss of the epithelium with increase in the interstitial cells.

In connection with his studies on the effect of parental alcoholism on the development of the offspring, Stockard¹¹ stated that guinea pigs given alcohol for as long as 19 months by inhalation, and therefore in unknown quantity, were still good breeders, and when killed showed no changes in the testicles. Ovaries of females similarly treated also showed no recognizable structural changes. On the other hand, Riddle and Basset¹² found that doves and pigeons made to inhale alcohol 1 to 2 hours daily for a few weeks produced eggs with yolks smaller than those in the eggs laid before the alcoholism. In general, however, the possible anatomical changes in the ovaries seem not to have been considered by pathologists, and the only mention we can find of this topic is contained in the review of Forel,¹³ who says, "more recently Bertholet has also demonstrated atrophy of the ovaries and ova of an alcoholic woman," but no reference is given and we have been unable to locate this statement in Bertholet's writings.

The only investigation of the influence of experimental alcoholism on the testicles of animals that we can find, beyond Stockard's negative results, is described by Bouin and Garnier,¹⁴ and unfortunately this report concerns only an isolated observation. It is stated by these authors that in the course of experiments on the effect of chronic alcoholism on the white rat, marked alterations were observed in the testicles of two animals that had been fed alcohol for 8 and 11 months respectively. No mention is made of how many animals were studied in

¹⁰ Schopper, K. J., *Frankfurter Z. Path.*, 1911, viii, 169.

¹¹ Stockard, C. R., *Arch. Int. Med.*, 1912, x, 374; *Arch. Entwicklungsmechn. Organ.*, 1912-13, xxxv, 3. Stockard, C. R., and Papanicolaou, G., *Am. Naturalist*, 1916, i, 65.

¹² Riddle, O., and Basset, G. C., *Am. J. Physiol.*, 1916, xli, 425.

¹³ Forel, A., *Münch. med. Woch.*, 1911, lviii, 2596.

¹⁴ Bouin, P., and Garnier, C., *Compt. rend. Soc. biol.*, 1900, lii, 23.

all, or whether the other animals showed any changes in the testicles. In these two animals there was marked atrophy of the seminal tubules, often with almost complete disappearance of the germinal epithelium, and in none was the epithelium normal. Between the tubules was found an accumulation of lymph, but no fibrosis or arteriosclerosis. In the lumen of the tubules few spermatozoa were found, but there was much desquamation of the epithelium, and often fusion of the cells into masses. Pyknosis and karyolysis were common, and the Sertoli cells often showed amitotic division. Before degenerating completely the germinal cells pass through various stages of altered vitality, which, the authors suggest, explains the frequency of abnormalities in the offspring of alcoholics. We cannot find that these authors have published elsewhere further details of their investigations in this field.

General Physical Changes Due to Alcohol.

In a series of rats fed alcohol for varying periods of time to determine the effect of alcohol on the psychology of their offspring, an opportunity was given to observe the effect of chronic alcoholism on these animals.¹⁵ Altogether we examined 15 male rats thus treated, 6 male rats of the second generation derived from them, 18 male rats of the third generation, and 8 male rats of the fourth generation. Approximately the same number of females was also studied. From each animal, with a few exceptions, the following organs were studied: lung, liver, kidney, spleen, stomach, heart, and sex glands. The animals were all killed, while in apparent health, with illuminating gas. They were all of about the same age, 6 to 9 months, except in the case of the rats fed 0.5 cc. for 10 months; these rats were 13 months old. All had been fed and cared for under identical conditions except for the administration of alcohol admixed with the food in quantities of from 0.25 cc. to 2.25 cc. per day, for periods varying from 2 to 10 months. The effect of the alcohol on the rats receiving it was, except for those fed for very long periods, to lessen learning capacity in almost direct proportion to the amount of the dose and the duration of the period during which it was administered.

The effect on body weight was also marked. Animals receiving 2.25 cc. *per diem* rate either gained weight far more slowly than the normal animals, or, as in some instances, actually lost weight though in the

¹⁵ The results of the psychological study will be published shortly in *Psychol. Monog. Suppl.*

growing period. As for the offspring, the observed physical effects were, in the case of the offspring of rats receiving 0.5 cc., a decrease in size and lessened fertility. This was accompanied by a marked decrease in learning capacity. The offspring of animals receiving 0.25 cc. showed no marked physical changes and were, as to intelligent behavior, generally on a par with, if not actually superior to, the offspring of normal animals.

The microscopic changes in all structures except the sex glands may be summarized briefly. Nearly all showed more or less pulmonary infection of the type common in rats, consisting in the less advanced stages of a chronic bronchitis with much cellular infiltration and hyperplasia of the bronchial walls. Many showed extension of the process to the adjacent alveoli with a frank mucopurulent bronchopneumonia. The degree of this change seemed to have little effect on the conditions in the other organs, and bore no relation whatever to the changes observed in the sex glands.

In the liver there were often varying degrees of hydropic vacuolization of cells, this condition occurring in about half the specimens. Focal necrosis was found in about one-fourth, severe in but a few. These changes bore no reference to the severity of the lung infection or to whether alcohol had been administered, as shown by tabulation and comparison of the results. Occasionally a slight periportal round cell infiltration was found, but this also was independent of other conditions. Even in the rats that received large quantities of alcohol for some months, the livers showed no more change than in the others. There was nothing found at all resembling cirrhosis.

The kidneys showed commonly a slight degree of vacuolization of the tubular epithelium, which was possibly slightly more general in the alcohol animals than in the others. Two animals in which the kidneys showed slight formation of granular casts had received much alcohol. That the alcohol was the cause of the renal changes is probable, especially in view of the great amount of cast formation commonly observed in the urine of patients with acute alcoholism, but this is by no means certain.

In the stomachs of a few of the rats receiving alcohol there seemed to be slightly more round cells in the mucosa and submucosa than normally, but the changes were not marked enough to be considered as

distinctly inflammatory. In two of the alcoholized rats the gastric glands showed more mucus content than was seen in any of the other animals, and hence this change may be ascribable to the alcohol. The slight effect of the alcohol on the stomach of the rats corresponds to the relatively normal condition of the gastric mucosa of human alcoholics observed by Hirsch.¹⁶

The heart, spleen, and adrenals usually showed no changes, and in no instance changes that occurred in the alcoholized rats and not in the others.

Pathological Changes in the Reproductive Tissues.

Only the testicles showed definite changes, but here the effects were so marked, and so nearly constant, that they stand out conspicuously as the result of the alcohol feeding. Of the fifteen male rats treated with alcohol, the testicles of not more than two or three failed to show noteworthy changes, and only one could be called normal. Several different types of changes were observed, and one that attracted attention at once was an apparent decrease in the size of the seminiferous tubules, and in several instances a distinct decrease in the size of the testicle itself. Measurements were made of the tubules in the testicles from thirty-seven rats, twenty-five tubules being measured from each testicle to secure adequate representation, and then the average diameter was calculated.¹⁷ The results of measurements in the several groups are given in Table I.

TABLE I.

No. of animals.	Minimum diameter.	Maximum diameter.	Average diameter.
6, 2nd generation rats.....	16.00*	19.16	17.26
18, 3rd " ".....	15.08†	22.60	17.50
8, 4th " ".....	15.56	18.32	17.08
15, alcoholized rats.....	10.00	18.24	14.65

* The measurements as recorded are the number of ocular micrometer spaces, not translated into microns. Each ocular micrometer space = 0.0155 mm.

† One very abnormal testicle in this series, measuring but 12.12, is not included.

¹⁶ Hirsch, E. F., *Arch. Int. Med.*, 1916, xvii, 354.

¹⁷ For these measurements we are indebted to Miss C. L. Chapin.

These measurements show at once that there is a distinct decrease in the size of the seminal tubules of the rats that had received alcohol, although in a few rats this change is not present. However, as Table II shows, but two of the fifteen rats that received alcohol had as large tubules as the average seminal tubules of their descendants that had not received alcohol. It also shows that the decrease in size does not vary directly with the amount of alcohol the rat had received. The tubules of normal rats of other strains corresponded in size to the tubules of the second, third, and fourth generation rats.

TABLE II.

Rat No.	Daily dose.	Time.	Diameter of tubules.	Histological changes summarized.
	cc.	mos		
1	0.25	2	13.40	Many defective spermatozoa; number decreased.
2	0.25	2	15.04	Spermatozoa decreased.
3	0.25	4	13.68	Few spermatozoa; mostly defective.
4	0.5	3	17.12	Nearly normal.
5	0.5	3	16.16	A few inactive tubules; mostly normal.
6	0.5	3	18.24	" " " " " "
7	0.5	10	11.32	Marked atrophy with intertubular edema; almost no spermatozoa, and these defective.
8	0.5	10	16.76	Much intertubular edema; most of tubules nearly normal, but number of spermatozoa decreased.
9	2.0	6	14.32	Very few spermatozoa; much desquamation.
10	2.0	6	14.16	Much desquamation and degeneration of epithelium; small number of spermatozoa.
11	2.25	3	10.00	No spermatozoa; great desquamation and degeneration of epithelium.
12	2.25	3	13.56	Only one-third to one-half the tubules contain spermatozoa, and few of these are normal.
13	2.25	6	15.84	Some edema; spermatogenesis much reduced.
14	2.25	6	13.88	Much atrophy and edema; spermatogenesis about 50 per cent of normal.
15	2.25	6	16.24	About three-fourths of the tubules nearly normal.

From Table II it will be seen that the least changes were found in the three rats (Nos. 4, 5, and 6) that received 0.5 cc. of alcohol for 3 months, while much more marked changes occurred in the three animals that received but 0.25 cc. of alcohol. Also, three of the rats that received the relatively enormous dosage of 2.25 cc. per day for

6 months, which would be equivalent to a man's taking over 2 quarts of whisky daily for a large part of his life, showed less change in the testicles than some of the rats that received somewhat less alcohol.

The changes produced by alcohol seem to take place in definite order. At first the spermatocytes seem to be normal in number and appearance, but there is soon an increase in the number of spermatids in the tubules with a decrease in the number of spermatozoa (see Fig. 1, showing a normal testicle, and Figs. 2 and 3, showing the testicles of rats which received 2 cc. and 2.5 cc. respectively). At the same time, or earlier, there is observed a greater diminution in the number of complete spermatozoa with tails than in the number of sperm heads. Not all the tubules in the testicles show the same degree of change, except in the most advanced cases (Fig. 4). In the more moderately affected testicles one finds some tubules nearly or quite normal, while others show merely a few active spermatocytes with the lumen packed with spermatids without spermatozoa or even spermatozoa heads (Fig. 5). Apparently the first effect of the alcohol is to render the formation of spermatozoa incomplete, so that the heads are formed without normal tails. In accordance with this, in one of these testicles we usually find the number of spermatozoa in the tubules of the epididymis much less than normal, and less in proportion than the number of spermatozoa seen in the seminiferous tubules, suggesting that the latter are too imperfect to migrate to the epididymis. The next effect of the alcohol seems to be to prevent the transformation of the spermatids into spermatozoa, whereby the tubules become filled with accumulated spermatids, with but a few spermatozoa or none at all. These spermatids then undergo a process of degeneration, so that they lose their nuclear stain and become granular. In the most advanced stages the tubules contain but the marginal cells, with few or no spermatocytes or spermatids (Fig. 6). Occasionally in the lumen of tubules showing advanced degeneration are found large cells with many nuclei or chromatin masses.

The degree of atrophy does not exactly parallel the decrease in functional activity, but usually the diameter of the tubules corresponds somewhat with the loss of function. When the tubules are atrophied there is commonly some compensatory accumulation of

serous fluid in the interlobular spaces, an edema *ex vacuo* (Fig. 4). In no instance have inflammatory changes been seen, and no marked fibrosis, although in some instances there has been an apparent slight increase in the thickness of the basement membrane of the tubules. We have noted no definite multiplication or other changes in the interstitial cells of Leydig, although when the tubules shrink apart these cells become more evident. No arterial changes were observed.

The epididymis generally reflects, in the number of spermatozoa it contains, the degree of functional impairment of the testicle (Figs. 7 and 8). In two of the rats there was also noteworthy desquamation of the epithelial lining of the ducts. Other changes were not observed in the epididymis.

Although the ovaries of the alcoholized females, and of the offspring of alcoholized parents, were examined in considerable numbers, it is not possible to make any positive statement as to the effect of alcohol on this organ. The changes of ovulation, pregnancy, and corpus luteum formation produce such great structural alterations in the ovary that we were unable to determine satisfactorily what changes were caused by the alcohol. There were two distinctly atrophic ovaries found in females that had had alcohol, and in several alcoholic females the ovaries were poor in ova in the sections examined.

Without study of serial sections of every ovary no conclusions of value could be reached from the material, and we were unable to undertake this task.

SUMMARY.

Administration of alcohol in the food of male white rats for 2 or more months, in daily quantities of 0.25 to 2.25 cc., results almost constantly in the appearance of marked degenerative alterations in the testicles. These changes affect the steps of spermatogenesis in inverse order to their occurrence, so that for some time before sterility and complete aspermia result, the animal is producing spermatozoa with all possible degrees of abnormality and deficiency. The possible relation of this abnormal spermatogenesis to the production of defective offspring is obvious. Individual rats show marked differences in the degree of change produced by equal amounts of alcohol. The

fibrous, interstitial, and vascular elements of the testicle are not affected, except for intertubular edema compensating for tubular atrophy. These experimental observations harmonize with the necropsy findings in human alcoholics. No other tissue was found to be noticeably affected by the alcohol; especially to be remarked is the absence of cirrhosis or fatty infiltration in the liver.

EXPLANATION OF PLATES.

PLATE 57.

FIG. 1. Normal testicle of a rat. $\times 58$.

FIG. 2. Testicle of a rat which had received 2 cc. of alcohol daily for 6 months. Marked loss of germinative epithelium and absence of spermatogenesis are shown, without much decrease in size. Many tubules in this testicle also show spermatogenesis. $\times 58$.

PLATE 58.

FIG. 3. Testicle of a rat which had received 2.25 cc. of alcohol daily for 3 months. Marked atrophy of the cellular content, decrease in size of the tubules as a whole, and complete absence of spermatogenesis are shown. $\times 58$.

See higher power of the same in Fig. 6.

FIG. 4. Testicle of a rat which had received 0.5 cc. of alcohol daily for 10 months. Marked decrease in size of the tubules with intertubular edema. $\times 58$.

PLATE 59.

FIG. 5. Tubule of a rat which had received 0.25 cc. of alcohol daily, showing absence of spermatozoa and accumulation of spermatids. This is one of the early stages of the degeneration of the testicular tubules. $\times 309$.

FIG. 6. Higher power of Fig. 3. Later stage of degeneration. The tubules contain no spermatozoa or spermatids, and almost no spermatocytes. $\times 309$.

PLATE 60.

FIG. 7. Normal epididymis of a rat. Tubules filled with spermatozoa. $\times 58$.

FIG. 8. Epididymis of a rat which had received 2 cc. of alcohol for 6 months, showing great atrophy and no normal spermatozoa. $\times 58$.

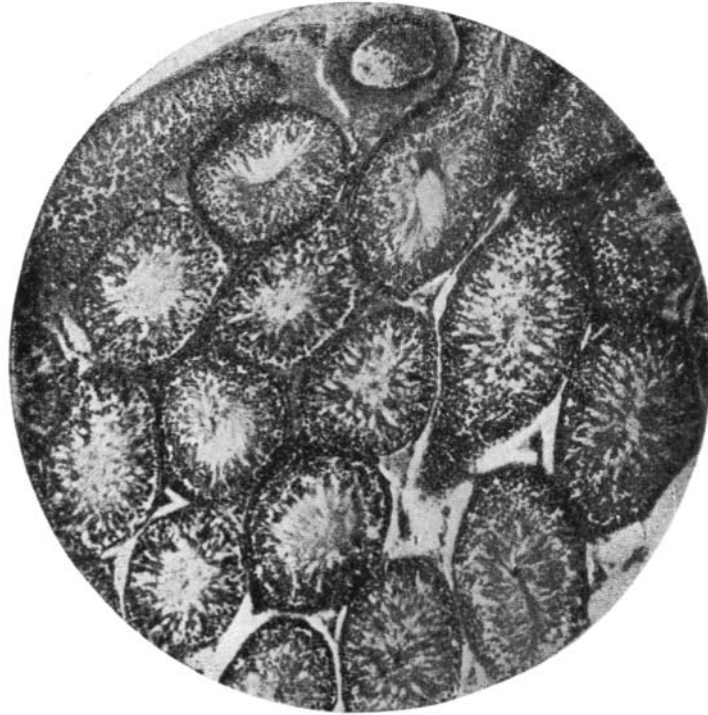

FIG. 1.

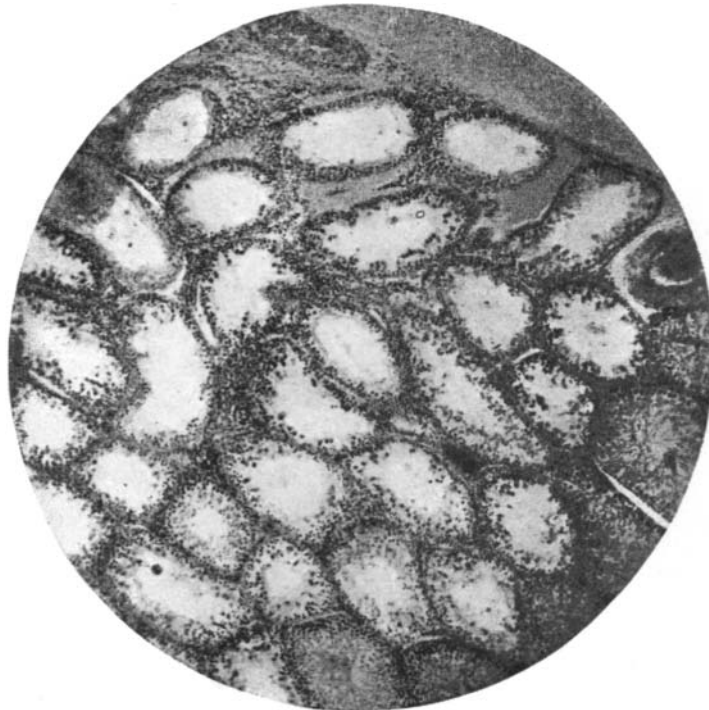

FIG. 2.

(Arlitt and Wells: **Effect of alcohol on reproductive tissues.**)




FIG. 3.

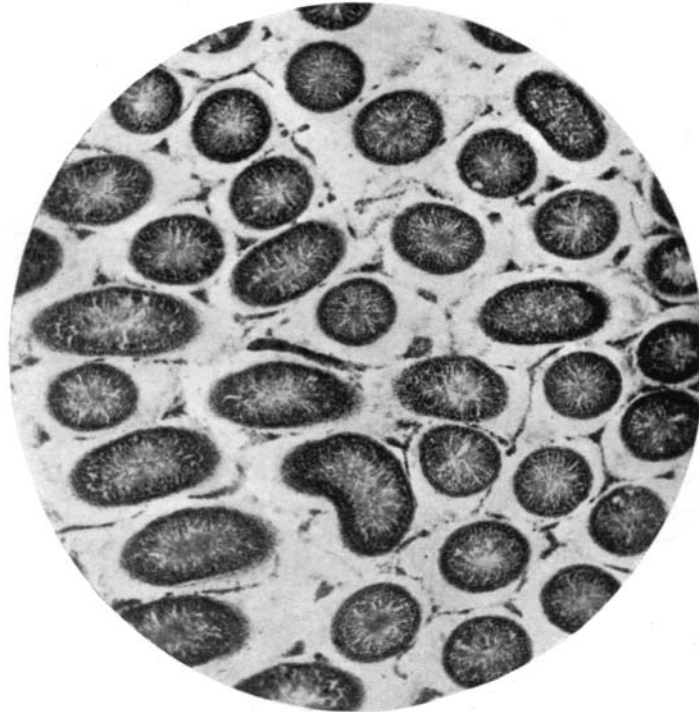


FIG. 4.

(Arlitt and Wells: Effect of alcohol on reproductive tissues.)

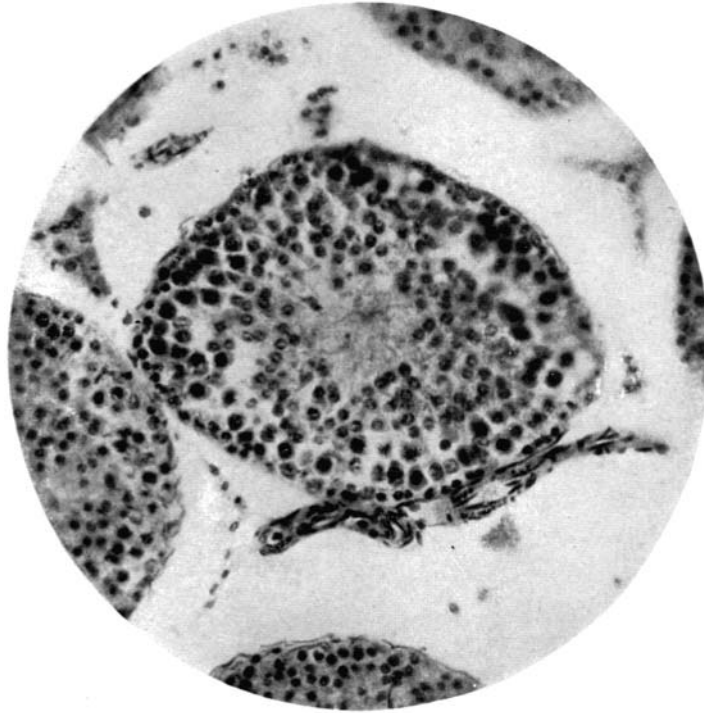


FIG. 5.

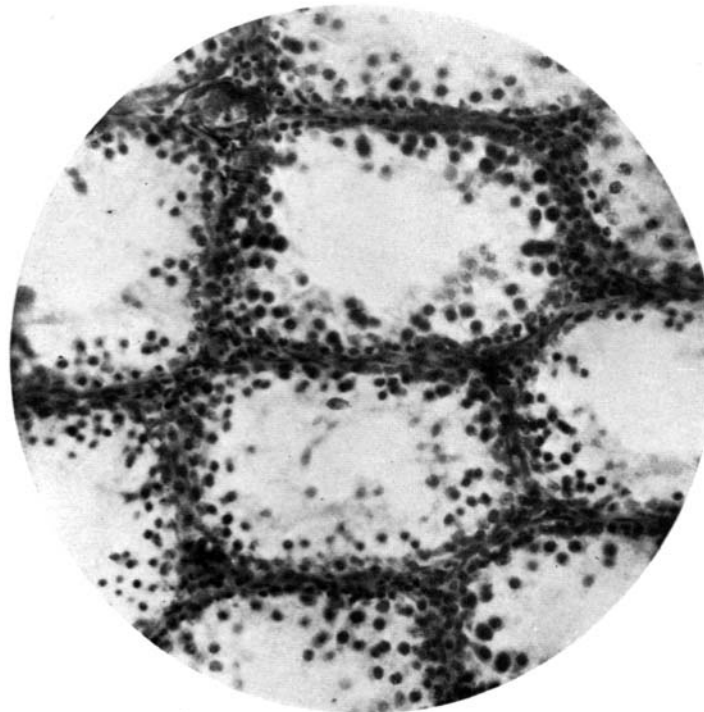


FIG. 6.

(Arlitt and Wells: Effect of alcohol on reproductive tissues.)

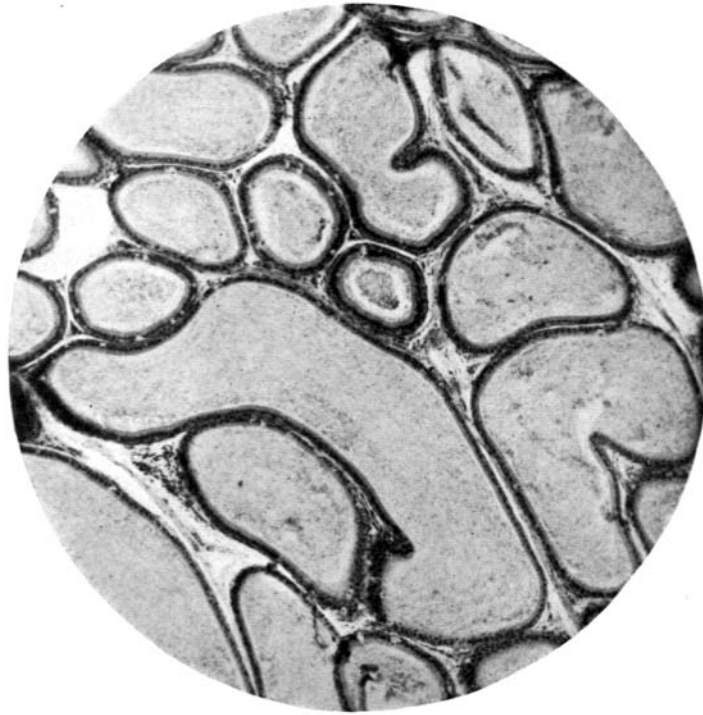


FIG. 7.

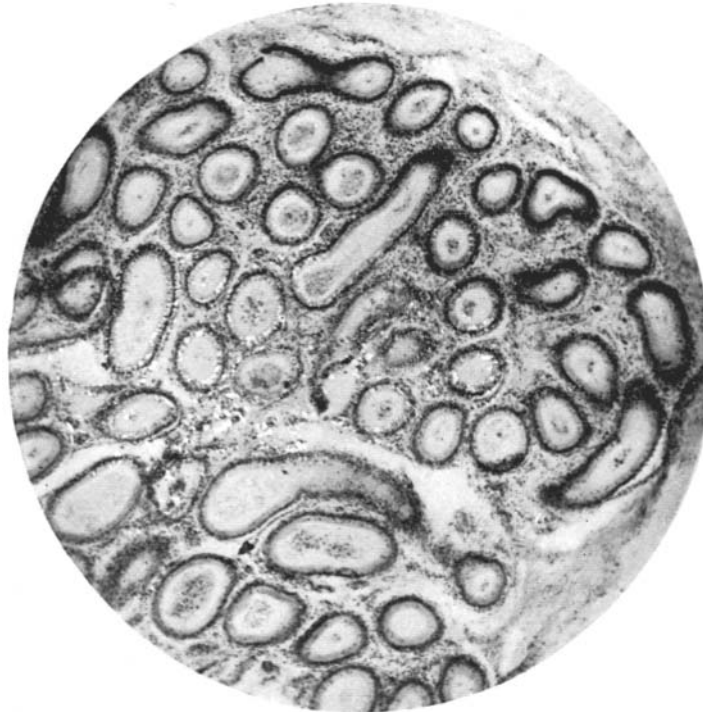

FIG. 8.

(Arlitt and Wells: Effect of alcohol on reproductive tissues.)