

ON CERTAIN SPONTANEOUS CHICKEN TUMORS AS MANIFESTATIONS OF A SINGLE DISEASE.

II. SIMPLE SPINDLE-CELLED SARCOMATA.*

By LINDA B. LANGE, M.D.

(From the Laboratories of The Rockefeller Institute for Medical Research.)

PLATES 72 TO 74.

Among the spontaneous chicken tumors recently brought to this laboratory there have been two spindle-celled sarcomata that have yielded, on transplantation, neoplasms similar respectively to two strains already under propagation. The resemblance of the growths derived from Chicken Tumor 38 to those derived from Chicken Tumor 18 is taken up in the preceding article.¹ They are spindle-celled sarcomata of protean character, often rifted with blood sinuses in a characteristic manner and showing a tendency to metastasize to the voluntary muscles. The subject of the present paper is Chicken Tumor 43, a simple spindle-celled sarcoma, apparently identical with Chicken Tumor 1.

The spontaneous tumor No. 38 differed considerably from the spontaneous tumor No. 18, and only after the growths had been observed in many hosts was their close similarity realized. Tumor 43, on the other hand, in its original form strikingly suggested Tumor 1, and the transplantation growths are practically identical with those of the latter. Both are produced by a filterable agent.

GROSS CHARACTERISTICS.

The original Chicken Tumor 43 occurred in a Plymouth Rock hen as a large nodular mass in the substance of the pectoral muscle, loosely attached to the lower end of the sternal keel, but not in-

* Received for publication, April 20, 1914.

¹ Rous, P., *Jour. Exper. Med.*, 1914, xix, 570.

volving the skin. The mass was fairly well defined, but devoid of a capsule. On incision the tumor tissue was, for the greater part, smooth, greyish pink, and firm, traversed by a few large blood sinuses, and well nourished throughout.

Pieces of the fresh tissue were inoculated into the pectoral muscles of two Plymouth Rock fowls by means of small trocars, the method employed also in subsequent transfers. The tumor grew in one of the two fowls. The rate of growth was slow at first, but on transplantation the malignancy increased rapidly, and in the fourth tumor generation the number of takes reached 100 per cent. The rate of growth as measured by the longest diameter was three times as rapid in the eighth as in the first generation. As contrasted with the firm almost gristly tissue of the earlier growths the more malignant tumors of later generations have been translucent and friable, and wet with a mucinous fluid. Hemorrhage into the tumors is frequent. In resistant fowls, on the other hand, the growth is firm, dense, nodular, and may undergo liquefaction resulting in cysts containing a clear mucinous fluid. With the progressive enlargement of the tumors the host emaciates, becomes cyanotic, and finally dies in coma.

Metastases were found in the original fowl in the heart and lungs, but not again until the fourth transplantation generation when they were also situated in the heart and lungs. Metastases have since been fairly frequent. They usually occur in the heart, lungs, and liver, less often in the spleen and kidney (figures 1 and 2). Implantation tumors on the heart and liver from a tumor growing through the body wall have been observed once.

MICROSCOPIC FINDINGS.

The tissue of the original growth is composed for the most part of slender spindle cells of somewhat irregular size, with pale, oval, vesicular nuclei often containing elongated or double nucleoli. Mitotic figures are fairly frequent. Scattered through the tissue are a few giant cells (figure 3). In some areas the cells are plumper and irregularly oval. The tissue structure varies, being very compact in some places and loosely meshed in others.

This picture has been fairly constant. Among the transplantation growths giant cells have been infrequent and the tumors have presented the general characters of a simple, spindle-celled sarcoma. In hosts relatively resistant, as shown by the behavior of the tumor, accumulations of small round cells are found, especially at the edge of the neoplastic tissue. The vigorously growing tumors are composed of spindle cells fairly uniform in size, shape, and arrangement. At the edge of the tumors there is practically no cellular reaction. When very malignant the tumor invades the muscle, not only by growing between the muscle bundles and fibers, but by penetrating the sarcolemma and replacing the muscle substance directly (figure 4). The metastases are histologically identical with the primary tumors.

ETIOLOGY.

Bacteriological cultures from the tumor tissue on the ordinary media have remained sterile under aerobic and anaerobic conditions. A causative agent separable from the tumor cells has, however, been demonstrated. The clear fluid obtained by filtering a thin suspension in Ringer solution of the finely ground tumor through Berkefeld filters holding back a test bacterium at the same filtration is capable of giving rise to tumors in normal fowls. These filtration tumors are identical with those from which the tissue for the emulsion was obtained. Tissue ground, frozen, and dried *in vacuo* over sulphuric acid, made up to the original bulk with distilled water, and injected into normal chickens, likewise causes tumors. Finally, the opalescent fluid obtained by centrifugalizing a thin suspension of the ground tissue in Ringer's solution may be mixed with glycerin and kept at 5° C. for many days without losing its ability to cause tumors. Mixtures containing 80 per cent. glycerin tested after ten days, and those containing 50 per cent. glycerin tested after twenty-one days were still active. Tumors arose from two to three weeks after inoculation of the material. As with the other chicken tumors, no case of cage infection has ever occurred.

RESEMBLANCE TO CHICKEN TUMOR I.

The spontaneous Chicken Tumor 43 and its transplanted growths closely resemble those of the strain known as Chicken Tumor I.² They are of similar gross and microscopic structure, run the same course, metastasize, in general, to the same organs and have the same general action on the host. In appearance and behavior they are, indeed, indistinguishable. An etiological agent distinct from the living cells is easily demonstrated for both tumors by filtration, desiccation, and glycerination. In the absence of definite experiments upon the point it cannot be affirmed that both tumors have the same cause, yet a closer parallelism between two strains of the same disease obtained by transfer from separate instances occurring in nature could hardly be looked for. In this connection it is of interest to note that Chicken Tumor 13 (figure 5), a growth arising in the connective tissue of the foot, has some resemblance in its histology to Nos. 1 and 43, though it may not with certainty be classed with them. The attempt to propagate No. 13 was unsuccessful and nothing can be said as to its etiology.

SUMMARY.

The forty-third spontaneous chicken tumor received at this laboratory strikingly resembles the first and has given rise on transplantation to an entirely similar series of neoplasms. Tumors of both strains are due to a filterable agent which remains active in the dried or glycerinated tissue.

EXPLANATION OF PLATES.³

PLATE 72.

FIG. 1. Characteristic tumor filling out the left breast of the fowl. The right breast shows the emaciated state of the fowl. Metastases can be seen in the heart, lungs, and liver, as indicated by the arrows. This tumor arose from glycerinated tissue.

FIG. 2. Metastasis in the heart from a tumor of the eighth transplantation generation. There is a complete absence of a cellular reaction about the growth.

PLATE 73.

FIG. 3. Section of the original growth showing subcutaneous spindle-celled neoplasm with scattered giant cells.

FIG. 4. Tumor of the sixth transplantation generation invading striated muscle. The muscle fibers are directly replaced by tumor cells.

PLATE 74.

FIG. 5. Section of Chicken Tumor 13.

² Rous, P., *Jour. Exper. Med.*, 1910, xii, 696; 1911, xiii, 397.

³ The microscopic sections were stained with methylene blue and eosin.

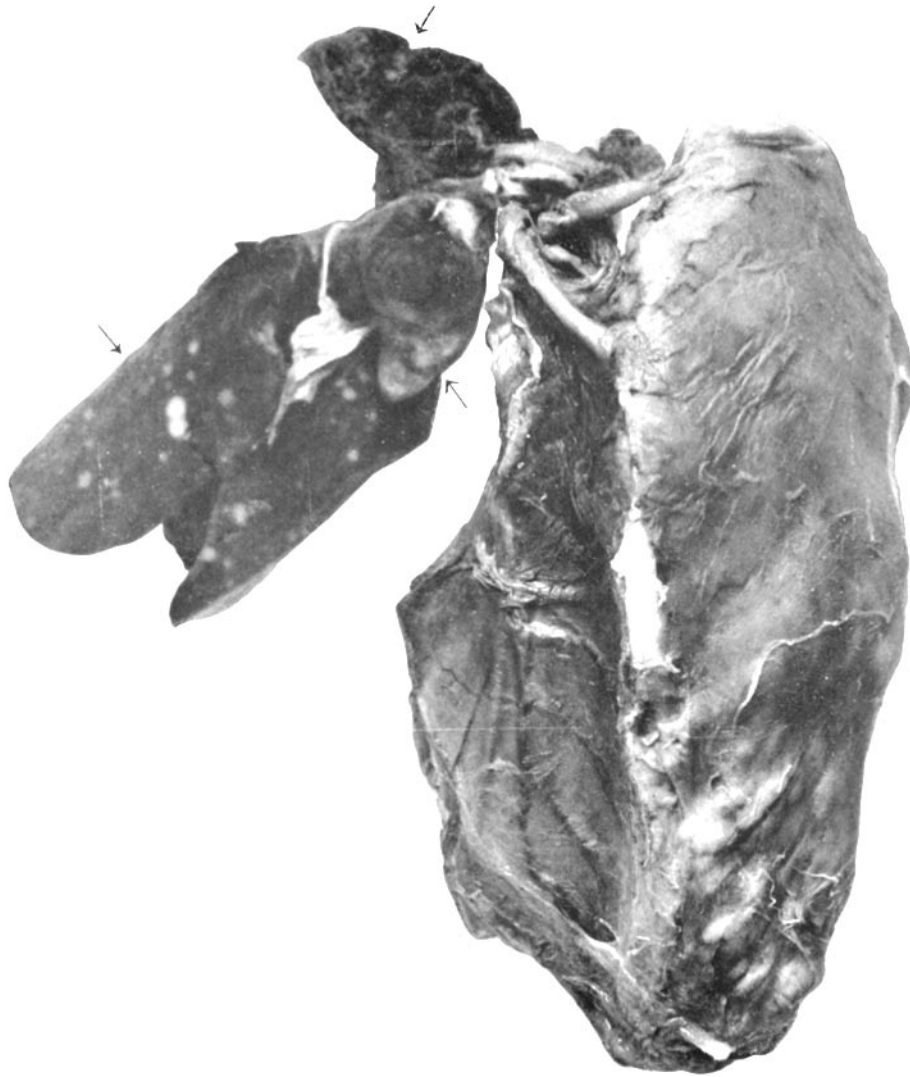

FIG. 1.

(Lange: Spontaneous Chicken Tumors.)

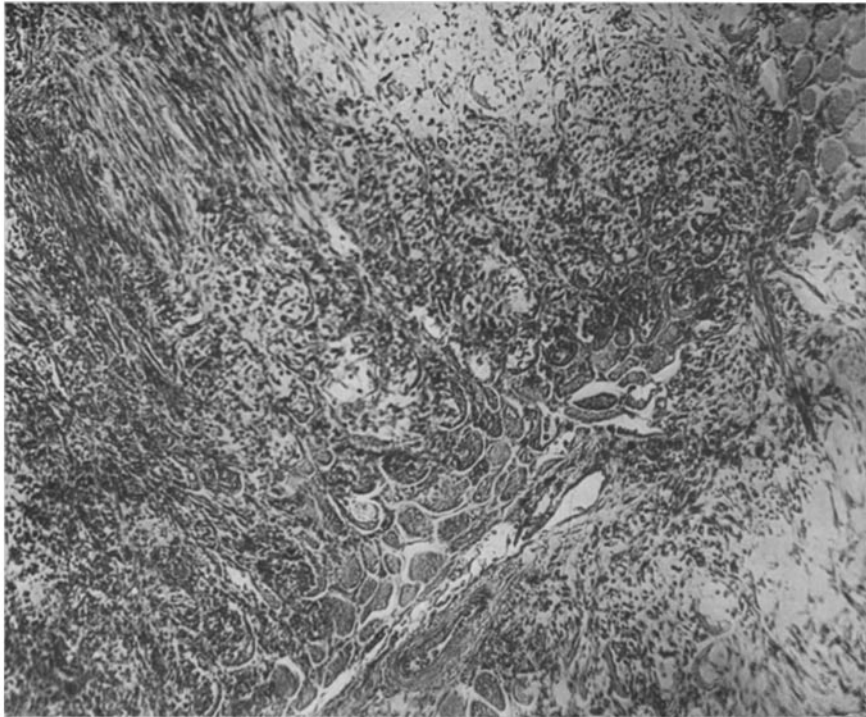


FIG. 2.

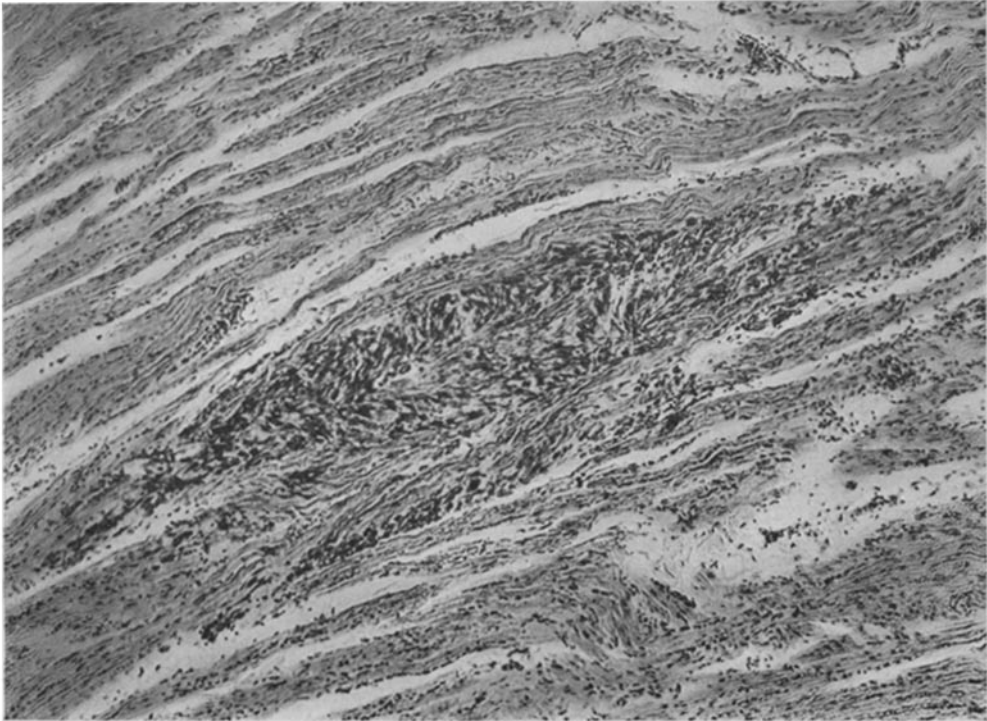

FIG. 3.

(Lange: Spontaneous Chicken Tumors.)

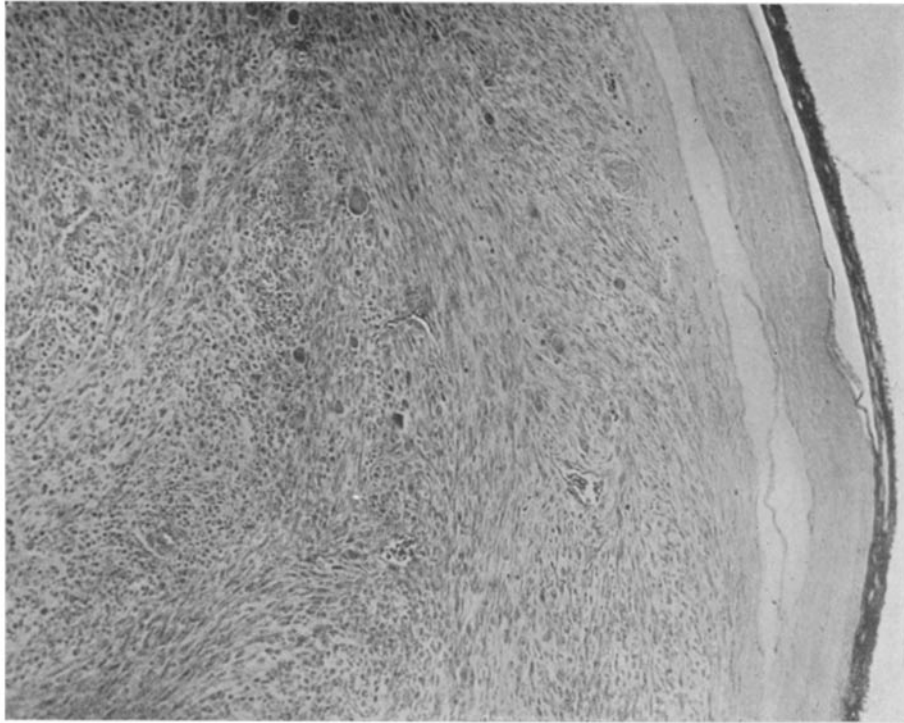


FIG. 4.

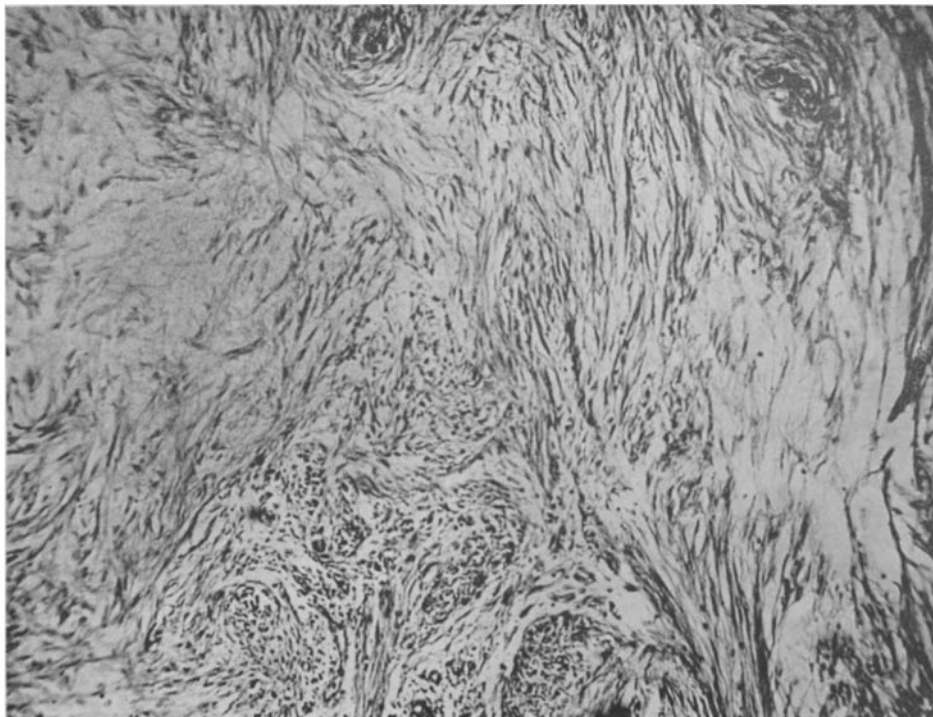


FIG. 5.

(Lange: Spontaneous Chicken Tumors.)