

# A HISTOLOGICAL AND CHEMICAL STUDY OF THE FATTY MATTER OF NORMAL AND CRYPTORCHID TESTES.\*

BY FREDERIC M. HANES AND JACOB ROSENBLOOM.

*(From the Departments of Pathology and Biological Chemistry, Columbia University, College of Physicians and Surgeons, New York.)*

## PLATE XXXVII.

### I. HISTOLOGICAL OBSERVATIONS.

In the course of an investigation of the interstitial cells of Leydig in the testes of various mammalia, our attention was early directed to the large amount of microchemically demonstrable fat in the Sertoli and spermatogenic cells of the seminal tubules. This observation is by no means new. Kölliker (1), in 1854, described similar findings, and all subsequent writers upon the subject have emphasized the point (2). From a study, however, of a large number of cryptorchid testes from the pig, we have accumulated additional data which bear so directly upon the problem of the metabolic rôle played by the fats of the seminal tubules of the testis, that the subject seems worthy of detailed analysis.

Within the seminal tubules there are two very distinct histological elements, the sperm-forming cells, and the Sertoli, or sperm-nourishing cells. These latter cells line the inner surface of the seminal tubules in a syncytium-like manner, and the former lie partially embedded in their cytoplasm. At the beginning of a spermatogenic generation large droplets of fat are constantly present in the basal portions of the Sertoli cells, so that a section of such a tubule stained with Sudan III, or osmic acid, shows a peripheral ring of fat droplets (plate XXXVII, Fig. 1). These large droplets respond to all the tests for neutral fats. As spermatogenesis proceeds, however, these large droplets break into smaller ones, and, leaving the basal portions of the Sertoli cells, they pass into the central protoplasmic

\* Received for publication, January 5, 1911.

prolongations of these cells. The spermatids, having now in the course of spermatogenesis formed a true protoplasmic union with the Sertoli cells, the small droplets of fat are seen to have partially passed into the spermatids (von Ebner). In a section of a seminal tubule at this stage of spermatogenesis (stained by osmic acid after having been previously treated with potassium dichromate—Müller's fluid, twenty-four to forty-eight hours), it is found that the small central droplets of fat, although continuing to stain with Sudan III, will no longer reduce osmic acid and stain black. The large droplets of fat in the same and neighboring tubules still stain intensely black with osmic acid. Obviously then, the fat of the Sertoli cells, as it passes toward the lumen of the seminal tubules, undergoes some chemical change. The chemical treatment just described (chromatization followed by osmic acid) is essentially an application of Marchi's stain to the fats of the testis, and Marchi's stain, as is well known, is employed to differentiate fats from the peculiar lipid complex known as myelin. We have concluded, therefore, that the change in the neutral fats of the Sertoli cells represents a transformation to a lipoid. This conclusion is supported by the work of Regaud (3) who, using Weigert's method for staining myelin, has also demonstrated lipoids in the Sertoli and spermatogenic cells.

A discussion of some of the physical and chemical properties of the myelin bodies will be found in a note at the end of this paper, and will not be entered upon at this time. Regaud (3) has sought to establish a relation between the fats of the Sertoli cells and their cell granules or mitochondria (Benda (4)). To pursue this question would involve a discussion of the very difficult and little understood problem of the structure and functions of cell granules, and it must therefore be abandoned for the present. We may safely conclude with von Ebner, however, that histologically fat seems to be an important constituent of the nourishment furnished by the Sertoli cells to the rapidly maturing sperm-cells.

Physiological evidence of the important rôle played by the fats in spermatogenesis has been wanting. Such evidence is obtainable, we think, from a study of the cryptorchid testes of the pig. In

a section of a cryptorchid testis (plate XXXVII, Fig. 2), one sees, in addition to an enormous increase of the Leydig cells, that the seminal tubules are much smaller than normally, and are lined only by a single layer of Sertoli cells. *The entire series of spermatogenic cells has completely disappeared*, a finding which is in harmony with the well-known sterility of double cryptorchid animals (Ancel and Bouin (5)). A section of such a cryptorchid testis, stained for fat, shows a truly remarkable quantity of large fat droplets in the Sertoli cells (Fig. 2). Indeed, the protoplasm of these cells is often so nearly replaced by fat that they resemble fat cells. This fat reacts chemically in every way like the neutral fats found elsewhere in the body.

The histological evidence of the presence of an excessive amount of fat in the seminal tubules of cryptorchid testes is strikingly substantiated by chemical analysis. The results tabulated on page 359 show that the fat content of the cryptorchid testis is approximately double that of the normal organ. We have seen that fat is apparently actively employed by the Sertoli cell as a metabolic element in the course of its activity as a nourisher of the sperm-forming cells. But in the cryptorchid testis these latter cells are lacking. We have concluded, therefore, that the large accumulation of fat found in the Sertoli cells of cryptorchid testes represents the fat which in the normal testis is utilized in the course of spermatogenesis. The Sertoli cell is endowed with the function of accumulating the fats needed during the process of spermatogenesis, and even in the absence of the spermatogenic cells, which normally utilize this fat, the Sertoli cell continues to perform its function. The persistence of such specialized cell functions under the most abnormal conditions is among the best recognized of biological phenomena.

There was a time, not far past, when such accumulations of fat as those just described in the Sertoli cells of the cryptorchid testis, were simply labelled "fatty degeneration" and set aside. Under the influence of recent pathological and biochemical research upon normal and abnormal fat metabolism, Virchow's time-honored phrase has lost most of its charm. There exists to-day no acceptable evidence that protoplasm ever "degenerates" into fat (Rosenfeld

(6)). We are beginning to see more clearly that the presence of abnormal quantities of neutral fats in the body cells is an expression of metabolic derangement, and not necessarily of protoplasmic degeneration. The procuring of foodstuffs, as represented, for example, by the fats, and their subsequent utilization by the cell, represent, it would seem, separately specialized functions of the cell. Normally these functions are beautifully coördinated, so that intake and utilization balance, but this coördination may be disturbed, as seen, for example, after toxic injury to the cells of the liver, with the consequence that fat continues to accumulate in the cell but is no longer metabolized with normal rapidity. The end result of this derangement of cell functions is now termed "fatty infiltration," and the idea suggested by the term is well supported by the work of Rosenfeld and others. The abnormal situation of the cryptorchid testicle is accompanied, for some unknown reason, by a loss of the spermatogenic cells, which normally utilize in their growth the fats furnished by the Sertoli cells. Fat accumulates, therefore, in the Sertoli cells, and we may properly regard the process as that of fatty infiltration, and not fatty degeneration. The fat content of the testicle does not show variations, due to changes in the general condition of the body, exhibited by the stored-up neutral fats elsewhere. Extreme cachexia occasions no diminution in the testicular fat, nor does obesity cause an increase (Thaler (7), Cordes (8), Traina (9)).

The histological study of the fats of normal and cryptorchid testes revealed facts which led us to make a thorough chemical study of the subject. Our data in this connection are recorded below.

## II. CHEMICAL DATA.

*Desiccation of the Testes.*—The testes within three hours after their removal from the body were cleaned from the epididymis, weighed, and run through a hashing machine. 1,005 grams of normal pig testicles were used for this study and 610 grams of cryptorchid pig testicles. Three separate amounts of each kind of material, obtained on different days, were employed, thus allowing for unavoidable variations in the testes, due to slightly varying ages of the pigs. The hashed organs were spread on glass trays and dried in a stream of warm air, with repeated mixings of the tissue. At the end of twenty-four hours the desiccated material was ground in a mortar, passed through a grinding machine, and dried *in vacuo* over sulphuric acid until of constant weight. The dried tissue

was reground to a fine powder and samples then taken for the extraction of the fatty matters.

*Extraction of the Fatty Matter.*—The extractions were carried out in the ordinary form of Soxhlet extractor and each extraction continued until a fresh supply of solvent yielded no residue on evaporation. Four thorough extractions of each sample of material were made successively with the following solvents: ether, alcohol, ether. The residue was then subjected to peptic digestion, after which the material was again thoroughly extracted with ether (Dormeyer (10)).

*Chemical Analyses.*—In order to detect any variations in the character of the fatty material contained in the normal testes as compared with that from cryptorchid testes, the material from each extract was examined separately. The separation of the phosphorized fat (lecithans) was carried out according to the method described by Koch (11). The phosphorus oxidations were made by the Neumann method (12), and the phosphoric acid weighed as magnesium pyro-phosphate.

*Results.*—The following table exhibits the results obtained. The data show that:

1. The proportion of fatty material in the cryptorchid pig's testis which is soluble in alcohol and ether is approximately twice that in the normal organ.
2. The percentage of phosphorized fats (lecithans) in the cryptorchid testis is likewise nearly double that in the normal glands.
3. The fatty materials in the cryptorchid and in normal testes which are soluble in alcohol and ether are nearly identical in their iodine numbers and saponification values (table I).

TABLE I.

*Normal testes (1,005 grams); 84.36 per cent. water.*

No.	Weight of dry tissue in grams.	1st extract (in ether) grams.	2d extract (in alcohol) grams.	3d extract (in ether) grams.	(Dormeyer) 4th extract (in ether) grams.	Total fat in grams.	Percentage of fats in % dry tissue.	Percentage of fats in fresh tissue (average).
I	59.3545	7.2515	3.7450	0.0460	0.1620	11.2045	18.87	2.97
II	49.1740	5.6020	3.3510	0.0245	0.1995	9.1770	18.66	
III	48.9445	5.9600	3.3230	0.0010	0.2080	9.4920	19.38	

*Cryptorchid testes (610 grams); 80.37 per cent. water.*

IV	36.9345	7.6080	3.2435	0.0155	0.2180	11.0850	30.01	6.01
V	37.2665	8.1175	3.2040	0.0155	0.2860	11.6230	31.19	
VI	44.7222	9.8945	3.6175	0.0310	0.3775	13.9305	31.15	

## Normal testes.

No.	Percentage of lecithans in dry tissue.			Percentage of lecithans in fresh tissue (average).	Saponification value.*			Iodine number † (Hübl's method).		
	Ether soluble.	Alcohol soluble.	Ether and alcohol soluble (average).		Ether soluble.	Alcohol soluble.	Ether and alcohol soluble (average).	Ether soluble.	Alcohol soluble.	Ether and alcohol soluble (average).
I	34.18	30.26	32.22	0.988	205.5	156.9	181.2	103.8	51.8	77.8
II	27.40	28.42	27.91		206.0	157.3	181.6	104.0	54.2	79.1
III	30.86	30.58	30.72		205.1	157.8	181.4	107.3	53.7	80.5

## Cryptorchid testes.

IV	42.27	28.27	35.27	1.75	226.5	164.2	195.3	106.0	53.2	79.6
V	42.08	21.22	31.65		226.4	165.1	195.7	106.1	53.8	79.9
VI	34.01	38.06	36.03		225.8	163.6	194.7	106.4	53.6	80.0

## III. CONCLUSIONS.

1. About 19 per cent. of the dry weight of the normal pig testicle is fatty matter. Histologically this fat occurs largely in the cells of the seminal tubules, and especially in the Sertoli cells.

2. During spermatogenesis the fat of the Sertoli cell passes inward for the nutrition of the spermatids and spermatozoa. During this passage its character is altered from a neutral fat to a lipid.

3. About 30 per cent. of the dry weight of the cryptorchid pig testicle is fatty material. Histologically this fat lies within the seminal tubules, partially filling the Sertoli cells. The spermatogenic cells have completely disappeared.

4. We conclude that the presence of such an excessive amount of fat in the cryptorchid testicle is due to the absence of the spermatogenic cells which normally utilize during their development the fat furnished by the Sertoli cells.

\* The saponification value of a fat is the number of milligrams of potassium hydroxide that are neutralized by the fatty acids from one gram of the fat. It is a measure of the mean molecular weight of the fatty acids entering into the composition of a fat.

† The iodine value of a fat is the amount of halogen (computed as iodine) expressed in per cent. of the weight of fat that the unsaturated acid radicals it contains will take up. The saturated acids and their glycerides absorb no iodine and, therefore, the iodine value of a fat or a mixture of fatty acids is an index of the per cent. of saturated and unsaturated acids present. The acids with unsaturated linkages in more than one place absorb proportionally more iodine. The saponification and iodine values in the above table represent the mean of closely agreeing triplicate determinations.

## IV. A NOTE ON THE MICROCHEMISTRY OF FATTY SUBSTANCES.

Recent studies in the microchemistry of the fatty substances have materially increased our knowledge of old methods and added new ones for the more certain differentiation of the various forms in which fats and fat-like substances occur in the organism. In this note no attempt is made to enumerate the many substances which will stain fat (Eisenberg); only those more recent advances are briefly detailed which have placed the staining of fatty substances on a more certain chemical basis.

Osmic acid (osmium tetroxide,  $\text{OsO}_4$ ) was formerly employed as a stain for all tissue fats, but it is now generally agreed that osmic acid is only a stain for fatty compounds containing one or more unsaturated fatty acid radicals. The ordinary neutral fats of the body are mixtures of the triglycerides of palmitic, stearic, and oleic acids. Tristearin and tripalmitin are saturated compounds and do not blacken when treated with osmic acid. That is to say, they do not reduce, being already saturated, the soluble  $\text{OsO}_4$  to the insoluble black oxide  $\text{OsO}_2$ . Triolein on the contrary, with its three unsaturated oleic acid radicals, takes up oxygen with avidity from  $\text{OsO}_4$ , causing a deposition of the oxide,  $\text{OsO}_2$ .

Osmic acid is thus seen to be unreliable as a stain for all fats. Oleic acid, on the other hand, is seldom if ever absent from the body mixtures of neutral fats, so that osmic acid is not to be discarded, but rather carefully controlled by more reliable stains, such as Sudan III. The one advantage which until recently osmic acid has possessed over other methods is that it renders the fats insoluble in the usual fat solvents, and hence capable of being sectioned in paraffin. But this supposed advantage has been greatly overestimated. It is certainly true that small droplets of fat blackened by osmic acid may be dissolved completely by alcohol, while the morphology of larger drops is seriously altered. Nor are variations in the depth of staining tone of various fats after osmium treatment reliable criteria of their composition, as has been assumed by some observers. It must also be borne in mind that tissues treated with osmic acid and subsequently with alcohol, may become blackened in some places where no fat is present. Thorough washing tends to prevent this. It would seem necessary to reduce further the  $\text{OsO}_2$  by some such reducing agent as pyroligneous acid, as embodied in Benda's method for the demonstration of cell granules.

Sudan III and Scharlach R. are far more reliable fat stains than osmic acid. Until recently they have been applied for obvious reasons only to frozen sections, but results to be mentioned presently seem to widen greatly their usefulness by permitting their application to paraffin material. They color specifically the neutral fats, tinging slightly the surrounding tissues. Fats are not chemically altered by Sudan III or Scharlach R., and are stained owing to the fact that these dyes, in common with many others, are more soluble in fat than in alcohol. For the demonstration of neutral fats, Sudan III and Scharlach R. leave nothing to be desired, but they do not stain differentially other fatty substances, such as fatty acid, soaps, and lipoids.

The important place which the lipid substances have been shown to occupy, both in the normal and pathological metabolism of the cell, have rendered impera-

tive the development of new methods for their morphological study. Histologists have long used Weigert's method for staining a mixture of lipid substances, myelin, in the axis cylinder sheaths of medullated nerves. A brief discussion of this stain in the light of the recent very important work of Smith, Mair, and Thorpe (13) will render clearer some of the problems connected with the specific staining of various lipoids. The term myelin, introduced by Virchow, is not used to designate a definite chemical compound of constant composition, but rather a physical complex of various lipoids which is characterized by certain peculiar properties. Virchow (14) defined the properties of the myelin substances which he had found widely distributed throughout the body as follows:

1. They swell in water, exhibiting the most irregular, bizarre forms, changing their shape while under observation (myelin figures).
2. Easily soluble in hot alcohol; precipitated only in part by cooling.
3. Soluble in ether, chloroform, and turpentine.
4. Affected very slightly by weak acids and alkalis; shrink and lose their peculiar property of myelin figure formation in strong alkalis. Mettenheimer, in 1858, first noted that the myelin bodies when examined under crossed Nicol prisms are anisotropic. Such anisotropic myelin bodies are fluid crystals (Adami (15)). They may be brilliantly demonstrated under the microscope by adding a drop of strong ammonium hydroxid solution to a drop of oleic acid. The following substances are capable of yielding anisotropic myelin bodies (Aschoff (16)):  
(1) the phosphatids; (2) soaps of oleic acid; (3) esters of cholesterol; (4) solutions of cholesterol in phosphatids, fatty acids, and fats; (5) solutions of cholesterol esters in fats.

Smith, Mair, and Thorpe have carefully investigated the chemical reactions underlying Weigert's method for staining the myelin sheath of nerves, and other myelin bodies. As is well known, Weigert's method consists in thoroughly chromatizing material to be stained by prolonged exposure to potassium dichromate and then deeply staining the sections with hematoxylin. Upon properly differentiating, a lake of hematoxylin is found deposited in the myelin substance of the nerves. Smith and his co-workers have demonstrated that any fatty body containing an unsaturated grouping in its molecular constitution will stain by Weigert's method, whereas saturated fatty compounds, such as tripalmitin, do not stain thus. They have further shown that when unsaturated compounds, such as triolein, are treated with potassium dichromate, one molecule of  $\text{CrO}_2$  attaches itself to each unsaturated acid residue converting it into an insoluble hydroxyacid and, upon subsequent treatment with hematoxylin, an insoluble lake is formed in the fat. Now the ordinary neutral fats in the body are mixtures containing triolein, tristearin, and tripalmitin, and since triolein contains unsaturated acid radicals, the neutral fats of the body should stain by Weigert's method. Such indeed is the case. The neutral fat mixtures differ, however, from the myelin of the nerve sheaths in requiring much more time for the oxidative action of potassium dichromate, like quantities of the two substances being used. So the reaction, as Smith points out, is not altogether chemical. The physical complex, myelin, oxidizes much more rapidly than the same volume of neutral fat mixture. Smith, Mair, and Thorpe thereupon investigated the staining properties of artificially prepared myelins, such as mixtures of



cholesterol and lauric acid. Neither pure cholesterol nor lauric acid stains by Weigert's method, but when mixed they yield myelin figures and stain readily by Weigert's procedure. In other words, two chemical substances which alone are non-oxidizable with potassium dichromate, are easily oxidized when united in a molecular arrangement which yields myelin figures.

Myelin bodies occur under both physiological and pathological conditions in various cells of the body (Aschoff (16)). Applying the results of the work of Smith, Mair, and Thorpe to the body cells in general, Dietrich (17) has shown that myelin substances can be stained differentially from neutral fats.

Neutral fats treated with potassium dichromate for a sufficient length of time are rendered insoluble, and may be sectioned in paraffin and subsequently stained with Sudan III or Scharlach R. In conclusion it is interesting to note that one simple chemical change is essentially the basis of the Weigert, Marchi, and osmic acid methods of staining fatty substances. This change consists in an oxidation of the unsaturated fatty acid radicals present in the molecules of certain fats and lipoids.

## BIBLIOGRAPHY.

1. Kölliker, *Mikroskopische Anatomie oder Gewebelehre des Menschen*, Leipzig, 1854, ii.
2. von Ebner, *Kölliker's Handbuch der Gewebelehre*, Leipzig, 1902, iii, pt. 2, p. 451.
3. Regaud, Études sur la structure des tubes spermatogenese chez les mammifères, *Arch. d' anat. micr.*, 1910, xi, 291.
4. Benda, Die Mitochondria, *Ergebn. d. Anat. und Entwickl.*, 1902, xii, 743.
5. Bouin et Ancel, Recherches sur la signification physiologique de la glande interstitielle du testicule des mammifères, *Jour. de physiol. et de path. gén.*, 1904, vi, 1012.
6. Rosenfeld, Fettbildung, *Ergebn. d. Physiol.*, 1902, i, 651; 1903, ii, 50.
7. Thaler, Über das Vorkommen von Fett und Kristallen im menschlichen Testikel unter normalen und pathologischen Verhältnissen, *Beitr. z. path. Anat.*, 1904, xxxvi, 528.
8. Cordes, Untersuchungen über den Einfluss acuter und chronischer Allgemeinerkrankungen auf der Testikel, specielle auf die Spermatogenese, sowie Beobachtungen über das Auftreten von Fett in den Hoden, *Virchow's Arch. f. path. Anat.*, 1898, cli, 402.
9. Traina, Ueber das Verhalten des Fettes und der Zellgranula bei chronischem Marasmus und acute Hungerzuständen, *Beitr. z. path. Anat.*, 1904, xxxv, 1.
10. Dormeyer, Die quantitative Bestimmung von Fetten, Seifen und Fettsäuren in thierischen Organen, *Arch. f. d. ges. Physiol.*, 1897, lxxv, 90.
11. Koch, Methods for the Quantitative Analysis of Animal Tissues, *Jour. Am. Chem. Soc.*, 1909, xxxi, 1341.
12. Neumann, Einfache Veraschungs Methode, *Ztschr. f. physiol. Chem.*, 1902, xxxvii, 115; 1904, xliii, 37.
13. Smith, Mair, and Thorpe, An Investigation of the Principles Underlying Weigert's Method of Staining Medullated Nerve, with a Note on the Staining of Fats by Potassium Dichromate and Haematoxylin, *Jour. Path. and Bact.*, 1909, xiii, 14

14. Virchow, *Virchows Arch. f. path. Anat.*, 1854, vi, 562.
15. Adami, Harvey Lectures, Philadelphia, 1908, series ii, p. 117.
16. Aschoff, Zur Morphologie der lipoiden Substanzen, *Beitr. z. path. Anat.*, 1910, xlvii, 1.
17. Dietrich, Eine Differentialfärbung der fettartigen Substanzen, *Centralbl. f. allg. Path.*, 1910, xxi, 465.

## EXPLANATION OF PLATE XXXVII.

FIGS. 1 and 2 are microphotographs taken under exactly the same magnification.

FIG. 1. Section of normal pig testis in active spermatogenesis. Altmann's fixation (osmic acid and potassium dichromate); stained with Bensley's neutral gentian. The droplets of neutral fat lying in the Sertoli cells form an outline of the seminal tubule. Numerous small droplets of fatty material are seen toward the lumen.

FIG. 2. Section of cryptorchid pig testis, stained with Sudan III and hematoxylin. The tubules are much smaller than in the normal testicle, and are lined only by a layer of Sertoli cells, which contain a large number of neutral fat droplets. No sperm-forming cells are present. The Leydig cells are seen, on comparison with Fig. 1, to be greatly increased in number.

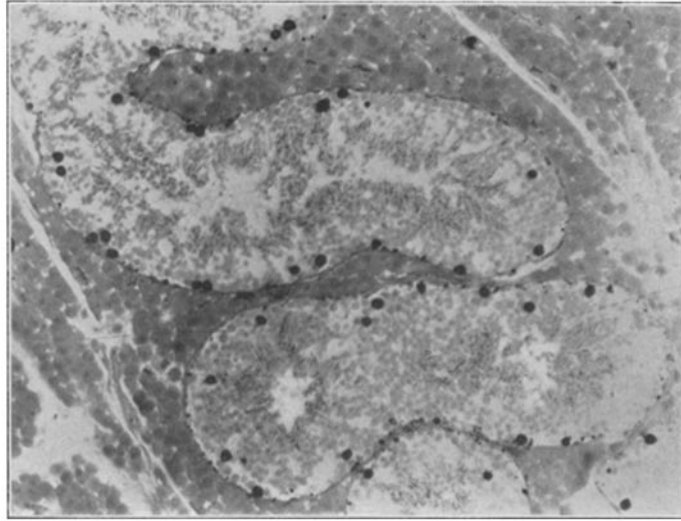


FIG. 1.

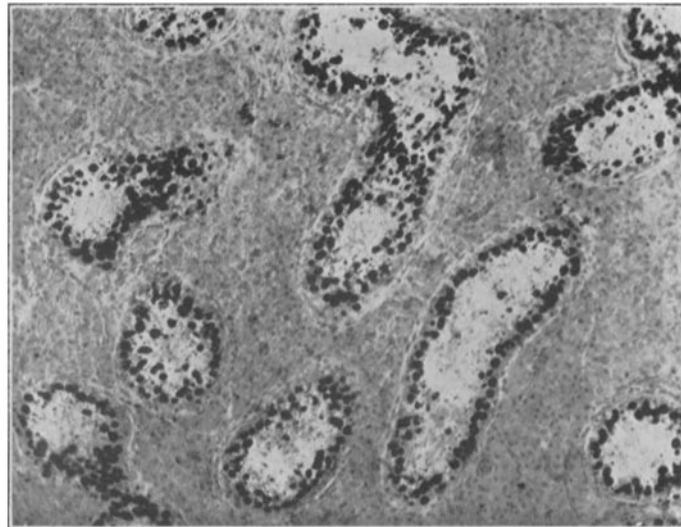


FIG. 2