

AUTOIMMUNE DISEASE IN NZB/BL MICE

III. INDUCTION OF MEMBRANOUS GLOMERULONEPHRITIS IN YOUNG MICE

BY THE TRANSPLANTATION OF SPLEEN CELLS FROM OLD MICE

BY ROBERT C. MELLORS, M.D.

(From The Hospital for Special Surgery, in Affiliation with The New York Hospital-Cornell University Medical College, and the Department of Pathology, Cornell University Medical College, New York)

PLATES 100 TO 102

(Received for publication 18 February 1966)

Autoimmune hemolytic anemia is of natural, and virtually universal, occurrence in NZB/Bl mice (1-3). Renal disease with clinical and pathological similarity to chronic membranous glomerulonephritis and related diseases (4-6) as described in man is also of frequent occurrence and is probably the commonest cause of death of NZB/Bl mice. The presence of immunoglobulins fixed to, and showing in vitro specificity for, the altered glomeruli suggests that membranous glomerulonephritis in NZB/Bl mice is induced by immunological, and autoimmune, mechanisms (5). The present study describes successful attempts to induce membranous glomerulonephritis in young NZB/Bl mice by the transplantation of spleen cells obtained from old NZB/Bl mice with severe glomerular disease.

Methods and Materials

The hematological, biochemical, serological, and immunopathological methods have been described elsewhere (5). Our colony of NZB/Bl mice, derived from breeding stock kindly provided by Dr. Marianne Bielschowsky, is now in the sixty-fourth generation of brother-sister matings and comprises more than 1400 mice. Several thousand laboratory examinations and more than one hundred autopsies of NZB/Bl mice from 1 day to 16 months of age, including healthy young mice, Table I, served as control observations for the transplantation studies described herewith. These latter were representative of several transplantation experiments carried out during the last year. The plan has been first to study the natural course of spontaneous renal disease, and then to attempt to induce a disease of similar kind in young NZB/Bl mice, well in advance of its natural occurrence, by the transplantation of spleen cells from adult NZB/Bl mice with severe nephropathy. The adult spleen tissue was minced into 1 mm cubes in sterile balanced salt solution and injected through a large gauge needle into the subcutaneous tissue of the ventrolateral abdominothoracic region. Approximately $\frac{1}{8}$ of a donor spleen was injected into each recipient: 0.14 g into each recipient of donor 1 spleen and 0.03 g into each recipient of donor 2 spleen. The number of transferred cells was estimated to be several (30 to 100) million. The recipients were usually 4, rarely 8, wk of age at the time of transplantation and were autopsied at an age of 8 to 13 wk, Table IV.

RESULTS

Spontaneous Renal Disease.—

Clinical pathology: Significant (++ to ++++) proteinuria occurred rarely (once in 108 tests) during the first 7 months and not prior to 5 months of age. At 11 to 13 months, 57% (88/154) of NZB/Bl females had significant proteinuria and a rare (1/154) female had massive (+++++) proteinuria. At 11 to 13 months, 22% (28/126) of NZB/Bl males had significant proteinuria. The urinary proteins excreted in membranous glomerulonephritis were mainly serum albumin but, with progression of the renal disease, included also serum α -, β -, and γ -globulins as shown by immunoelectrophoretic analysis. Qualita-

TABLE I
*Laboratory Examinations of Healthy Young NZB/Bl Mice**

Determination	Average	Average \pm 2 sd (or range)
Hematocrit, %	49	44–54
Reticulocytes, %	3	0–7
Platelets/mm ³	1,500,000	300,000–4,200,000
Wbc/mm ³	5200	3200–7800
Serum urea nitrogen, mg/100 ml	24	16–32
Serum cholesterol, mg/100 ml	150	82–218
Serum proteins, g/100 ml		
Total	5.7	5.1–6.3
Albumin	3.1	2.1–4.1
α_1	0.5	0.2–0.7
α_2	0.8	0.3–1.2
β	0.7	0.5–1.0
γ	0.6	0.2–0.8

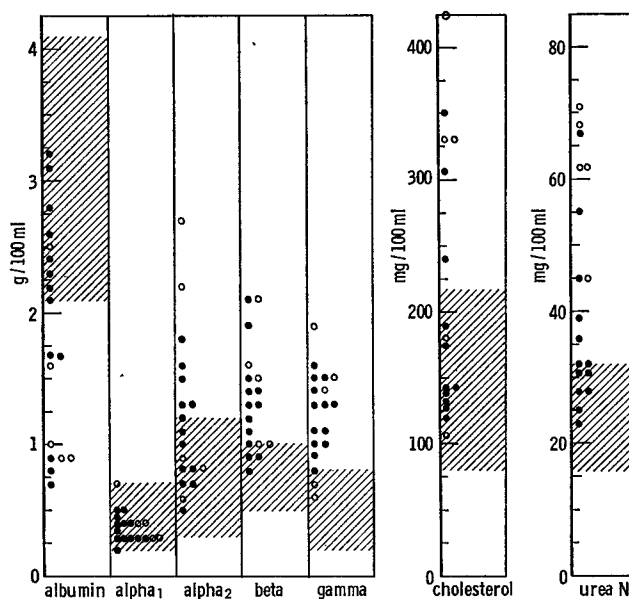
* Results obtained on mice mainly between 2 to 3 months of age.

tive urinary tests for occult blood were usually negative but were positive in about 5% (5/93) of NZB/Bl females whose renal disease displayed a fulminating course resembling lupus nephritis. Features of the nephrotic syndrome, such as described in man, developed in a substantial proportion of NZB/Bl mice of advanced age, Text-figs. 1 and 2: edema and ascites, proteinuria and cylindruria, hypoalbuminemia, elevation of the serum α_2 -globulin levels, and hypercholesterolemia. Terminal azotemia occurred late in the course of chronic renal disease and earlier in fulminating renal disease.

Pathology: Grossly there were four different, but not necessarily separate (6), forms of renal pathology in older NZB/Bl mice: (a) *mahogany brown*, but otherwise normal appearing, kidneys the site of hemosiderosis, associated with autoimmune hemolytic disease; (b) slightly enlarged *pale smooth* kidneys, in chronic

membranous glomerulonephritis; (c) slightly enlarged *pale granular* kidneys, in chronic membranous glomerulonephritis with more advanced structural change; and (d) slightly enlarged pale (*café au lait*) granular kidneys showing *petechial hemorrhages*, in systemic connective tissue disease of lupus type.

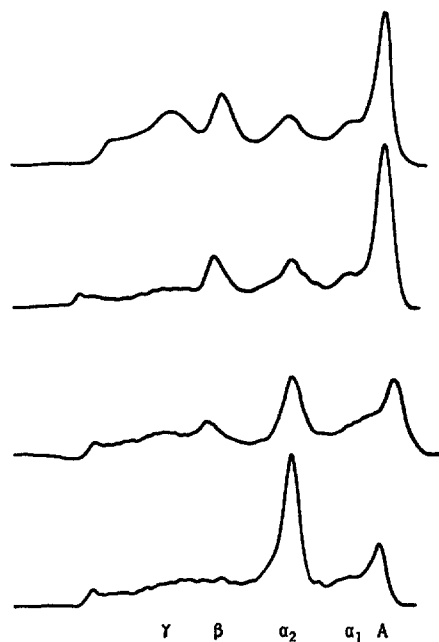
The microscopic changes in chronic membranous glomerulonephritis of NZB/Bl mice were described elsewhere (5) and can be briefly restated with relevance to the present work. The glomerular basement membrane of peripheral capillary loops and the mesangium, or the central region, of the glomerulus gradually underwent structural transformation characterized by the accumu-



TEXT-FIG. 1. Serum proteins, cholesterol, and urea nitrogen in 13 old NZB/Bl mice with chronic membranous glomerulonephritis (closed circles, ●) and 5 mice with systemic connective-tissue disease and lupuslike nephropathy (open circles, ○). Range (average ± 2 SD) of normal values shown by cross-hatching.

lation of carbohydrate rich basement membrane-like materials and by hyalinization of the filtering membrane. The earliest and practically pathognomonic lesion, best seen in Carnoy's fixed 1μ thick sections stained with the periodic acid-methenamine silver method (7) and confirmed by electron microscopy, consisted of homogeneous swelling with nodule formation along the outer (sub-epithelial) aspect of the glomerular capillary basement membrane (5). This lesion was not observed in NZB/Bl mice less than 4 months of age and, along with the mesangial lesion, was characteristically associated with functional manifestations of renal disease in older NZB/Bl mice.

About 5% of older NZB/Bl females, and a rare male, developed renal disease with an accelerated course and pathological findings resembling lupus nephritis (8). In these instances fibrinoid change and hemorrhage occurred in structurally altered glomeruli whose capillaries became completely permeable to plasma proteins, including fibrin, and to erythrocytes as well. The extravasated blood was present in Bowman's space, where crescents and adhesions were formed by fibro-epithelial proliferation, and in the tubular lumens. Fibrinoid change, and resulting hemorrhage, occurred also in the walls of arterioles



TEXT-FIG. 2. Paper electrophoresis patterns for serum proteins of an NZB/Bl male mouse at 6 (top), 7, and 8 months and with fully developed nephrotic syndrome at 9 months (bottom). Albumin (A) migration to the right.

and small arteries of other organs (spleen, intestine, and uterus). Lupus erythematosus (L.E.) cell tests, positive in 6% (3/54) of our older NZB/Bl mice, were usually negative in these examples of systemic connective tissue disease with lupuslike nephropathy.

One of the spleen cell donors, Tables II and III, had (+++) proteinuria and chronic membranous glomerulonephritis of severe degree, Fig. 1; the other had (+++) proteinuria and systemic connective tissue disease with lupuslike nephropathy, Fig. 2. Both had autoimmune hemolytic disease with anemia, reticulocytosis, and positive direct antiglobulin (Coombs') tests and some

TABLE II
Status of Two Donor NZB/Bl Mice with Renal Disease

Donor No.....	1	2
Sex	F	F
Age, wk	59	40
Urinalysis		
Proteinuria	+++	+++
Occult blood	-	+
Direct antiglobulin test	+	+
Organ weights, g		
Total body	46	31
Spleen	1.12	0.24
Kidneys (2)	0.62	0.50
Thymus	0.02	0.05

TABLE III
Blood Studies on Two Donor NZB/Bl Mice with Renal Disease

Donor No.....	1	2
Hematocrit, %	25*	25*
Reticulocytes, %	91*	21*
Platelets/mm ³	2,190,000	250,000*
Wbc/mm ³	—	3,450
Serum urea nitrogen, mg/100 ml	32	23
Serum cholesterol, mg/100 ml	175	250*
Serum proteins, g/100 ml		
Total	5.0*	5.3
Albumin	2.1	2.2
α_1	0.4	0.3
α_2	0.8	0.9
β	0.8	1.0
γ	0.9*	0.9*

* More than 2 standard deviations from normal mean.

elevation of serum γ -globulins. Donor 1 had splenic enlargement common for the age and the degree of anemia. About 20% of the spleen section was white pulp containing lymphoid cells, and 80% was red pulp, including reticulum cells, plasma cells, and other lymphoid cells, extramedullary hematopoietic cells, and hemosiderin-laden macrophages. The spleen of donor 2 was somewhat smaller than usual at that age, showed fibrinoid lesions of arterioles, and contained cells of the type and general distribution just mentioned.

Induced Renal Disease.—

Clinical pathology: The recipients of adult NZB/Bl spleen cell transplants (~30 to 100 × 10⁶ cells) were healthy young NZB/Bl mice of either sex and

TABLE IV
Status of Six Recipient NZB/Bl Mice with Spleen Cell Transplants

Recipient No.....	1	2	3	4	5	6
Sex	M	M	M	M	F	F
Donor No.	2	1	1	1	2	1
Age, wk						
At transplantation	4	4	4	4	4	8
At autopsy	8	9	9	10	12	13
Urinalysis						
Proteinuria	++	++	+++	++	++	++
Direct antiglobulin test	—	—	—	+	—	—
Organ weights, g						
Total body	30	32	26	34	29	27
Spleen	0.18	0.15	0.09	0.29	0.13	0.09
Kidneys (2)	0.46	0.44	0.42	0.48	0.32	0.31
Thymus	0.01	0.04	0.05	0.03	0.07	0.06

TABLE V
Blood Studies on Six Recipient NZB/Bl Mice with Spleen Cell Transplants

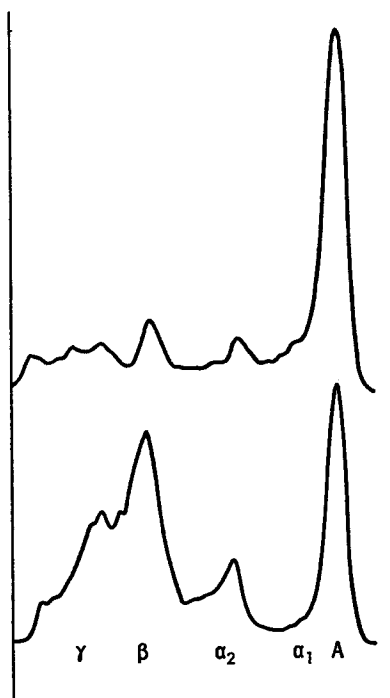
Recipient No.....	1	2	3	4	5	6
Hematocrit, %	29*	48	50	47	49	51
Reticulocytes, %	12*	10*	1	3	1	0.4
Platelets/mm ³	2,500,000	2,100,000	1,700,000	880,000	1,100,000	3,900,000
Wbc/mm ³	3,300	5,300	6,500	4,800	5,400	7,650
Serum urea nitrogen, mg/100 ml	23	19	24	32	31	28
Serum cholesterol, mg/100 ml	144	248*	223*	253*	—	220*
Serum proteins, g/100 ml						
Total	6.3	5.6	6.9*	4.7*	4.5*	6.9*
Albumin	1.6*	2.3	3.2	2.2	1.7*	1.5*
α ₁	0.6	0.3	0.4	0.4	0.6	0.2
α ₂	1.2	1.0	1.1	0.5	0.7	1.2
β	2.5*	1.0	0.9	0.9	0.7	2.5*
γ	0.4	1.0*	1.3*	0.7	0.8	1.5*

* More than 2 standard deviations from normal mean.

usually 4 wk of age, rarely 8 wk, Table IV. The results of laboratory examinations performed on the prospective recipients prior to spleen cell transplantation were, with one exception, in the normal range for 2 to 3 months' old mice, Table I, including the absence of significant proteinuria and negative direct

antiglobulin (Coombs') tests. The exception was hematocrit per cent, with an average value of 37 at 4 wk of age.

Within a few (2 to 5) weeks after spleen cell transplantation, significant proteinuria (++ to ++++) occurred in each recipient, Table IV. The direct antiglobulin (Coombs') test became positive in recipient 4. Blood studies performed at 4 to 8 wk after spleen cell transplantation, Table V, revealed low hematocrit per cent in recipient 1, slightly elevated reticulocytes per cent in



TEXT-FIG. 3. Paper electrophoresis patterns for serum proteins of NZB/Bl female recipient 6 at 3 wk (top) and 5 wk (bottom) after receiving spleen cell transplant from NZB/Bl female donor 1. A, albumin.

recipients 1 and 2, increase of serum cholesterol in recipients 2, 3, 4, and 6, decrease of total serum proteins in recipients 4 and 5 and elevation in recipients 3 and 6, decrease of serum albumin in recipients 1, 5, and 6, and elevation of β - (fast γ -) and/or γ -globulins in recipients 1, 2, 3, and 6, Text-fig. 3. The serum changes (hypoalbuminemia, hypergammaglobulinemia, and hypercholesterolemia) were similar in direction to those observed in adult NZB/Bl mice with severe renal disease, Text-fig. 1.

Pathology: At autopsy, the kidneys and the other organs of 8- to 13-wk-old mice, Table IV, bearing spleen cell transplants for an interval of 4 to 8 wk were,

with few exceptions, grossly normal. Microscopically, the early and the characteristic (membranous and mesangial) lesions of membranous glomerulonephritis were identified in the kidneys of each recipient. In some, but not all, glomeruli the basement membrane of one or more peripheral capillary loops was structurally transformed by the accumulation of carbohydrate rich basement membranelike materials associated with homogeneous expansion of the basement membrane and nodular protrusions along its outer (subepithelial) aspect, Fig. 3. The mesangium, or the central region, of some of the glomeruli also contained excessive amounts of basement membranelike materials, Fig. 4. It is to be emphasized that membranous glomerulonephritis developed in the spleen cell recipients at an age when the spontaneous renal disease was never seen.

The other relevant observations concerned the status of the spleen cell transplant site and the lymphatic organs. In several instances, cellular components similar to those of abundance in the donor spleen were present in the subcutaneous transplant site: hematopoietic cells, including megakaryocytes, reticular cells, lymphoid cells, including lymphocytes and plasma cells, and mononuclear phagocytes containing hemosiderin, Fig. 5. The spleens of the recipients were composed of about 20% white pulp, with lymphatic nodules, and 80% red pulp, containing hematopoietic cells, reticular cells, and lymphoid cells, including in some instances numerous plasma cells of immature, mature, and Russell-body types, Fig. 6. The lymph nodes contained lymphatic nodules and many reticular cells and plasma cells. The thymus glands were histologically normal except, in some instances, for an excess number of plasma cells.

DISCUSSION

These studies made it clear that the transplantation of syngeneic spleen cells from old to young NZB/Bl mice was a sufficient condition to induce membranous glomerulonephritis in the recipients within a few weeks and well in advance of its usual spontaneous occurrence. The development of hypergamma-globulinemia and lymphoid cell hyperplasia together with one instance of Coombs' test conversion in the young mice indicated that immunologically competent cells, derived from either the transplant or the recipient, proliferated during this process. These experiments, together with the demonstration in the spontaneous renal disease of immunoglobulins fixed to, and showing in vitro affinity for, the altered glomeruli (5), provided further support for the view that membranous glomerulonephritis in NZB/Bl mice is produced by immunological, and probably autoimmune, mechanisms. Evidence of similar kind has already been presented in autoimmune hemolytic disease of NZB/Bl mice by Holmes and her associates (9, 10). In their studies, intraperitoneal inoculations of spleen cell suspensions prepared from old NZB/Bl mice with a positive Coombs' antiglobulin test induced a positive Coombs' test in normal

young NZB/Bl mice after 1 to 3 wk, accompanied by splenic enlargement and histological changes in the spleen and thymus. Cell suspensions prepared from lymph nodes, thymus, bone marrow, or buffy coat failed to induce Coombs' test conversion.

The fact that the transplantation of spleen cells induced, under separate experimental conditions, diseases of two kinds, renal and hemolytic and apparently almost wholly unrelated (5), favors the hypothesis that "disturbed" immunological tolerance rather than "disturbed" (altered) antigen is a basic underlying mechanism. A nonimmunological hypothesis would implicate non-specific reactive immunoglobulins or, lacking these, other as yet unidentified mechanisms.

SUMMARY AND CONCLUSIONS

The transplantation of spleen cells from old NZB/Bl mice with renal disease induced both the structural and the functional changes of membranous glomerulonephritis in young NZB/Bl mice within a few weeks and well in advance of its usual spontaneous occurrence. The development of hypergammaglobulinemia and lymphoid cell hyperplasia in the young mice indicated that immunologically competent cells, derived from either the transplant or the recipient, proliferated during this process. These experiments, together with other findings, provide further support for the view that membranous glomerulonephritis in NZB/Bl mice is produced by immunological, and probably autoimmune, mechanisms and that the renal disease is apparently almost wholly unrelated to the hemolytic process.

This work was supported in part by grants from the National Institute for Arthritis and Metabolic Diseases of the United States Public Health Service.

The technical assistance of David Bardell and Dolores A. Bentham is gratefully acknowledged.

BIBLIOGRAPHY

1. Bielschowsky, M., Helyer, B. J., and Howie, J. B., Spontaneous hemolytic anaemia in mice of the NZB/Bl strain, *Proc. Univ. Otago Med. School*, 1959, **37**, 9.
2. Holmes, M. C., and Burnet, F. M., The natural history of autoimmune disease in NZB mice. A comparison with the pattern of human autoimmune manifestations, *Ann. Int. Med.*, 1963, **59**, 265.
3. Long, G., Holmes, M. C., and Burnet, F. M., Autoantibodies produced against mouse erythrocytes in NZB mice, *Australian J. Exp. Biol. and Med. Sc.*, 1963, **41**, 315.
4. Helyer, B. J., and Howie, J. B., Positive lupus erythematosus tests in cross-bred strain of mice NZB/Bl-NZY/Bl, *Proc. Univ. Otago Med. School*, 1961, **39**, 17.
5. Mellors, R. C. Autoimmune disease in NZB/Bl mice. I. Pathology and pathogenesis of a model system of spontaneous glomerulonephritis, *J. Exp. Med.*, 1965, **122**, 25.

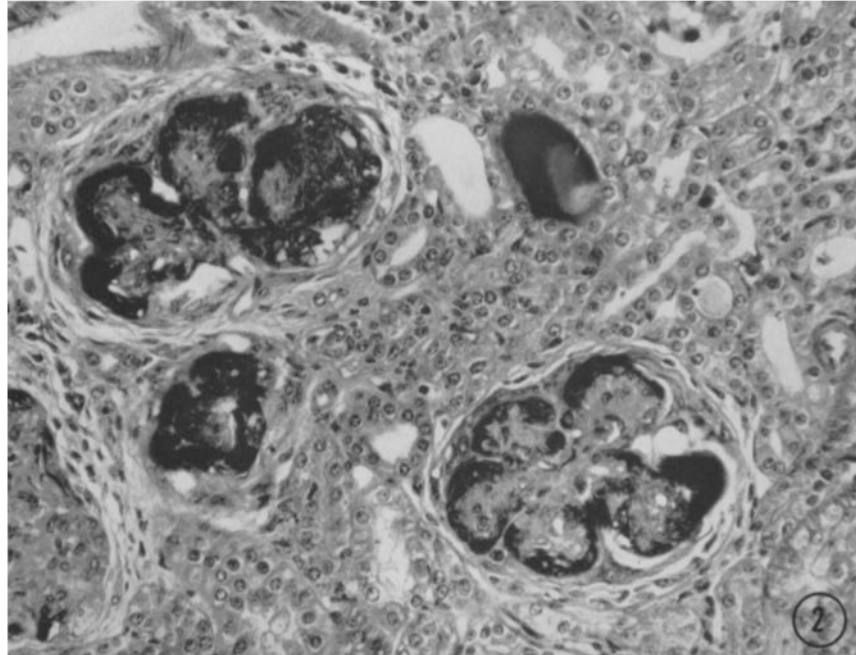
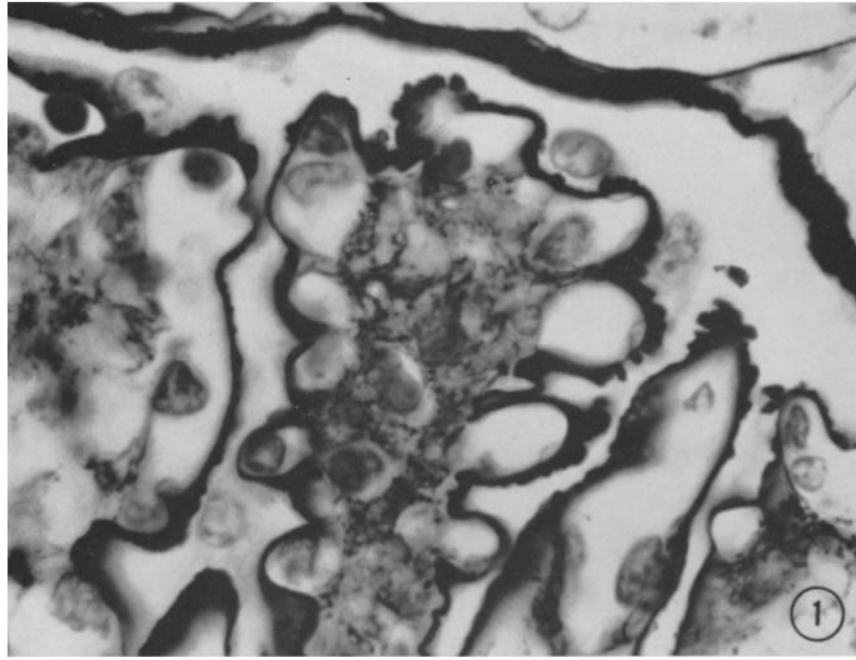
6. Howie, J. B., and Helyer, B. J., Autoimmune disease in mice, *Ann. New York Acad. Sc.*, 1965, **124**, 167.
7. Jones, D. B., Nephrotic glomerulonephritis, *Am. J. Path.*, 1957, **33**, 313.
8. Helyer, B. J., and Howie, J. B., Renal disease associated with positive lupus erythematosus tests in a cross-bred strain of mice, *Nature*, 1963, **197**, 197.
9. Holmes, M. C., Gorrie, J., and Burnet, F. M., Transmission by splenic cells of autoimmune disease occurring spontaneously in mice, *Lancet*, 1961 **2**, 638.
10. Holmes, M. C., Coombs test conversion in young NZB mice induced by transfer of lymphoid cells from Coombs positive donors, *Australian J. Exp. Biol. and Med. Sc.*, 1965, **43**, 399.

EXPLANATION OF PLATES

PLATE 100

FIG. 1. Kidney (donor 1), chronic membranous glomerulonephritis. Portion of a glomerulus with peripheral capillary loops showing thickening of wall and nodule formation along outer (subepithelial) aspect of the capillary basement membrane. 1 μ section. Periodic acid-methenamine silver stain, \times 1440.

FIG. 2. Kidney (donor 2), lupuslike nephropathy. Fibrinoid change in structurally altered glomeruli, with extravasation of fibrin and blood in Bowman's space and tubular lumen; and fibroepithelial proliferation in Bowman's space. Phosphotungstic acid-hematoxylin, \times 300.

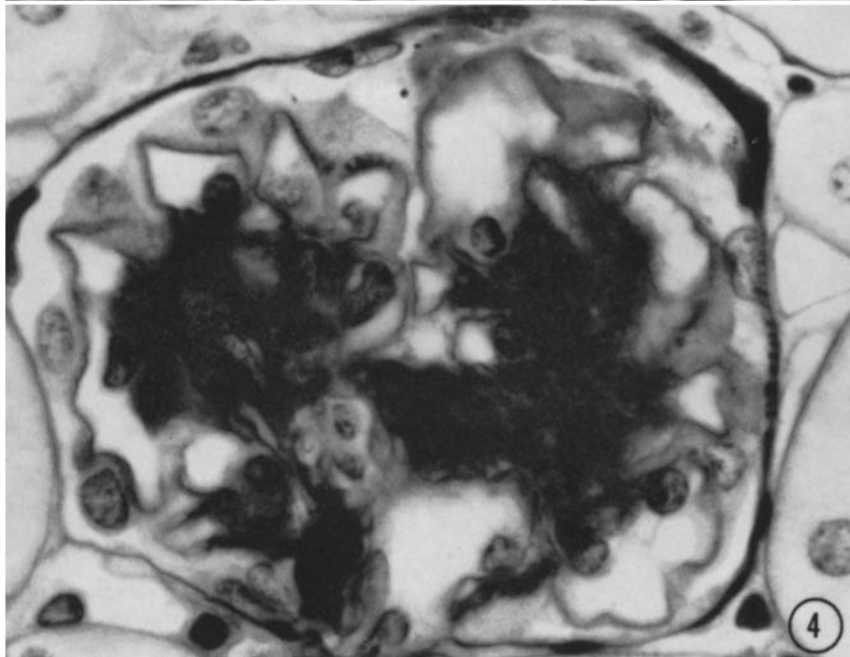
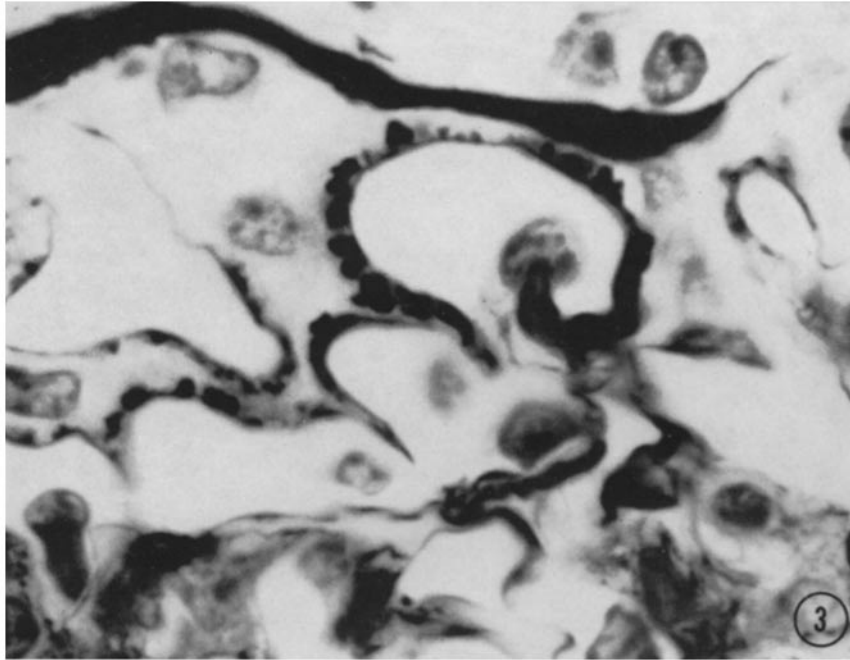


(Mellors: Autoimmune disease in NZB/Bl mice. III)

PLATE 101

FIG. 3. Kidney (recipient 6), membranous glomerulonephritis. Portion of a glomerulus with peripheral capillary loops showing thickening of wall and nodule formation along outer (subepithelial) aspect of the capillary basement membrane. 1 μ section. Periodic acid-methenamine silver stain, \times 2160.

FIG. 4. Kidney (recipient 6), membranous glomerulonephritis. Mesangial lesion, with accumulation of basement membrane-like materials in the central region or stalk of the glomerulus; and nodular membranous lesion in peripheral capillary loop at 12 o'clock. Periodic acid-Schiff stain, \times 1440.

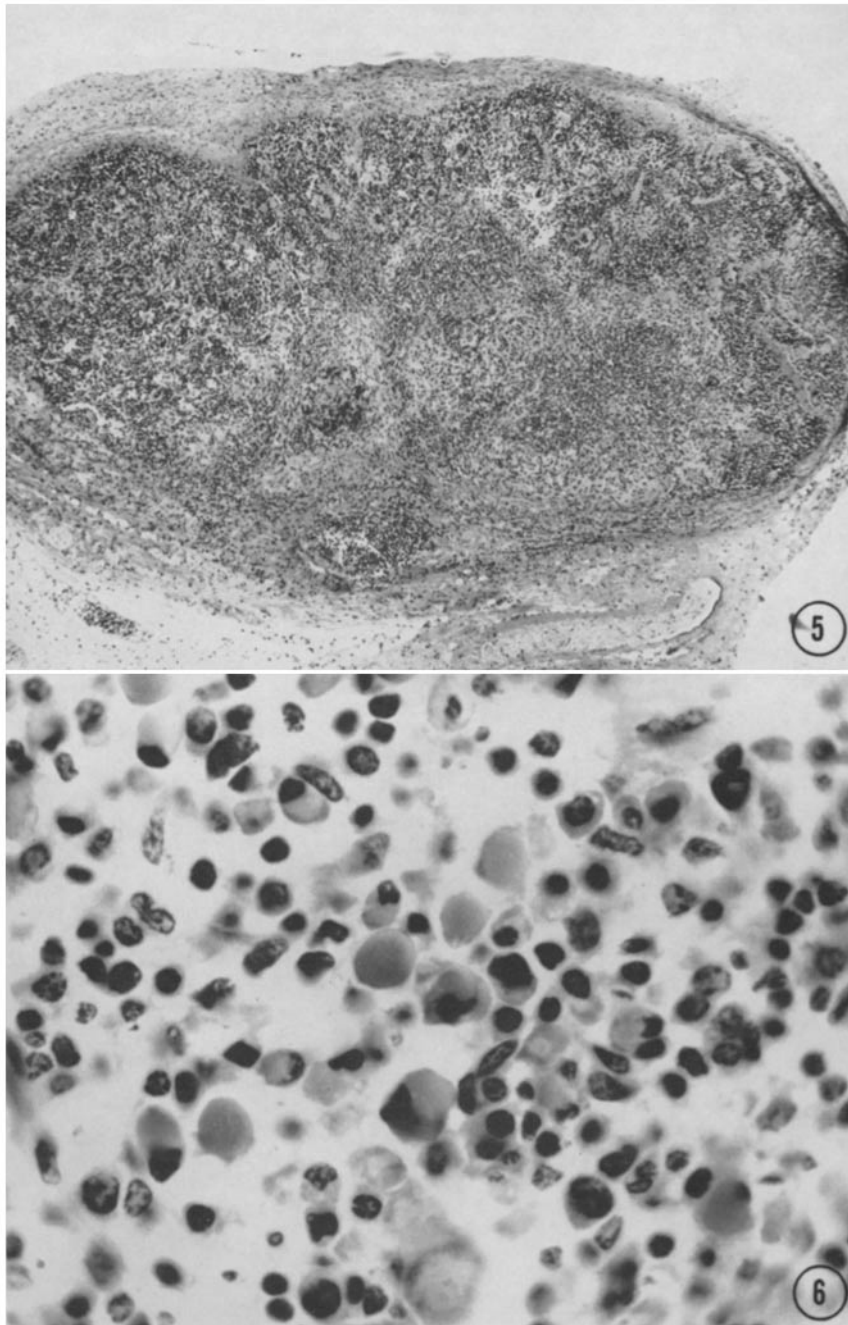


(Mellors: Autoimmune disease in NZB/Bl mice. III)

PLATE 102

FIG. 5. Subcutaneous tissue (recipient 1), the site of spleen-cell transplantation (from donor 2) and somewhat resembling a miniature spleen. Hematoxylin-eosin, $\times 60$.

FIG. 6. Spleen (recipient 6) containing numerous Russell-body plasma cells (gray in illustration, bright red in section, and also periodic acid-Schiff positive). Hematoxylin-eosin, $\times 960$.



(Mellors: Autoimmune disease in NZB/Bl mice. III)