

THE HISTOLOGICAL CHANGES IN NERVE CELLS  
DUE TO TOTAL TEMPORARY ANÆMIA OF  
THE CENTRAL NERVOUS SYSTEM.<sup>1</sup>

BY LIBORIO GOMEZ AND F. H. PIKE.

(From the Hull Physiological Laboratory, The University of Chicago.)

PLATE IV.

In the course of some experiments on the resuscitation of the central nervous system, the question arose as to whether it would be possible to determine from the histological appearance of the cells, after being subjected to anæmia for a given period, which of them might recover under proper conditions, and which of them were injured beyond the possibility of recovery. Again, in cases of recovery, it was thought that there might be some relation between the degree of functional return and the morphological appearances of the nerve cells. The present paper attempts a partial answer to these questions.

*Previous Histological Work.*—The classical experiment of Stenson and Swammerdam—ligation of the abdominal aorta for varying periods of time—first described by these two investigators and later by Haller, has been repeated by many workers in order to determine the histological changes resulting from interference with the blood supply of the spinal cord.

A review of the literature up to the time of publication of their paper is given by de Buck and de Moor (1). Most of the work was done on the spinal cord. Artificial anæmia was induced by Stenson's modified method, *i. e.*, passing a curved needle and thread around the spinal column at about the fourth lumbar vertebra, thus compressing the aorta against it (Ehrlich and Brieger (2), Singer (3), Spronck (4), Herter (5), Singer and Münzer (6), Münzer and Wiener (7), Sarbo (8), Marinesco (9), Rothman (10), Rhigetti (11), Jatta (12) and others). Ballet and Dutil (13) have resorted to temporary or permanent digital compression of the abdominal aorta. Experimental embolism, by injecting lyco-podium spores has been tried by Lamy (14), Singer and Rothmann (15).

<sup>1</sup> Received for publication October 19, 1908.

Most authors agree with Ehrlich and Brieger that one hour of ligation of the abdominal aorta produces death of the cell, whereas Spronck believes that ligation for half an hour is sufficient to produce necrosis and destruction of the cells in rabbits.

The character of the lesions is much disputed. The primary œdema described by Marinesco (9) has not been seen by other observers. Chromatolysis is admitted by most authors, the peripheral type being frequently seen. Reticular formation has been seen by many, but its exact significance is not known. As alterations of the achromatic substance the following are described: (1) Vacuolization, which is believed by Marinesco to begin at the periphery and to appear only after chromatolysis has occurred. Jatta, however, finds it to be more centrally located and already shown where the Nissl bodies are still intact. (2) Molecular disintegration and fracture of the protoplasm and dendrites are also described. (3) Most authors agree that the cell is atrophied after anæmia, although Marinesco insists on a primary œdema. (4) The nucleus is found by Sarbo to undergo acute homogeneous atrophy. Jatta found, on the other hand, karyorrhexis or disintegration of the chromatin. Ballet and Dutil, and Rothmann are the only observers who have described migration of the nucleus towards the periphery as a result either of a disaggregation of the cytoplasm or disturbance of intracellular pressure. (5) The nucleolus is generally considered to have great resistance. Swelling, atrophy, fragmentation and fusion with the nuclear substance have been described as pathological alterations.

Rhigetti is the first to call attention to the difference in the lesions occurring after a temporary or a permanent anæmia, the lesions appearing later in the latter condition, and resembling cadaveric changes.

The great resistance of the spinal ganglion cells was pointed out by Ehrlich and Brieger, and confirmed later by de Buck and de Moor. After a temporary ligation, de Buck and de Moor found around the nerve cells an infiltration of lymphoid cells which they believed to be phagocytes exuded from the lymph stream. Tuckett (16), by sectioning branches of the carotid artery and dissecting out the sheath of the sympathetic trunk, induced anæmia of the superior cervical sympathetic ganglion, the cells of which he found to possess greater resistance than those in the spinal cord. The changes within five days correspond nearly to the lesions in the cord after from twenty-four to forty-eight hours as described by Münzer and Wiener.

Mott (17) studied the changes produced in the brain of the monkey by the permanent ligation of the carotid and vertebral arteries on both sides, and found that swelling of the cell and chromolytic changes occurred within less than ten minutes after ligation. In animals that die within twenty-four hours after ligation of these arteries, the cortical ganglion cells, when stained by Nissl's method, show a uniform diffuse staining, absence of Nissl granules, an appearance of coagulating necrosis, denoting a biochemical change in the protoplasm and permanent loss of function. On the other hand, if signs of recovery are evident twenty-four hours after operation the cells are swollen, with the nucleus greatly enlarged and displaced, but there is still a differentiation into chromatic and achromatic substances, denoting biophysical rather than biochemical changes and temporary, rather than permanent, depression of function.

Later, Hill and Mott (18), using Cajal's method for neurofibrils, examined the brains of animals similarly treated, which showed signs of recovery. The neurofibrils were found to be intact, although the cells were greatly swollen.

*Material and Technique.*—The material was obtained, for the most part, from the animals used in the series of physiological experiments, the principal facts of which have been given in a previous paper (19), anæmia being produced by ligation of the carotid and subclavian arteries. A few cats were subjected to varying periods of anæmia, and the material taken at the desired stage of anæmia or subsequent recovery. The central nervous system was removed and pieces fixed in ninety-six per cent. alcohol and in Muller's fluid. The staining methods used were Nissl's methylene blue, with or without counterstaining with erythrosin, the Pal-Weigert and the Marchi. A two-thirds grown normal cat was killed by ether and the nervous tissue used for comparison.

The physiological department of the animals is given for the most part in the paper cited, the numbers of the experiments being the same in that and in the present paper. Some further facts are given in later papers (20).

*The Nature of the Lesions.*—The pericellular lymph space is dilated in animals in which the circulation has been allowed to return, so that it is two or three times wider than normal (Fig. 10). This extracellular œdema disappears after a certain time. After recovery is complete the lymph space is reduced to normal size. When the tissue is taken during the period of anæmia the space is rather diminished or not greater than normal in size (Fig. 9).

The contour of the cells tends to assume a somewhat rounded outline when circulation is restored. This is best seen in cells of the anterior horn of the spinal cord, whose edges are normally concave, but which become more convex from the intracellular œdema. It is hard to make out the difference between the contour of a normal cell, a cell subjected to anæmia without restoration of the circulation, and a cell which has completely recovered after being subjected to anæmia.

The subsequent increase of blood pressure when the flow returns and the probable alteration in the cement substance of the endothelium incident to the anæmia of the capillaries may possibly ex-

plain the increased transudation of lymph into the pericellular lymph spaces. The cells possibly swell by imbibition, which is favored by changes in their physical character brought about by anæmia. It has been shown by Galeotti (21) that the permeability of some cells rises sharply at death, and that other cells, *e. g.*, epithelial cells of the intestine, become permeable to ions which would not be allowed to pass under normal conditions. There is little doubt, therefore, that the permeability of the nerve cells is altered by the anæmia, and that substances in the blood and lymph which might normally be excluded now pass through the cell membrane, which has become indifferent to the ions seeking entrance or exit. There is the further possibility also that there have been formed in the nerve cells, or tissues about them, during the period of anæmia some toxic products whose presence disturbs the normal physico-chemical relationships of the cells and fluids, and which may thus give rise to the spasms seen during resuscitation. The amount of these toxic substances need not necessarily be great enough to affect distant normal nerve cells because of their presence in the blood. This idea is not incompatible with what has been observed regarding toxins in the blood of the resuscitated animals (22). In cats that die as a result of prolonged cerebral anæmia, many hours after the restoration of the blood supply, the cells are shrunken and irregular in outline, and the pericellular lymph spaces are relatively wider.

The chromatin bodies show two different kinds of lesions. One, seen in large ganglion cells (spinal cord, retina, etc.) is manifested in irregularity of outline, clumping and diffuse blue staining often extending into the nucleus, which is only marked by the presence of the relatively unchanged, deeply-stained nucleolus. As the process advances the chromatin breaks down into fine dustlike particles, which afterward become unstainable from the periphery to the center (Fig. 2). In another type of lesion, seen in the small nerve cells (small pyramidal and bipolar cells of the retina), there is a tendency to lose affinity for the stain, the granules becoming paler, and those that are stained being fewer in number.

Vacuolation of the cytoplasm occurs when the period of anæmia is long, say twenty-two minutes, and the animal survives for several hours afterwards (Fig. 6). Under these conditions the

nucleus has been seen slightly displaced towards the periphery, but we were not able to see actual extrusion of the nucleus through the cell wall.

The nucleus is often diffusely stained blue, almost uniform with the diffuse blue staining cytoplasm. In prolonged occlusion the outline becomes irregular and shrunken. A decreased affinity of the nuclear chromatin for the stain is marked in small nerve cells. We have not seen any changes in the nucleolus by the methods used.

Some nerve cells of the cat that was killed for control show chromatolytic changes which may be due to a different stage of functional activity (van. Durme (23)) or to the effect of ether (Wright (24)). The average, however, is taken here for comparison.

The changes produced by occlusion of the arteries of the head vary with the length of the period of anæmia and the time that elapses after resuscitation. Chromatolysis alone, shown in tissues taken during or immediately after the experiment, does not mean death of the cell. A certain length of time must elapse after the reestablishment of the circulation before the shrinkage of the nucleus, vacuolation and shrinkage of the protoplasm, and displacement of the nucleus, signifying solution of the achromatic substance and probable permanent impairment of the cell functions, become apparent.

The fact that a certain time must elapse after resuscitation in order to bring about the complete histological destruction of the cell is similar to the finding of Favre and Laignel-Lavastine (25), namely, that a certain interval must elapse after death before any changes in the Nissl substance of the nerve cells can be detected by histological methods.

These facts make it probable that enzymes, either within the cell or in the tissue fluids, are responsible for the final destruction of the nerve cell. This hypothesis is in harmony with the observation of Rhigetti that changes are produced sooner after temporary anæmia, possibly because of the greater amount of cytolytic enzymes that circulate when the circulation is restored; and with the findings of de Buck and de Moor of neuronophagic mononuclear leucocytes, which may furnish cytolytic enzymes when they break down.

The neurones of different animals and the neurones of the same or different regions of the same animal show different degrees of alterations with the same period of anæmia. The number of affected cells, due either to individual cellular resistance or to different collateral or lymphatic circulation, also varies.

The small pyramidal cells are the most sensitive to anæmia, showing a lessened degree of affinity to methylene blue. Eight minutes of anæmia was sufficient to kill many of the pyramidal cells of the cat of Experiment 74 (19). This animal was allowed to live three months after resuscitation. The spinal cord in the upper cervical region showed early degeneration of the pyramidal tracts. The Purkinje cells are next in the order of sensitiveness, diffuse chromatolysis being seen after thirteen minutes of anæmia.

The cells of the medulla are rather resistant. In the cat of Experiment 87, which was subjected to anæmia for twenty-two minutes, and survived twenty hours after return of circulation, the cells showed diffuse chromatolysis, with greatly diminished affinity for the stain. In this case the diffuse chromatolysis is probably in part due to profound changes in the protoplasm, by which the broken down chromatin granules, poorly stained, are diffused throughout the substance of the cell. The changes in the medulla—the seat of the respiratory and vaso-motor centers—may explain the failure to resuscitate some animals. Eight to thirteen minutes of anæmia may provoke no, or only slight, lesions. Twenty to thirty minutes may produce deeper alterations which are incompatible with complete recovery of the animal.

The retina shows about the same degree of resistance as the medulla oblongata. We have examined the retinas of cats subjected to anæmia of twelve and thirty minutes respectively, without return of the circulation, and thirteen minutes of anæmia followed by thirteen minutes of reëstablished circulation before death. The material from these three retinas does not differ to any extent. In general the ganglion cells of all of them showed a less distinct outline of the Nissl bodies, less affinity for the stain, some clumping and diffuse staining. The inner and outer granular layers were paler and of a more greenish tint when stained with methylene blue.

The cervical cord showed slight chromatolysis after an occlusion

of thirteen minutes with a subsequent reestablishment of the circulation. More marked still were the changes in the cat of Experiment 87 (*vide supra*), the cells in the spinal cord of which showed marked chromatolysis and vacuolation. The cells of the posterior horn were less affected than those of the anterior horn. We have seen no changes in the spinal ganglia after thirty minutes of anæmia.

The neuroglia cells, although subjected to the same degree of anæmia, do not seem to be at all affected. When circulation was allowed to return, pericellular œdema, more marked around groups of cells, was seen. This is in accordance with the ideas of Cohnheim that, during anæmia of a portion of an organ, the tissues are affected in the order of the height of their differentiation.

#### SUMMARY AND CONCLUSIONS.

With the return of the circulation, dilation of the pericellular lymph space and slight swelling of the cell body occurs, disappearing as recovery progresses. Chromatolysis, as evidenced by poor affinity for stains, clumping, diffuse staining, and breaking into dust-like particles, induced by anæmia, is not necessarily fatal. Death of the cell is not shown histologically when tissue is removed and fixed immediately after the experiment. Some time must elapse for the detection of the vacuolation, displacement of the nucleus and solution of the chromatic substance, indicative of profound changes. Neurones from different regions as well as neurones of the same region differ in degree of resistance to anæmia. The small pyramidal cells are the most susceptible, and then come the Purkinje cells, cells of the medulla oblongata, retina, cervical cord, lumbar cord, spinal ganglia and, most resistant of all, the sympathetic ganglion cells. Failure to resuscitate animals after anæmia of the central nervous system is probably due to the destruction of many of the cells of the vital centers (vaso-motor and respiratory) which do not have histological peculiarities by which they may be defined. Death, however, of a few cells of any center does not necessarily mean the total loss of function of that center, since the remaining cells may be sufficient to discharge the function of the center.

## BIBLIOGRAPHY.

1. de Buck and de Moor, *Le Neuraxe*, 1901, ii, 2.
2. Ehrlich and Brieger, *Zeit. f. klin. Med.*, 1884, vii, Supplement, 155.
3. Singer, *Sitzungsberichte der kais. Akad. der Wissenschaft zu Wien*, 1887, xcvi, 136.
4. Spronck, *Arch. de physiol. norm. et path.*, 1888, i, 1.
5. Herter, *Jour. of Nervous and Mental Disease*, 1889, xvi, 197.
6. Singer and Münzer, *Akad. der Wissenschaft zu Wien, Denkschriften*, 1890, lviii, 569.
7. Münzer and Wiener, *Arch. f. exp. Pathol. und Pharm.*, 1895, xxxv, 113.
8. Sarbo, *Neurolog. Centralbl.*, 1895, xiv, 664.
9. Marinesco, *Compt. rend. de la Soc. de Biol.*, 1896, xlviii, 230, *Presse med.*, 1897, v, 42.
10. Rothmann, *Neurol. Centralbl.*, 1899, xviii, 2, 61.
11. Rhigetti, *Riv. di patol. nerv. e mentale*, 1899, iv, 153.
12. Jatta, *Archiv. per le sci. med.*, 1898, xxii, 293.
13. Ballet and Dutil, *Arch. de neurol.*, 1897, iv, 430.
14. Lamy, *Arch. de physiol. norm. et path.*, 1895, vii, 77.
15. Singer and Rothmann, *Zeit f. Heilk.*, 1897, xviii, 105.
16. Tuckett, *Jour. of Physiol.*, 1905, xxxiii, 77.
17. Mott, *Lancet*, 1900, i, 1779; *idem.*, ii, 1849.
18. Hill and Mott, *Jour. of Physiol.*, 1906, xxxiv, 4 (abstract).
19. Stewart, Guthrie, Burns and Pike, *Jour. of Exper. Med.*, 1906, viii, 289.
20. Pike, Guthrie and Stewart, *Jour. of Exper. Med.*, 1908, x, 490.
21. Galeotti, *Arch. ital. de biol.*, 1902, xxxviii, 137.
22. Pike, Guthrie and Stewart, *Amer. Jour. of Physiol.*, 1908, xxii, 60.
23. van Durme, *Le Neuraxe*, 1901, ii, 115.
24. Wright, *Jour. of Physiol.*, 1900, xxv, 30.
25. Favre and Laignel-Lavastine, *Rev. neurol.*, 1906, ix, 1089.

## EXPLANATION OF PLATE IV.

All the figures are drawn from cells stained by the Nissl method.

FIG. 1. Zeiss; oil imm., 2 mm.; oc. 3. A small pyramidal cell from normal cat killed by etherization.

FIG. 2. Leitz; oil imm.,  $\frac{1}{2}$ ; oc. 2. A small pyramidal cell of a cat subjected to anæmia during thirteen minutes. Tissues taken thirteen minutes after return of circulation. Showing poor affinity to stain and small number of chromatin granules.

FIG. 3. Zeiss; comp. oc. 6; oil imm.; obj. 2 mm. Large pyramidal cell from the same cat as in Fig. 2. Showing clumping or beginning chromatolysis.

FIG. 4. Zeiss; oil imm., 2 mm.; compens. oc. 6. Purkinje cell of cat subjected to twelve minutes of anæmia. Showing diffuse staining centrally and chromatolysis peripherally.

FIG. 5. Zeiss; compens. oc. 6; oil imm., 2 mm. Cell from medulla oblongata of cat used in Experiment 87; twenty-two minutes of anæmia; death within twenty hours. Showing diffuse chromatolysis and lessened affinity for stain.

FIG. 6. Leitz; obj. 7; oc. 2. Anterior horn cell of cervical spinal cord of cat of Experiment 87. Showing vacuolation and partial chromatolysis.



*Plate IV to be inserted opposite page 264 will accompany No. 3,  
Volume XI, of the Journal of Experimental Medicine.*

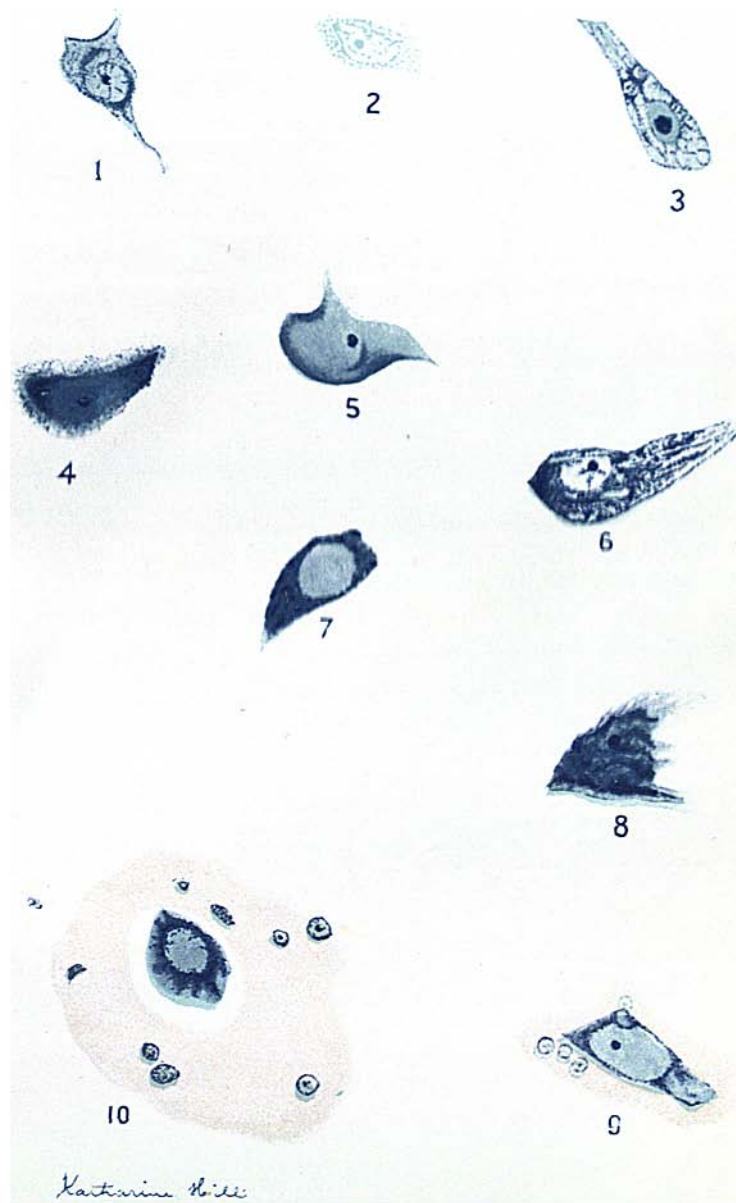


FIG. 7. Leitz; obj. 7; oc. 2. Normal ganglion cell of retina.

FIG. 8. Zeiss; compens. oc. 6; oil imm.; obj. 2 mm. Ganglion cell from the retina of a cat subjected to thirty minutes of anæmia. Tissues taken at the end of period of occlusion. Showing clumping and beginning solution of the chromatic bodies.

FIG. 9. Zeiss; oc. 3; oil imm., 2 mm. Anterior horn cell from cervical cord of cat subjected to thirty minutes of occlusion, the circulation not being allowed to return. Shows much chromatolysis and almost complete obliteration of the pericellular lymph space.

FIG. 10. Leitz; oc. 2; oil imm.,  $\frac{1}{2}$ . Anterior horn cell from cervical cord of cat subjected to thirteen minutes of anæmia. Killed thirteen minutes after reëstablishment of cerebral circulation. Shows chromatolysis, and intra- and extra-cellular œdema.