

# FLUORESCENT ANTIBODY DETECTION OF THE ANTIGENS OF THE SHOPE PAPILLOMA VIRUS IN PAPILLOMAS OF THE WILD AND DOMESTIC RABBIT

BY WILBUR FISKE NOYES, PH.D., AND ROBERT C. MELLORS, M.D.

(From the Pathology Division, Sloan-Kettering Institute for Cancer Research; and Cornell University Medical College, Sloan-Kettering Division, New York)

PLATES 47 TO 49

(Received for publication, June 19, 1957)

The fluorescent antibody method holds promise of providing a new means for the study of the role of viruses in the etiology and the pathogenesis of neoplastic diseases (1). For example, a determination of the cellular distribution and intracellular localization of the Shope papilloma virus antigens in papillomas of the wild cottontail rabbit and a study of any changes in the distribution and localization of the antigens occurring in papillomas of the domestic rabbit would be of value in understanding the mechanism of "masking" of this virus.

Beard (2) has suggested that "masking" of the papilloma virus is only a manifestation of a quantitative difference in the amount of virus present in the two situations. Demonstration of the viral antigens by labelled antibody would help to clarify this point.

This present paper reports the results obtained by a fluorescein-labelled antibody study of the Shope papilloma virus in papillomas of the wild and domestic rabbit.

## *Materials and Methods*

*Wild rabbits.*—The cottontail rabbits were obtained from Earl Johnson, Rago, Kansas. Both normal and tumor-bearing animals were obtained and the latter usually had multiple growths about the neck, shoulders, and abdomen.

*Virus.*—The usual virus source was a naturally occurring papilloma of a cottontail. This was removed and ground in a mortar with pH 7-buffered saline to give a 20 per cent suspension, then centrifuged at 2500 R.P.M. for 5 minutes. The supernatant fluid was rubbed into a shaved and scarified area of the skin. The papillomas appeared between 7 and 10 days after inoculation when fresh material was used. At the start of the study Dr. Richard Shope kindly inoculated several domestic rabbits with virus he had prepared.

*Antibody.*—A pool of serum was prepared from several cottontails bearing multiple, large, naturally occurring papillomas. These animals were resistant to reinoculation with the virus, and samples of the serum were found to neutralize the undiluted virus completely, which was not true of serum from normal rabbits. The fact that animals bearing papillomas have high titres of antibody against the virus has been reported previously (3). Four hyperimmune sera, kindly provided by Dr. Richard Shope, were also separately tested, with confirmation of the essential findings reported herein.

*Preparation of the Fluor.*—The pooled rabbit antiserum was concentrated by precipitation with half-saturated ammonium sulfate and coupled with fluorescein isocyanate by the method of Coons and Kaplan (4). The isocyanate in acetone solution (containing a slight turbidity of calcium sulfate) has been used successfully on many occasions after up to 8 months' storage in sealed tubes in the dark at  $-20^{\circ}\text{C}$ . The labelled antibody was absorbed once with acetone-precipitated rabbit liver powder to remove slight non-specific staining. Sufficient liver powder was used to give the consistency of light cream and absorption was carried out for 1 hour. The liver powder was prepared by homogenizing the liver from one animal in 100 ml. of staining buffer (0.01 molar phosphate buffered saline at pH 7.0) in a blender for 2 minutes, adding four volumes of acetone, and washing on a Buchner funnel with 5 pounds of acetone. This gives a very light fluffy powder.

*Sectioning.*—The specimens were rapidly frozen and sectioned immediately or stored at  $-20^{\circ}\text{C}$ . in tightly stoppered tubes. Sections were cut using a model 820 Spencer rotary microtome with attachments to allow cooling of both the block and the knife blade with crushed dry ice. This method of frozen-sectioning is an adaptation of the method described by Mellors and Ortega (5) and is described in another publication (6). Excellent, thin sections (5 microns or less) of even large blocks up to 20 mm. in diameter have been obtained with this technique. The sections were air-dried for 15 minutes and fixed in acetone for 15 minutes before staining. They were fixed in 12 per cent formalin in staining buffer for 10 minutes before hematoxylin and eosin staining.

*Staining.*—The sections were stained with the fluor for 1 hour at room temperature under Petri dishes containing moistened filter paper. The fluor was then carefully rinsed away and the slide immersed in buffered saline for 10 minutes and mounted in pH 7-buffered glycerol.

*Controls.*—Normal rabbit skin did not stain with the fluor nor did a rabbit papilloma induced by repeated painting with benzpyrene (kindly supplied by Dr. Ernest Wynder). Furthermore, the serum globulins from the rabbit bearing the benzpyrene tumor did not give any staining reaction in the chemical papilloma by the indirect method (7). (The indirect method was positive with the cottontail papilloma and cottontail serum). The staining of the cottontail papillomas by labelled antiserum against the Shope virus was completely blocked by prior treatment with unlabelled antiserum against the Shope virus, but the staining was not blocked by normal rabbit serum or several heterologous rabbit antisera. Absorption of the fluor with a crude lyophilized preparation of the Shope virus greatly reduced the intensity of the specific staining, but absorption with the same amount of similarly prepared material from a chemical papilloma did not reduce the intensity of fluorescent staining of the viral antigens. Finally, several other conjugates including one prepared against vaccine virus did not stain the cottontail papillomas.

*Fluorescence Microscopy.*—A Bausch and Lomb 10 ampere direct current automatic carbon arc was used as the ultraviolet source with darkfield illumination. Filtration was by 3 cm. of 10 per cent copper sulfate and either a Corning 5850 or 5113 filter. For visual work the microscope was equipped with a Wratten No. 3 gelatin filter in the eye-piece, and for photography this was replaced with a Wratten K-3. The 5113 source filter was used when there were brightly autofluorescent objects in the field as was encountered in some keratohyaline areas. For photography, polaroid type 44 film was used (See Figs. 1 to 5, 11). This film was convenient but negatives prepared from the print were unsatisfactory. Kodak tri-X and royal ortho  $4 \times 5$  inch sheet film were tried and gave excellent results with about the same exposure time as polaroid 44, which was 4 minutes at a magnification of 450 at the film. Recently the new Kodak royal-X pan sheet film has given excellent negatives with 15 second exposures at a magnification of 450 at the film. The advantage of this film was that the short exposure did not cause bleaching of the fluorescence, and thus a number of photographs could be taken. It was also of value in recording faint fluorescence.

## EXPERIMENTAL RESULTS

*Cottontail Papillomas:*

*Distribution of Virus.*—Papillomas ranging in diameter from 2 to 20 mm. were used in this study. The morphologic features conformed to those described by Rous and his associate (8). In our observations on the papilloma, reference will be made to the deeper epithelial layers (the site of proliferating cells derived from the germinal layer), to the intermediate keratohyaline layer, and to the superficial keratinized layer. Figs. 1 to 3 are fluorescence photographs which illustrate the distribution of the Shope papilloma virus antigens in the papillomas of the wild rabbit. The viral antigens were usually present in highest concentration in the keratohyaline layers (*H*, Figs. 1, 2, 4 and 6). The antigens were scattered irregularly in lesser amount through the keratinized layers (*K*, Figs. 1, 2, 4, 5) above the keratohyaline zone and also at the surface of the papilloma (*S*, Fig. 3). Viral antigens did not occur in any of the proliferating cells (*P*, Figs. 1, 2, 4, 6) in the layers below the keratohyaline zone, except that trace amounts of the antigens did occur in some of the cells a few layers below the lower limit of the keratohyaline zone (*P*, Fig. 3). The antigen did not occur in the germinal cells (*G*, Fig. 6). The amount of viral antigen varied with the individual tumor, and this is well shown by Fig. 1 and 2, illustrating the fluorescent staining of two papillomas which developed in cottontails after inoculation. The tumors were of the same size, but the tumor illustrated in Fig. 2 was 4½ weeks old while the other was 2½ weeks old. Even tumors of the same age differed markedly in antigen content. Naturally occurring papillomas that were not heavily keratinized usually had an abundant amount of antigen, and the pattern of distribution of antigen was the same as that seen in papillomas produced by inoculation of the virus.

*Intracellular localization.* The viral antigens were present only in the nucleus of the cell; no staining was ever observed in the cytoplasm. The nuclear localization of the antigen was determined by staining the section with fluorescent antibody, floating off the coverslip and counter-staining with hematoxylin and eosin or with the Feulgen method. Figs. 4 and 5 are fluorescent antibody and hematoxylin-eosin stains respectively of the same field. Note the exact correspondence of the fluorescence with the hematoxylin stained nuclei (arrows). Figs. 6 and 7 are also fluorescence and hematoxylin-eosin stains of the same field. Note the presence of the antigen in the keratohyaline (*H*) and keratinized layers forming a spike (*K*) and its absence from the proliferating cells (*P*). Fig. 3 also illustrates the nuclear occurrence of the viral antigens (*N*).

*TMCA*<sup>1</sup>—Trimethylcolchicinic acid methyl ether, tartrate derivative, was used in an attempt to modify mitosis and thus possibly to alter the distribution of the antigen in tumors of the wild rabbit. Sixteen mg. per kg. was injected intraperitoneally in 5 ml. of saline, an amount per unit weight which corresponds to ¼ the LD<sub>50</sub> for the mouse (9). Paraffin sections of a biopsy taken 6 hours after injection of the TMCA showed a large number of arrested and abnormal mitotic figures in the papilloma (Fig. 8). It is interesting that the mitotic activity does not occur solely in the germinal layer (*G*) but occurs also several layers above, and some mitoses can even be seen near the kerato-

<sup>1</sup> TMCA, trimethylcolchicinic acid methyl ether.

hyaline layer (*H*). Frozen sections from the same biopsy were stained with the anti-virus fluor and there was no change in the amount or distribution of the viral antigens.

*X-ray Irradiation.*—Friedewald and Anderson (10) have reported that irradiation of papillomas of the wild or domestic rabbit will sometimes give a higher yield of recoverable virus, although this result is highly variable. Using Friedewald's technique, wild rabbit papillomas were irradiated and biopsied 24 hours later. Frozen sections of the irradiated papillomas did not reveal any significant increase in the amount of antigen or any change in the distribution of the antigen upon staining with fluorescent antibody. However, in several sections the antigen was associated with a large nuclear pattern, representing an abnormal distribution of chromatin or possibly chromosomes in some instances. Such a nuclear pattern (*F*) is illustrated in Fig. 9 stained with fluorescein-antibody. Fig. 10 illustrates a comparable abnormal, fragmenting nucleus (*N*) in a paraffin section of the same biopsy. Such nuclear changes were rare, however, and microscopic appearance was otherwise that of a typical papilloma.

*Distribution of Antibodies.*—The possible existence of localized antibodies against the papilloma virus was studied by staining sections with fluorescein-labelled goat antibodies against rabbit globulin. This fluor had been shown to react strongly with rabbit globulin by the gel-diffusion method as well as by fluorescent staining (11). Sections of papillomas when stained with this reagent showed no specific fluorescence in the keratinized, proliferating, or germinal cells, but there was fluorescence in the connective tissues.

*Domestic Rabbit Papillomas.*—The papilloma viral antigens were very difficult to find in the numerous specimens of domestic rabbit papillomas examined. Almost all the sections were completely negative (an excellent control), but about 1 section in 10 showed a typical small localized area of antigen. The specificity of the finding was ascertained by the typical fluorescence, the morphology and the location of the area. The Shope antigen always occurred in the exterior keratin layers (*S*) as is illustrated by Fig. 11. When this and other similar areas were counter-stained with hematoxylin and eosin the fluorescent areas were seen to correspond to nuclei.

#### DISCUSSION

As far as is known to the authors, there has been no previous demonstration of the precise cellular localization of the Shope virus, in our observations found to be exclusively nuclear. It was surprising that practically all the cells in the proliferating layers of the papilloma contained no antigen, for the cells in these layers make the major contribution to the growth of the papilloma. The fact that antibodies were not masking the presence of viral antigen in the proliferating cells was shown by the failure to demonstrate rabbit globulin there. It was thought that viral antigen might exist in such small amounts in that area as to be undetectable with the fluorescent antibody; therefore, TMCA was used to arrest mitosis so that nuclear material, and thus viral antigen, might also be concentrated; but there was failure in the attempts to demonstrate any viral antigen in the mitotic figures of the proliferating layers or even in those near the keratohyaline layer. Treatment with x-ray has been reported to

increase occasionally the yield of Shope virus (10) and it was thought that it might also cause a change in the distribution of the virus. These irradiation experiments were also negative. It must be kept in mind that very minute amounts of Shope viral antigen can be detected by the fluorescent antibody method (*P*, Fig. 3). The staining of the viral antigen is very brilliant, as bright as any of the fluorescent antibody-virus systems studied in our laboratories, including vaccinia virus and Egypt 101 virus (12, 13). Assuming that the fluorescent antibody demonstrates the complete virus, it is reasonably certain that there is little or no complete virus in the proliferating cells, and none is encountered until the keratohyaline layer is approached. Complete virus is present in this layer and in the keratinized layers, and even occurs in the surface layers of the papilloma (*S*, Fig. 3). This finding is consistent with assumptions concerning the transmission of the virus in nature, in which presumably the dried keratin of a tumor is rubbed from a rabbit entering a burrow, and the virus in this dried keratin serves as an inoculum for the next rabbit who sustains an abrasion upon entering (14).

In order to promote the growth of a papilloma the virus presumably stimulates cell division in the proliferating cells, and not in the differentiating cells of the keratinized layers. It appears that Shope viral antigen demonstrable with fluorescent antibody does not accumulate until cellular proliferative activity diminishes and the cells differentiate into the keratohyaline and keratinized layers. It is postulated that virus is present in the germinal and the proliferating cells but exists there in an early stage of development, consisting mainly of nucleic acid and deficient in protein, and therefore non-antigenic and not demonstrable by fluorescent antibody. The nucleic acid moiety of the virus may be infective, and the protein component may provide immunologic specificity and serve to preserve transmissibility. Support of this theory may come from electron microscopic studies in progress, which may enable both early and late stages in virus development to be detected. Bloch *et al.* (15) describe stages in the nuclear development of adenovirus in their tissue culture studies utilizing electron microscopy and histochemical staining procedures. Developmental stages also exist for the virus of human warts (16) and for the virus-like particles associated with the Lucké renal adenocarcinoma (22).

The demonstration by fluorescent antibody of such minute amounts of viral antigen in the papillomas from the domestic rabbit as compared with the wild rabbit papillomas is supported by the ultracentrifugation studies of Beard, Bryan, and Wyckoff (17). These investigators obtained macromolecular nucleoproteins from centrifugates of extracts of papillomas from the wild rabbits in which the amount of the nucleoprotein was proportional to the infectivity. Extracts of papillomas from domestic rabbits gave no similar nucleoprotein product. Furthermore, Kidd (18, 19) in his serological studies found that papillomas in the domestic rabbit contain less specific antigen and produce

less circulating antibody than those from the cottontail. Selbie and Robinson (20) have suggested that the fundamental difference in the nature of the infection in the two species of rabbit is that the lesion in the domestic rabbit is produced with much less multiplication of the virus in the infected cells. The virus can be adapted to serial passage in the domestic rabbit (20, 21), and this can possibly be ascribed to an acquired capacity for increased multiplication in the infected cells (20).

The evidence indicates that there is a much smaller amount of complete virus in the domestic rabbit papillomas, whether demonstrated by infection, centrifugation, serology, or fluorescent antibody. The papillomas of the domestic rabbit apparently do not present as favorable a situation as the cottontail papillomas for the development of complete virus. As was postulated for the cottontail rabbit papillomas it seems probable that there is present in the proliferating cells of the domestic rabbit papillomas a large amount of early stage virus which is not demonstrable by fluorescent antibody. The virus in the domestic rabbit papillomas may for the most part be nucleic acid without a protein coat, and hence without protection against rapid inactivation and not capable of transmission. This protein-deficient virus can be referred to as masked virus.

#### SUMMARY AND CONCLUSIONS

The results obtained by a fluorescent antibody study of the Shope papilloma virus in papillomas of the wild and domestic rabbit are presented.

In the wild rabbit papillomas the viral antigens occurred exclusively in the nucleus and were present in the differentiating cells of the keratohyaline layers and in the keratinized layers. The antigens were not present in the deeper proliferating epithelial cells of the papillomas.

The Shope viral antigens were present in very minute amounts in papillomas of the domestic rabbit, as compared with papillomas of the wild rabbit, and were only detected in the superficial keratinized layers.

It is postulated that virus is present in the nuclei of the proliferating cells of the papillomas of the wild and domestic rabbit but exists there in an early stage of development, consisting mainly of nucleic acid and deficient in protein, therefore non-antigenic and not demonstrable by fluorescent antibody. The nucleic acid moiety of the virus may be infective, and the protein component may provide immunologic specificity and serve to preserve transmissibility. The protein-deficient virus can be referred to as masked virus.

This investigation was supported in part by a research grant from the National Cancer Institute of the National Institutes of Health, Public Health Service, and by grants from the Damon Runyon Memorial Fund and the American Cancer Society, Inc.

It is a pleasure to acknowledge the excellent technical assistance of Dr. Consolacion Carino.

## BIBLIOGRAPHY

1. Mellors, R. C., *Cancer Research*, 1955, **15**, 557.
2. Beard, J. W., *Cancer Research*, 1956, **16**, 279.
3. Shope, R. E., *J. Exp. Med.*, 1933, **58**, 607.
4. Coons, A. H., and Kaplan, M. H., *J. Exp. Med.*, 1950, **91**, 1.
5. Mellors, R. C., and Ortega, L. G., *Am. J. Path.*, 1956, **32**, 455.
6. Noyes, W. F., Southam, C. M., and Mellors, R. C., data to be published.
7. Weller, T. H., and Coons, A. H., *Proc. Soc. Exp. Biol. & Med.*, 1954, **86**, 789.
8. Rous, P., and Beard, J. W., *J. Exp. Med.*, 1934, **60**, 701, 723, 741.
9. Goldberg, B., Ortega, L. G., Goldin, A., Ulloa, G. E., and Schoenback, E. G., *Cancer*, 1950, **3**, 124.
10. Friedewald, W. F., and Anderson, R. S., *J. Exp. Med.*, 1943, **78**, 285.
11. Ortega, L. G., and Mellors, R. C., *J. Exp. Med.*, 1956, **104**, 151.
12. Noyes, W. F., and Watson, B. K., *J. Exp. Med.*, 1955, **102**, 237.
13. Noyes, W. F., *J. Exp. Med.*, 1955, **102**, 243.
14. Oberling, C., *Riddle of Cancer*, New Haven, Yale University Press, 1952.
15. Bloch, D. P., Morgan, C., Godman, G. C., Howe, C., and Rose, H. M., *J. Biophysic. and Biochem. Cytol.*, 1957, **3**, 1.
16. Bloch, D. P., and Godman, G. C., *J. Exp. Med.*, 1956, **105**, 161.
17. Beard, W., Bryan, W. R., and Wyckoff, R. W. G., *J. Infect. Dis.*, 1939, **65**, 43.
18. Kidd, J. G., *J. Exp. Med.*, 1938, **68**, 703.
19. Kidd, J. G., *J. Exp. Med.*, 1938, **68**, 737.
20. Selbie, F. R., and Robinson, R. H. M., *Brit. J. Cancer*, 1948, **2**, 375.
21. Shope, R. E., *Proc. Soc. Exp. Biol. and Med.*, 1935, **32**, 830.
22. Fawcett, D. W., *J. Biophysic. and Biochem. Cytol.*, 1956, **2**, 725.

## EXPLANATION OF PLATES

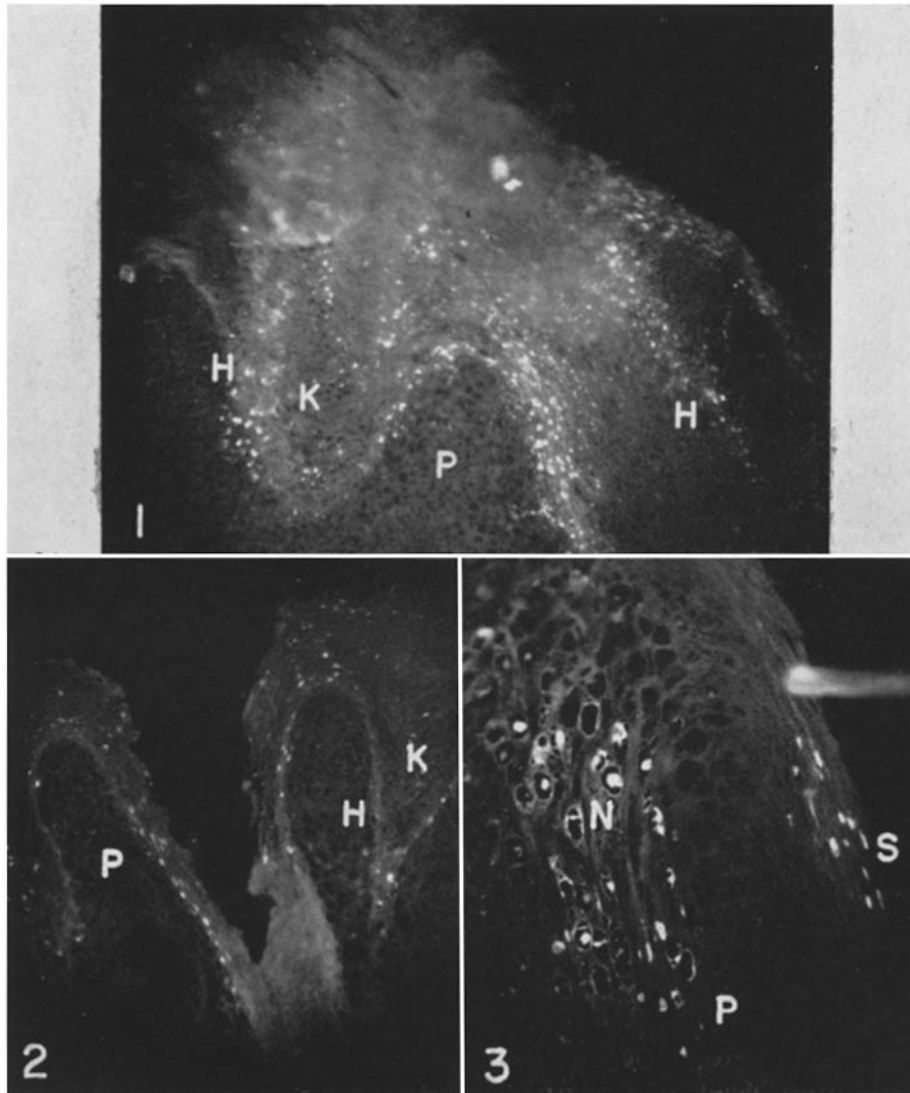
## PLATE 47

FIG. 1. A fluorescence photomicrograph of a frozen section of a wild rabbit papilloma stained with fluorescein-labelled antibody against the Shope papilloma virus. The Shope viral antigens are the numerous, discrete bright white areas restricted to the keratohyaline layer (*H*) and the keratinized layers (*K*). These sites of antigen were yellow-green visually. The keratinized layers also had diffuse blue-white auto-fluorescence which appears grey at the top of this illustration.  $\times 60$ .

FIG. 2. A fluorescence photomicrograph of another wild rabbit papilloma showing proliferating (*P*), keratohyaline (*H*), and keratinized layers (*K*). Viral antigen, which appears as bright white localized areas, is scattered sparsely in the latter two layers. Comparison with Fig. 1 illustrates the variation in the amount of antigen that can occur in two papillomas of the cottontail rabbit.  $\times 60$ .

FIG. 3. A higher power fluorescence photograph of a wild rabbit papilloma which illustrates the fact that the viral antigen is restricted to the nucleus of the cell (*N*). The antigen is also present in the surface keratinized layer (*S*). The bright horizontal line is an artifact.  $\times 400$ .



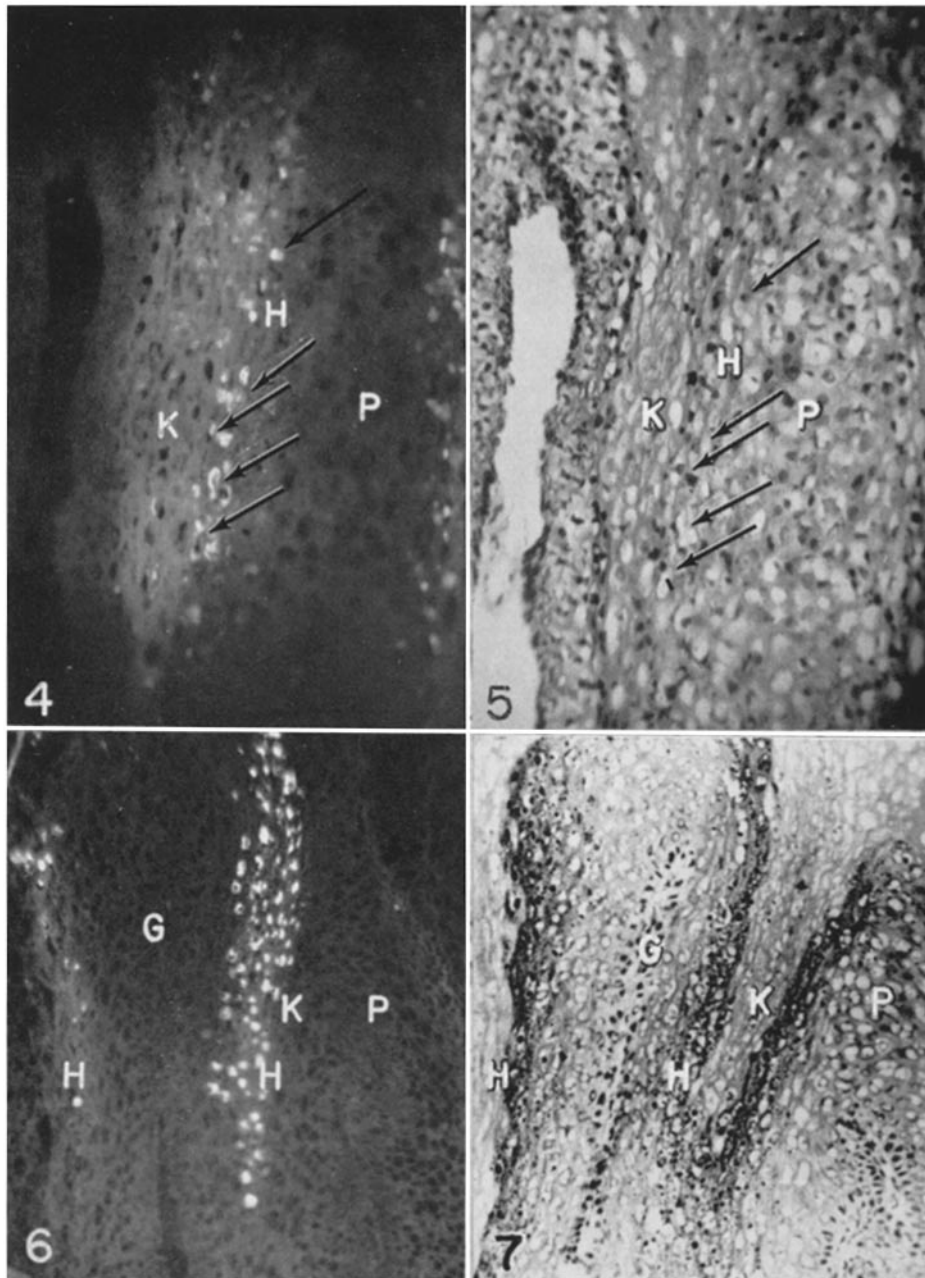


(Noyes and Mellors: Antigens of Shope papilloma virus)

PLATE 48

FIGS. 4 and 5. A fluorescent antibody stain for viral antigen and hematoxylin-eosin stain respectively of the same field of a section of a wild rabbit papilloma. Note the exact correspondence of the fluorescence with the hematoxylin-stained nuclei (arrows). The antigen is present in highest concentration in the keratohyaline zone (*H*) and is not present in the proliferating cells (*P*).  $\times 165$ .

FIGS. 6 and 7. A fluorescence and hematoxylin-eosin stain respectively of the same field of a wild rabbit papilloma. The antigen is present in the keratohyaline zone (*H*) and also the keratinized spike (*K*). The antigen is absent from the proliferating (*P*) and germinal cells (*G*).  $\times 122$ .



(Noyes and Mellors: Antigens of Shope papilloma virus)

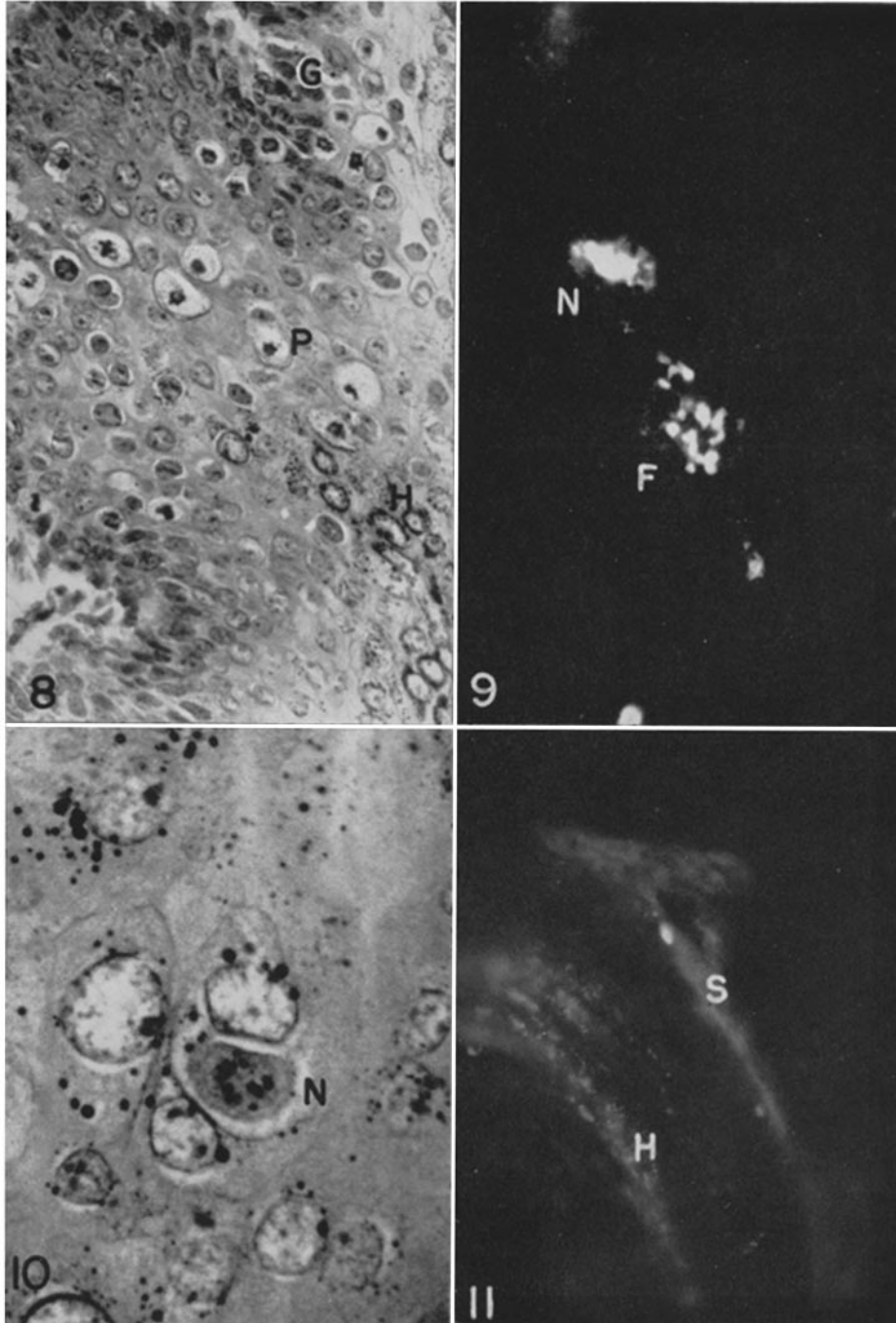
PLATE 49

FIG. 8. A paraffin section of a wild rabbit papilloma 24 hours after treatment with trimethylcolchicinic acid, showing mitotic figures in the proliferating layers (*P*) almost up to the keratohyaline layer (*H*). Hematoxylin-eosin stain.  $\times 190$ .

FIG. 9. A fluorescence photomicrograph of an irradiated wild rabbit papilloma illustrating the association of Shope antigen with nuclear fragments (*F*) and with concentrated nuclear material (*N*).  $\times 800$ .

FIG. 10. A paraffin section of the same irradiated papilloma as illustrated in FIG. 9. A nucleus comparable to the one stained with fluorescent antibody is seen in the center of the field (*N*). Hematoxylin-eosin stain.  $\times 800$ .

FIG. 11. A fluorescence photograph of a domestic rabbit papilloma stained with fluorescent antibody against the Shope virus. A small localized area of viral antigen is seen in the surface keratinized layer (*S*). The autofluorescence of the keratohyaline granules can be seen in the curving grey band (*H*).  $\times 400$ .



(Noyes and Mellors: Antigens of Shope papilloma virus)