

STUDIES OF DELAYED HYPERSENSITIVITY IN VITRO
II. DELAYED HYPERSENSITIVITY IN EXPERIMENTAL MUMPS VIRUS INFECTIONS*

By LOWELL A. GLASGOW AND HERBERT R. MORGAN, M.D.

(From the M. Herbert Eisenhart Tissue Culture Laboratory of the Department of Bacteriology, The University of Rochester School of Medicine and Dentistry, Rochester, New York)

PLATE 4

(Received for publication, March 6, 1957)

The state of delayed hypersensitivity following infections with the tubercle bacillus, usually demonstrated by the delayed skin reaction that develops after the intradermal injection of tuberculin, was shown by Rich and Lewis (1) to be manifested *in vitro* by a cytotoxic effect of tuberculoproteins on cells of tissue cultures prepared with spleen fragments from infected experimental animals. Other investigators (2-4) have confirmed these observations of cytotoxicity and the reaction has been shown to be so sensitive that tuberculoproteins in concentrations as low as 1 gamma/ml. will produce this effect in tissue cultures (5). The role of this hypersensitivity reaction in tuberculous infections has been discussed by Rich (6), and he concludes that the hypersensitive state is decidedly deleterious to the host in some instances.

Since it has been shown that mumps virus infections in man are accompanied by the development of a state of delayed hypersensitivity, as evidenced by a delayed skin reaction following injection of heat-inactivated virus preparations (7, 8), it was of interest to study the *in vitro* aspect of this hypersensitivity in experimental infections in guinea pigs, using tissue culture methods (4) which permit observation and evaluation of the effects of mumps viral antigen on hypersensitive cells.

Materials and Methods

Virus.—The egg-adapted strain of mumps virus used was obtained from Dr. John F. Enders. Infective virus was prepared for use in these experiments by the inoculation of 10^{-2} dilutions of seed virus into the amniotic sacs of 7-day chick embryos incubated at 37°C. On the 5th day after inoculation the eggs were refrigerated for 12 hours and the amniotic and allantoic fluids were harvested. The quantity of virus in the egg fluids was determined by the hemagglutination method.

The virus was concentrated by centrifugation of the fluids at 2500 R.P.M. for 10 to 15

* Supported by a research grant from The Lilly Research Laboratories, Eli Lilly and Company, Indianapolis.

minutes to remove particulate egg matter, following which the supernatant fluid was then centrifuged in a Spinco ultracentrifuge at 30,000 R.P.M. for 20 minutes to sediment the virus. The virus was resuspended in Hanks's (9) balanced salt solution (BSS) buffered at a pH of 6.8-7.2, and frozen for storage at -70°C .

The antigen employed in these studies was prepared from the concentrated fluids by inactivation in a water bath at 56°C . for 25 minutes.

Viral Infection of Guinea Pigs.—Guinea pigs weighing at least 250 gm. were infected with mumps virus by 2 routes. Following ether anesthesia, the eye was immobilized and 0.03 ml. of the virus-containing fluid was injected into the anterior chamber with a tuberculin syringe, and 0.1 ml. of the virus fluid was also dropped into the nasal passages of the animal.

Skin Tests.—Four to 6 weeks after infection, the guinea pigs were skin-tested with the mumps virus antigen prepared in this laboratory, a commercial antigen,¹ and an egg-fluid control.

The abdomens of the guinea pigs were shaved and 0.1 ml. of each of the test materials was injected intradermally. The reaction was determined by measurement of the area of induration which developed at the site of injection after 24 and 48 hours. Non-infected control animals were skin-tested with each group of experimental animals.

Tissue Cultures.—The tissue culture method was the same as that outlined by Gangarosa *et al.* (4). The experimental animal was sacrificed, the spleen removed under sterile conditions, and the tissue minced with corneal scissors in a small test tube with BSS. Fragments about 1 mm.³ were placed on a rooster plasma coagulum in T-9 flasks (Kontek Glass Co., Vineland, New Jersey.) Two ml. of medium was added to each flask. The flasks were sealed with a silicone stopper and incubated at 37°C .

The medium used in these experiments consisted of 60 per cent BSS, 30 per cent beef serum ultrafiltrate, 10 per cent heated guinea pig serum, 0.05 to 0.1 mg./ml. soybean trypsin inhibitor (General Biochemicals, Inc., Chagrin Falls, Ohio), 150 units/ml. of penicillin, and 100 gamma/ml. of streptomycin.

Approximately 45 fragments were included in each test group and mumps virus was added 24 hours after preparation of the tissue culture. Evaluation of the cytotoxic effects on the splenic macrophages was made in the manner described by Gangarosa *et al.* (4). Observations of cell morphology and a count of the number of macrophages migrating from each fragment were made at 24-hour intervals during the course of the experiments. Photomicrographs were made to record the nature of the cytotoxic effects.

EXPERIMENTAL

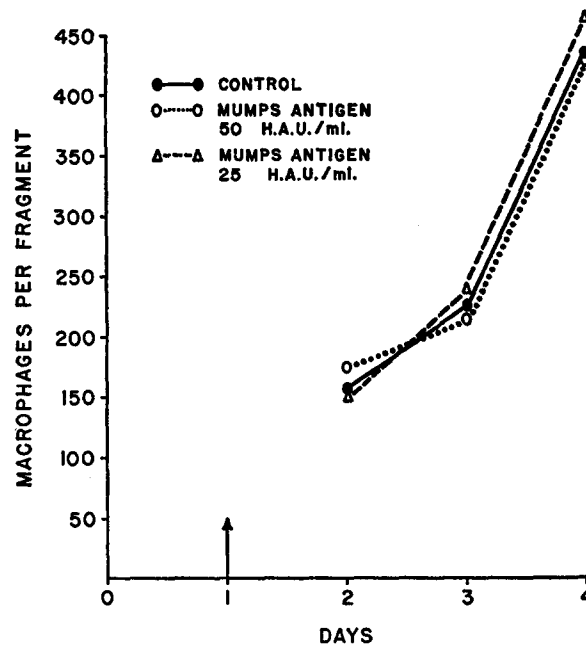
Experimental Mumps Virus Infections in Guinea Pigs.—After infection, the ocular reactions in guinea pigs were observed during the course of the disease in a manner similar to that previously reported (10-12), in which the eye was examined daily and the condition of the cornea, iris, and conjunctiva recorded. Twenty-four hours after inoculation, a mild diffuse infiltration or clouding of the cornea was seen, accompanied by moderate injection of the pericorneal vessels and a mild conjunctivitis. The pupil was commonly miotic. During the next 24 hours, the reaction was intensified. The cornea became markedly cloudy and the iris and pupil were not visible. The dilatation of the pericorneal vessels increased as did the injection of the conjunctiva. Exophthalmia was

¹ Obtained through the courtesy of Lederle Laboratories Division, American Cyanamid Company, Pearl River, N. Y.

marked in many of the infections. The reaction tended to remain at this state for 48 to 72 hours and then gradually disappeared. Depending upon individual variation, the infections tended to clear by the 10th to 14th day.

Virus could be recovered from the anterior chamber of the guinea pig's eye up to 96 hours after infection by removal of fluid and inoculation into eggs.

The immunological response of the guinea pigs to the injection of virus was followed by determination of the hemagglutination inhibition titer of serum



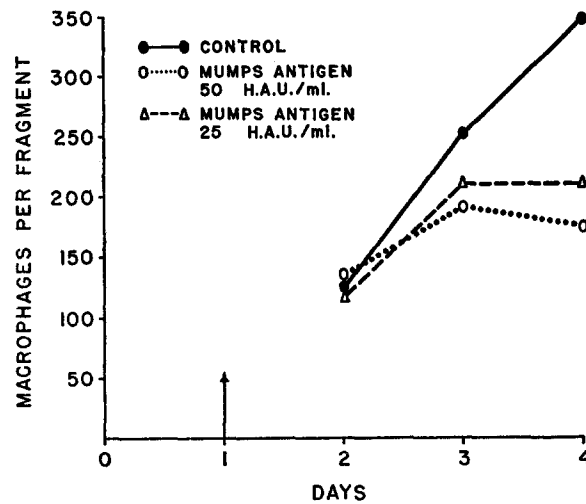
TEXT-FIG. 1. Response of macrophages from splenic explants of a normal, mumps-skin-test-negative guinea pig. Mumps antigen was added at 24 hours. H.A.U. = hemagglutinating units of virus.

samples obtained by intracardiac puncture at varying intervals from 12 hours to 7 weeks after inoculation with mumps virus. Titers greater than 1:8 appeared after 72 hours with the maximum titers of 1:512 being present at 3 weeks. A gradual decline in antibody titer occurred during the following 4-week period.

Delayed Skin Test Reactions.—Twenty-five guinea pigs were inoculated with mumps virus during the course of these experiments. The development of delayed hypersensitivity was determined by intradermal injection of skin test antigens. Twelve of the 25 guinea pigs developed positive skin tests with areas of induration ranging from 4 to 8 mm. with antigen prepared in this laboratory. Only 2 of these animals developed a positive reaction in response to the injection

of the less potent commercial preparation. No control animals developed positive reactions to any of the preparations used for the skin tests.

Studies of Cytotoxicity of Mumps Virus on Splenic Tissues in Vitro.—The possible action of the mumps viral antigen on cells of uninfected animals was investigated by the study of the effect of the antigen on the splenic tissues from normal, skin-test-negative guinea pigs. The mumps antigen had no adverse effect, either qualitatively or quantitatively, upon the macrophages migrating from the tissue explants (Text-fig. 1 and Fig. 1).



TEXT-FIG. 2. Response of macrophages from splenic explants of a mumps-skin-test-positive guinea pig. Mumps antigen was added at 24 hours. H.A.U. = hemagglutinating units of virus.

An *in vitro* cytotoxicity of the delayed hypersensitive type was shown to occur with splenic tissues of guinea pigs infected with mumps virus at the time they had positive skin tests (*i.e.*, 4 to 6 weeks after infection). The cells migrating from splenic tissue explants from mumps-infected guinea pigs which had developed a positive skin test were markedly altered by the presence of mumps antigen. Migration of macrophages was decreased and cells which did migrate manifested numerous and progressive toxic changes eventually leading to the destruction of a large number of cells. On the 2nd and 3rd days, after addition of the mumps antigen, there was a marked quantitative decrease in the number of cells in the test groups as compared with the control flasks (Text-fig. 2). The qualitative changes observed included swelling of cells, marked vacuolization (Figs. 2 and 3), clumping of groups of cells with loss of cell boundaries and formation of large giant cells, and finally disintegration of these cells.

DISCUSSION

Infections with mumps virus induce a state of delayed hypersensitivity in the host as indicated by the delayed skin test reaction that develops following the intradermal injection of heat-inactivated virus (7, 8). If this hypersensitive state is to have significance in the pathogenesis of mumps viral infections, it would have to manifest itself during the phase of clinical disease. This appears to be the case in man, since Habel (13), using a mumps viral antigen, showed that 84 per cent of 38 cases showed a positive skin test within 5 days of the onset of clinical symptoms. Furthermore, it is likely that local hypersensitivity in an organ where the virus is multiplying might precede the appearance of generalized dermal hypersensitivity. Other immunological reactions also develop early in mumps viral infections, since Stokes *et al.* (14) have observed that circulating antibodies to mumps virus are present when clinical symptoms develop in experimental infections with mumps virus in human beings, and the development of the complications in mumps involving several organs often occurs in the period after onset of the parotitis when the antibody titers in the blood are significantly elevated. Thus, immunological reactions, including those of hypersensitivity, develop early in mumps infection and at a time when the clinical symptoms are becoming more severe.

It seems reasonable, therefore, to consider that the hypersensitive state in mumps infection might be related to the pathogenesis of the disease. This study indicates that in experimental mumps infections this delayed hypersensitivity is associated with a cytotoxic response to viral antigen which can be observed directly, and thus a mechanism for cell damage as a result of the state of hypersensitivity exists. The pitfalls of extrapolating from the *in vitro* experimental situation to that which obtains naturally *in vivo* are recognized. However, the parallelism that exists between the *in vitro* cytotoxic manifestations of the hypersensitive state in mumps viral infections and that in experimental (1) or natural (4) infections with the tubercle bacillus lends support to the idea that the hypersensitive state in mumps infection may be related to pathogenesis, since it is believed that hypersensitivity plays a part in the pathogenesis of experimental and natural infections caused by the tubercle bacillus (6).

It might be suggested that there is a formation of cellular antibodies in mumps infection and that their subsequent combination with mumps virus antigen *in vivo* results in injury to the host tissues. Thus, the cellular damage caused by the mumps virus during natural infection might be a result of two processes: (a) the primary destruction of cells through direct cytolysis by virus (15, 16); and (b) a secondary cytotoxic effect produced by mumps viral antigen on hypersensitive cells. With the activation of the immunological mechanisms of the host, the latter reaction would be superimposed on the former, thus contributing to the symptomatic manifestations of the disease.

SUMMARY

Guinea pigs experimentally infected with mumps virus develop a delayed, hypersensitive skin reaction following the intradermal injection of heat-inactivated mumps virus. This *in vivo* hypersensitivity is accompanied by a state of cellular hypersensitivity which can be demonstrated *in vitro* by the addition of mumps viral antigen to cultures of splenic macrophages, following which they become less motile and undergo lysis. These observations support the hypothesis that the state of hypersensitivity which develops early in mumps virus infections may have a role in the pathogenesis of the disease.

BIBLIOGRAPHY

1. Rich, A. R., and Lewis, M. R., The nature of allergy in tuberculosis as revealed by tissue culture studies, *Bull. Johns Hopkins Hosp.*, 1932, **50**, 115.
2. Moen, J. K., and Swift, H. F., Tissue culture studies on bacterial hypersensitivity. I. Tuberculin sensitive tissues, *J. Exp. Med.*, 1936, **64**, 339.
3. Moen, J. K., Tissue culture studies on bacterial hypersensitivity. III. The persistence *in vitro* of the inherent sensitivity to tuberculin of cells from tuberculous animals, *J. Exp. Med.*, 1936, **64**, 943.
4. Gangarosa, E. J., Inglefield, J. T., Thomas, C. G. A., and Morgan, H. R., Studies on hypersensitivity of human tissue *in vitro*. I. Tuberculin hypersensitivity, *J. Exp. Med.*, 1955, **102**, 425.
5. Shea, J. D., and Morgan, H. R., Studies on delayed hypersensitivity *in vitro*. I. Effects of tuberculoproteins on tissue from sensitive guinea pigs, *Proc. Soc. Exp. Biol. and Med.*, in press.
6. Rich, A. R., Pathogenesis of Tuberculosis, Springfield, Charles C. Thomas, 1946.
7. Enders, J. F., Kane, L. W., Maris, E. P., and Stokes, J., Jr., Immunity in mumps. The correlation of the presence of dermal hypersensitivity and resistance to mumps, *J. Exp. Med.*, 1946, **84**, 341.
8. Enders, J. F., Observations on immunity in mumps, *Ann. Int. Med.*, 1943, **18**, 1015.
9. Hanks, J. R., and Wallace, R. E., Relation of oxygen and temperature in the preservation of tissues by refrigeration, *Proc. Soc. Exp. Biol. and Med.*, 1949, **71**, 196.
10. Bolin, V. S., and Leymaster, G. R., Use of guinea pig eye in study of intraocular infections produced by mumps virus, *Proc. Soc. Exp. Biol. and Med.*, 1952, **79**, 7.
11. Bolin, V. S., Anderson, J. A., and Leymaster, G. R., Experimental intraocular infection of guinea pigs with mumps virus, *Proc. Soc. Exp. Biol. and Med.*, 1950, **75**, 166.
12. Kirber, H. P., and Kirber, M. W., Experimental intraocular infection with mumps virus, *Arch. Ophthalm.*, Chicago, 1954, **51**, 832.
13. Habel, K., Immunity response in mumps with complications, *J. Lab. and Clin. Med.*, 1952, **39**, 785.

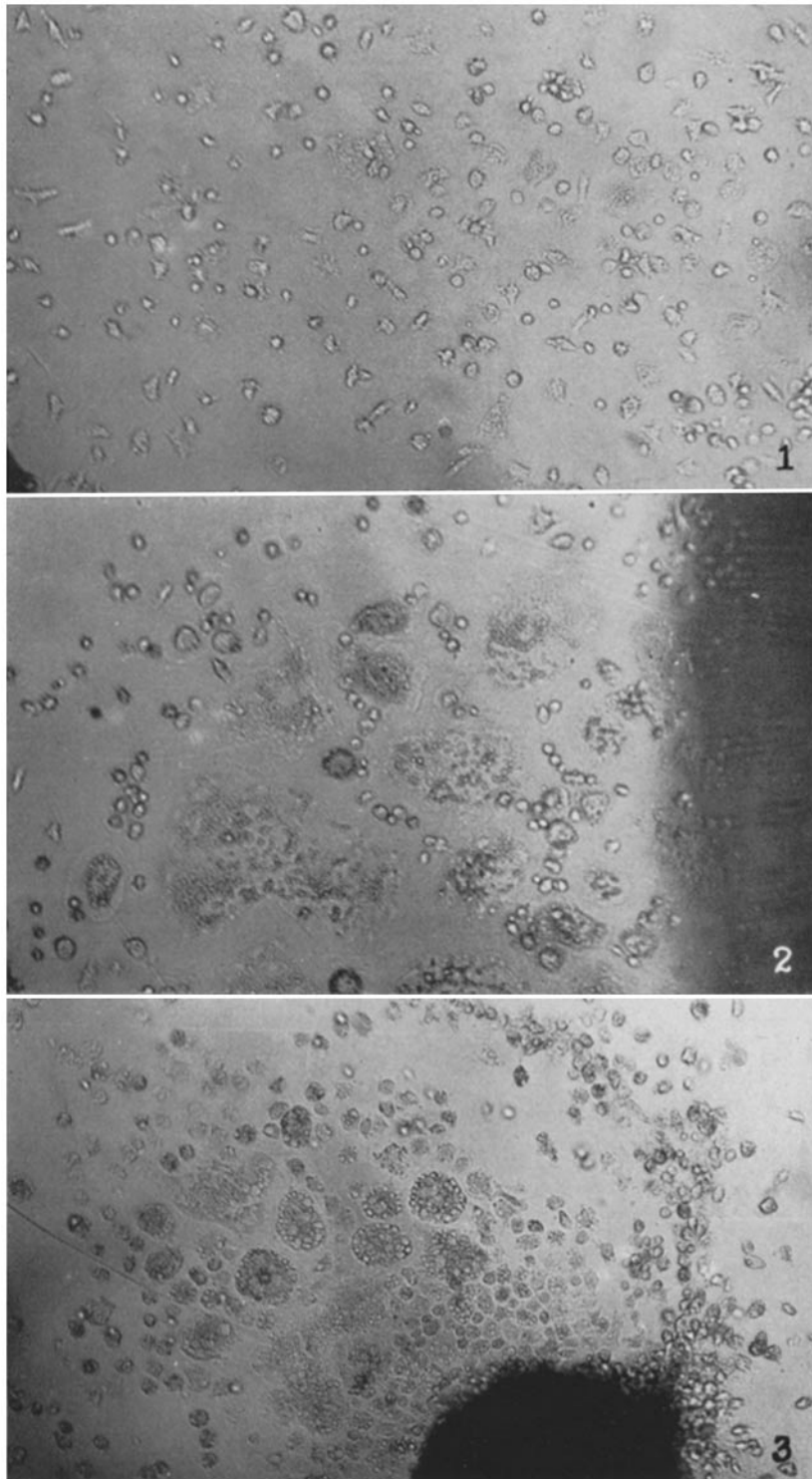
14. Stokes, J., Jr., Enders, J. R., Maris, E. P., and Kane, L. W., Immunity in mumps. VI. Experiments on the vaccination of human beings with formalized mumps virus, *J. Exp. Med.*, 1946, **84**, 407.
15. Morgan, H. R., Enders, J. F., and Wagley, P. F., A hemolysin associated with the mumps virus, *J. Exp. Med.*, 1948, **88**, 503.
16. Henle, G., Deinhardt, F., and Girardi, A., Cytolytic effects of mumps virus in tissue cultures of epithelial cells, *Proc. Soc. Exp. Biol. and Med.*, 1954, **87**, 386.

EXPLANATION OF PLATE 4

FIG. 1. Photomicrograph of spleen from skin-test-negative guinea pig grown in the presence of mumps virus antigen 72 hours after addition of antigen. $\times 100$.

FIG. 2. Photomicrograph of spleen from skin-test-positive guinea pig grown in the presence of mumps virus antigen 72 hours after addition of antigen. $\times 100$.

FIG. 3. Photomicrograph of spleen from skin-test-positive guinea pig grown in the presence of mumps virus antigen 72 hours after addition of antigen. $\times 100$.



(Glasgow and Morgan: *In vitro* delayed hypersensitivity)