

OBSERVATIONS ON ATTEMPTS TO PRODUCE ACUTE DISSEMINATED ENCEPHALOMYELITIS IN MONKEYS

By THOMAS M. RIVERS, M.D., D. H. SPRUNT, M.D., AND G. P. BERRY, M.D.

(From the Hospital of The Rockefeller Institute for Medical Research)

PLATES 1 TO 3

(Received for publication, February 21, 1933)

During convalescence from certain diseases, notably smallpox, vaccinia, and measles, and during or following vaccination against rabies, an occasional patient develops symptoms and signs referable to the central nervous system. A careful study (1-3) of the brains and cords of individuals who have died because of such involvement of the nervous system has revealed a characteristic pathological picture, acute disseminated encephalomyelitis, of which perivascular demyelination is a striking feature. The etiology of this malady is unknown in spite of the fact that considerable experimental work has been done to disclose it. Inasmuch as vaccine virus is suitable for a variety of experiments, many of the investigations (4-10) have dealt with vaccinal infections of the brain in rabbits and monkeys. At present, as a result of these investigations two main views are held regarding the relation of vaccine virus to postvaccinal encephalomyelitis, namely, (1) that it is the etiological agent and can induce the disease under experimental conditions, (2) that there is no clinical, pathological, or experimental evidence to show that it is directly responsible for the malady. In view of this difference of opinion, we decided to conduct some experiments on vaccinal infections in monkeys in the hope of obtaining information concerning the effect of the active agent on the central nervous system. We made no effort to repeat any work that had been previously reported, yet some of our control animals were handled in a manner similar to that employed by other investigators. Consequently, our results in many instances are comparable with those already recorded in the literature.

EXPERIMENTAL

In the work described at this time four lines of investigation were followed. In the first place, an effort was made to determine what pathological changes are induced by vaccine virus in the brains of immune, partially immune, and normal monkeys. Then it seemed advisable to ascertain whether a testicular extract, Reynals' factor (11, 12), is capable of inducing vaccine virus to produce an acute disseminated encephalomyelitis in monkeys. Furthermore, inasmuch as it has been stated (13, 14) that repeated injections of normal brain tissues cause paralysis in rabbits, an attempt was made to determine whether inoculations of such tissues in monkeys would cause an acute disseminated encephalomyelitis. Finally, it seemed of interest to find out whether vaccine virus would cause an acute disseminated encephalomyelitis in monkeys that had received repeated injections of emulsions and extracts of normal rabbit brains.

Methods and Materials

Monkeys.—All monkeys (*Macacus rhesus*) used in the experiments were healthy and approximately half-grown.

Virus.—The dermal strain of vaccine virus employed was originally obtained from the New York City Board of Health (15). It has been freed from bacteria and has been propagated in rabbits and by means of cultivation *in vitro* in a mixture of viable chick embryo tissue and Tyrode's solution (15). It follows that none of the results reported in this paper can be ascribed to the action of bacterial contaminants. When intracranial injections of vaccine virus were made, the monkeys in the majority of instances received known amounts of the same testicular virus emulsion, No. 3285, preserved in 50 per cent glycerol, the titer of which in rabbits was 1-1,000,000. Culture virus was usually employed for dermal inoculations of the monkeys. The reason for the use of virus propagated in chick embryo tissue will be apparent when the experiments are described in detail.

Fresh Brain Emulsions.—The fresh brain emulsions injected into monkeys were prepared in the following manner: One normal rabbit brain was thoroughly ground with alundum in a mortar. 40 cc. of Locke's solution and 10 cc. of 95 per cent alcohol were added. Then the emulsion was centrifuged at speed 5 for 3 minutes. 3-5 cc. of the supernatant material were injected into each monkey. Fresh emulsions were made for each set of inoculations. The sterility of the materials employed was tested by cultures.

Brain Extracts.—The brains of 4 rabbits that had been exsanguinated were removed and thoroughly ground in a mortar, without an abrasive. This material was then placed in a large flask and extracted for 4 days at 37°C. with 300 cc. of

95 per cent alcohol. The alcohol was drawn off and saved. Then 300 cc. of ether were added to the brain tissue and extraction was allowed to take place at 37°C. for 6 days. The ether was removed and allowed to evaporate under the influence of heat and vacuum until only 20 cc. of a "soapy-looking" material remained. To this material were added the 300 cc. of alcohol with which the first extraction was made. The "soapy-looking" material went into solution. By means of heat (70°C.) and vacuum the volume of the mixed extracts was reduced to 150 cc. The concentrated alcohol-ether extract was stored in a cold room kept at 0°C. At this temperature a white waxy sediment appeared in the extract; but when the temperature of the extract was raised to 70 or 80°C., the sediment again went into solution. For the injection of each monkey 1 cc. of the alcohol-ether extract heated to 70–80°C. was added to 3 or 4 cc. of sterile distilled water. The resulting mixture consisted of a milky-looking fluid with the appearance of a Wassermann antigen. All of the prepared materials were tested for the presence of bacteria by means of cultures.

Injections of Brain Emulsions and Extracts.—The brain emulsions and extracts were repeatedly injected intramuscularly in monkeys, the animals receiving 3 inoculations a week consisting either of 2 emulsions and 1 extract or of 2 extracts and 1 emulsion.

Testicular Extract (Reynals' Factor).—The Reynals' factor used in the experiments consisted of a bacteria-free Berkefeld N filtrate of a distilled water (15 cc.) extract of desiccated testicular tissue (7.5 gm.).

Autopsies.—Complete autopsies were performed on all monkeys that died or that were sacrificed. Cultures to test the sterility of all brains were made.

Stains.—Sections from different parts of the cerebrum, cerebellum, pons, and cord were stained with hematoxylin and eosin, according to Marchi's method, and according to Kulschitzky-Wolter's modification of Weigert's myelin sheath stain.

Effect of Vaccine Virus on the Normal, the Partially Immune, and the Immune Brain of the Monkey

It has been stated (9) that vaccine virus introduced into the cisterna magna of a normal monkey produces a disease somewhat similar to postvaccinal encephalomyelitis in man. Furthermore, it has been suggested (16) that the acute disseminated encephalomyelitis following certain virus maladies including vaccinia is an hyperergic phenomenon (16). In regard to vaccinia, such an hypothesis is easily tested by experimentation in animals. Consequently, we decided to see what clinical and pathological manifestations are induced by the introduction of vaccine virus into the cisterns of monkeys during the process of immunization against the active agent. Inasmuch as normal monkeys were used as controls, an opportunity was also afforded to study the effect of the virus on the brains of non-immune animals.

The 9 experiments performed to determine the effect that vaccine virus has on the brains of normal, partially immune, and immune monkeys have been divided into 2 groups. The animals of the first group received intracranially 1 cc. of a 1-20 dilution of a rabbit testicular virus, while those of the second group received 1 cc. of a 1-5 dilution of the same virus.

Group I.—Group I consisted of 5 experiments in which 13 monkeys were used, 5 of which were controls. 8 monkeys were inoculated on the skin with vaccine virus that had been cultivated in a mixture of chick embryo tissue and Tyrode's solution. The virus was smeared on 2 large areas of scarified skin. On the 2nd, 4th, 6th, and 10th days after the dermal inoculations either 1 or 2 of the monkeys together with a control received intracisternally 1 cc. each of 1-20 dilution of a rabbit testicular vaccine virus, No. 3285. In addition to these animals, 1 monkey dermally vaccinated 6 days previously and 1 normal monkey received 1 cc. each of the testicular virus in the right parietal lobe. All of the control animals died of a meningitis. The control monkey that received the virus in the right parietal lobe also had a partial paralysis of the left arm and leg. The 2 monkeys that had been vaccinated 2 days prior to the cisternal inoculations died of a meningitis similar to that of the controls. The 2 monkeys that had been vaccinated 4 days prior to the cisternal inoculations had a mild meningitis from which they promptly recovered. The animals vaccinated 6 and 10 days prior to the cisternal inoculations showed no clinical evidences of cerebral involvement. None of the test and control animals showed any manifestations suggestive of an acute disseminated encephalomyelitis. The results of these experiments are summarized in Table I.

Group II.—The monkeys in Group I vaccinated on the skin developed a refractory state to the cisternal inoculations of a 1-20 dilution of the testicular virus so rapidly that we decided to do another series of experiments in which 1-5 dilutions of the same virus emulsion were employed. This set of 4 experiments represents Group II in which 8 monkeys were used. 4 monkeys were vaccinated on the skin with culture virus similar to that used for the animals in Group I. On the 5th, 7th, 10th, and 12th days after vaccination, 1 vaccinated and 1 control monkey received intracisternally 1 cc. each of a 1-5 dilution of testicular virus, No. 3285. All of the control animals died of a meningitis. The monkeys that had been vaccinated 5 and 7 days prior to the cisternal inoculations also died of a meningitis similar to that of the controls. The monkey that had been vaccinated 10 days prior to the cisternal inoculation developed a mild meningitis from which it promptly recovered, while the one vaccinated 12 days prior showed no evidences of cerebral involvement. None of the animals developed signs suggestive of an acute disseminated encephalomyelitis. The results of the experiments are summarized in Table II.

Pathology.—The pathological findings in the brains of the monkeys that died following the cisternal inoculations of vaccine virus consisted of a non-purulent

meningitis most intense around the pons, cerebellum, and cord. A slight amount of perivascular infiltration and glial reaction was seen in the superficial portions of the brain. The response of the partially immune brains to the infection differed

TABLE I
Summary of Experiments in Which Each Monkey Received Intracranially 1 Cc. of a 1-20 Dilution of a Rabbit Testicular Vaccine Virus, No. 3285

Experiment No.	Monkey No.	No. of days between dermal vaccination and intracranial inoculation	Site of intracranial inoculation	Result	Remarks
I	1	2	Cisterna magna	Died, 5 days	Signs of meningitis
	2	2	" "	" 6 "	" " "
	3	No dermal vaccination	" "	" 5 "	" " "
II	4	4	" "	Survived	Signs of a mild meningitis
	5	4	" "	"	" "
	6	No dermal vaccination	" "	Died, 6 days	Signs of meningitis
III	7	6	Right parietal lobe	Survived	No signs of cerebral involvement
	8	No dermal vaccination	" "	Died, 6 days	Signs of meningitis, weakness in left leg and arm
IV	9	6	Cisterna magna	Survived	No signs of cerebral involvement
	10	No dermal vaccination	" "	Died, 8 days	Signs of meningitis
V	11	10	" "	Survived	No signs of cerebral involvement
	12	10	" "	"	" "
	13	No dermal vaccination	" "	Died, 6 days	Signs of meningitis

in no obvious way from that of the normal brains. In no instance was an acute disseminated encephalomyelitis with perivascular demyelination encountered. Figs. 1-4 portray the pathology of vaccinal meningitis and encephalitis in monkeys.

The results of the experiments described above and summarized in Tables I and II indicate that the brain of a vaccinated monkey rapidly

becomes refractory to the virus, probably just as rapidly as does the skin. Furthermore, it seems evident that vaccine virus injected intracranially in monkeys produces a meningitis accompanied by a mild superficial encephalitis, and not an acute disseminated encephalomyelitis with perivascular demyelination.

TABLE II

Summary of Experiments in Which Each Monkey Received Intracranially 1 Cc. of a 1-5 Dilution of a Rabbit Testicular Vaccine Virus, No. 3285

Experiment No.	Monkey No.	No. of days between dermal vaccination and intracranial inoculation	Site of intracranial inoculation	Result	Remarks
VI	14	5	Cisterna magna	Died, 3 days	Signs of meningitis
	15	No dermal vaccination	" "	" 5 "	" " "
VII	16	7	" "	" 4 "	" " "
	17	No dermal vaccination	" "	" 4 "	" " "
VIII	18	10	" "	Survived	Signs of a mild meningitis
	19	No dermal vaccination	" "	Died, 3 days	Signs of meningitis
IX	20	12	" "	Survived	No signs of cerebral involvement
	21	No dermal vaccination	" "	Died, 5 days	Signs of meningitis

Effect of Testicular Extracts (Reynals' Factor) on Vaccinal Infections in the Brains of Monkeys

It has been shown (11, 12) that testicular extracts in some manner enhance the action of vaccine virus. In view of this fact, we decided to determine whether by means of such an extract vaccine virus could be induced to cause an acute disseminated encephalomyelitis in monkeys.

Experiment X.—In this experiment we attempted to find out (1) whether a testicular extract injected into the cistern of a monkey would cause vaccine virus placed on the skin of the thorax to invade the brain and (2) whether a mixture of

testicular extract and vaccine virus injected into the cistern of a monkey vaccinated on the skin 3 days previously would produce a marked encephalitis as well as a meningitis.

Monkey 22 received intracisternally 1 cc. of Reynals' factor and showed no signs of cerebral involvement. Monkey 23 was vaccinated on the skin with culture virus. 2 and 7 days after the dermal vaccination the animal received intracisternally 1 cc. of Reynals' factor and showed no signs of cerebral involvement. Monkey 24 was vaccinated on the skin with culture virus and 3 days later received intracisternally a mixture of a 0.5 cc. of Reynals' factor and a 0.5 cc. of a 1-20 dilution of testicular virus, No. 3285. The animal developed a stiff neck, ataxia, and spasticity, and was sacrificed 7 days after the cisternal inoculation. Sections of the brain and cord revealed pictures similar to those described earlier in the paper. Monkey 25 received intracisternally a mixture of a 0.5 cc. of Reynals' factor and a 0.5 cc. of a 1-20 dilution of testicular virus, No. 3285. The animal developed a stiff neck, ataxia, and weakness of the arms, and was sacrificed when found moribund on the 6th day after inoculation. Sections of the brain and cord revealed pictures similar to those described earlier in the paper.

The evidence obtained from Experiment X indicated that we would be unable by means of Reynals' factor and vaccine virus to produce an acute disseminated encephalomyelitis in monkeys. Consequently we pursued the matter no further.

Effect in Monkeys of Repeated Injections of Emulsions and Extracts of Normal Rabbit Brains

During antirabic vaccination an occasional patient develops signs and symptoms of involvement of the central nervous system (17, 18). Some of these patients die and at autopsy a myelitis or an encephalitis is found. In many instances, however, the meager descriptions of the pathological changes in the brain and cord leave one in doubt as to their nature. Nevertheless, sufficiently accurate and complete descriptions (18-20) have been made to indicate that in certain instances the lesions are similar to those seen in postvaccinal encephalomyelitis. The cause of this rare complication of antirabic vaccination is unknown. Certain workers have suggested, however, that it is produced by the repeated injections of brain or cord tissues in the antirabic vaccine (13, 18). Indeed, several workers (13) believe that they have produced the disease experimentally in rabbits by means of repeated injections of normal brain tissues. Nevertheless, Hurst (14) recently found that no obvious pathological changes were present in the brains

and cords of rabbits that became paralyzed while receiving repeated injections of normal brain tissues. Inasmuch as monkeys had not been used for this type of work, we decided to find out what effect repeated injections of emulsions and extracts of normal rabbit brains would have on such animals.

Experiment XI.—8 healthy half-grown monkeys (*Macacus rhesus*) received repeated inoculations (3 a week) of emulsions and extracts of normal rabbit brains. The emulsions and extracts were prepared and administered to the animals in the manner described under the heading of Methods and Materials.

Each of 2 monkeys, Nos. 26 and 27, received 14 injections, 5 of emulsions and 9 of extracts. Both monkeys remained well and were used for Experiment XII in which the brains and cords were examined and found to show no perivascular demyelination.

Each of 3 monkeys, Nos. 29, 32, and 33, received 93 injections, 52 of emulsions and 41 of extracts. The 3 animals remained healthy and were used for Experiment XIII in which the brains and cords were examined and found to show no perivascular demyelination.

Monkey 30 received, between May 26, 1931, and Dec. 14, 1931, 84 injections, 46 of emulsions and 38 of extracts. On Nov. 9, it was noticed that the monkey kept its head turned to the left, and that there was a tendency for the chin to rest on the left shoulder. The animal at this time began to lose weight and grow weak. On Dec. 2, the monkey seemed ataxic, climbed about the cage with difficulty, and became tired quickly. The animal gradually grew worse and was sacrificed on Dec. 18, 1931. At no time were there any signs suggestive of tuberculosis. At autopsy all the organs macroscopically appeared normal. No evidence of tuberculosis was seen. Cultures of the brain remained sterile. Sections stained with hematoxylin and eosin revealed a slight amount of perivascular infiltration in the cerebrum and cord, a marked perivascular infiltration in the midbrain, pons (Figs. 5 and 7), medulla, and cerebellum (Fig. 6). In certain instances, the cells seemed to be collected in the perivascular spaces, while in others there was definite glial reaction extending out from the vessels into the substance of the brain. Some areas not definitely associated with vessels (Fig. 5) showed a similar glial reaction. In places the lesions had a granulomatous appearance, and an occasional giant cell (Fig. 9) was found. In spite of the fact that mononuclear cells predominated in the cellular reaction a surprisingly large number of eosinophilic polymorphonuclear elements were also found. In certain areas the meninges (Fig. 9) of the cerebellum were involved and showed an infiltration of mononuclear cells. Marchi and Weigert stains revealed definite changes in or loss of myelin sheaths in the neighborhood of vessels in the pons (Fig. 10) and cerebellum (Fig. 8). No degeneration of spinal cord tracts was seen.

Monkey 31 received, between May 26, 1931, and Oct. 10, 1931, 52 injections, 28 of emulsions and 24 of extracts. On July 20, an abscess formed at the site of

one of the inoculations. From that time until Aug. 10 the injections were discontinued. After the abscess healed, the inoculations were again made at the rate of 3 a week. On Oct. 9, the animal appeared weak and dragged its left leg. Oct. 14, the animal was weaker, left arm and leg were partially paralyzed leading to incoordination of movement particularly noticeable when the monkey made attempts to climb up the side of the cage. Oct. 16, the animal was sacrificed and autopsied immediately. All the organs seemed normal except the brain. No evidence of tuberculosis was found. The brain was congested and on section the white substance of the right parietal lobe had a moth-eaten appearance. A

TABLE III
Summary of the Results of Experiment XI in Which Monkeys Received Repeated Injections of Emulsion and Extracts of Normal Rabbit Brains

Monkey No.	No. of injections of brain emulsions	No. of injections of brain extracts	Results
26	5	9	Negative. Used in Experiment XII
27	5	9	" " " " XII
28	24	26	Died suddenly after 50th injection. Brain and cord negative
29	52	41	Negative. Used in Experiment XIII
30	46	38	Developed a tendency to hold chin on left shoulder, ataxia, and weakness. Sacrificed. Section showed involvement of midbrain, pons, cerebellum, and medulla, with perivascular demyelination
31	28	24	Developed ataxia, general weakness, and paresis of left leg and arm. Sacrificed. Section through right parietal and temporal lobes showed marked involvement of white matter with perivascular demyelination. Tract degeneration in cord
32	52	41	Negative. Used in Experiment XIII
33	52	41	" " " " XIII

Sudan III preparation from this area showed a large number of fat-containing cells around the vessels. Cultures made from the brain remained sterile. Sections of the brain stained with hematoxylin and eosin revealed a marked infiltration of cells in the white substance of the right parietal lobe (Figs. 12-15) and a slight infiltration in the left parietal lobe. In general, the cells seemed to be collected around the vessels (Figs. 12, 15) but they also extended well out into the substance of the brain (Fig. 13, 14). At times the cells assumed a palisade arrangement around minute areas of necrosis in such a manner as to be suggestive of granulomatous lesions. Mononuclear cells, particularly glial elements, pre-

dominated in the reaction. Nevertheless, a surprisingly large number of eosinophilic polymorphonuclear elements were found. Marchi and Weigert preparations showed marked changes in or loss of the myelin sheaths in the right parietal lobe (Fig. 11). Slight pathological changes of a similar nature were also found in the left parietal lobe. Marchi preparations of the cord revealed degeneration of myelin in both of the lateral pyramidal tracts and both of the anterior median columns.

From the results of Experiment XI (Table III) it appears that of 8 healthy half-grown monkeys (*Macacus rhesus*) receiving repeated injections of emulsions and alcohol-ether extracts of normal rabbit brains, 5 developed no clinical signs of involvement of the central nervous system and at autopsy showed no evidences of perivascular demyelination, 1 suddenly died after an injection and had no demonstrable pathological changes in the central nervous system, and 2 developed clinical signs of involvement of the central nervous system in which sections revealed an inflammatory reaction accompanied by demyelination. The significance of the findings in these 2 monkeys will be discussed in another part of the paper.

Effect of Vaccine Virus on Monkeys Receiving Repeated Injections of Emulsions and Extracts of Normal Rabbit Brains

Having studied the effect of vaccine virus on the brains of normal, partially immune, and immune monkeys, and having noted the effect in monkeys of repeated injections of emulsions and alcohol-ether extracts of normal rabbit brains, we decided to investigate the reaction of monkeys to the combined action of vaccine virus and emulsions and extracts of normal brain tissue. This matter was dealt with in Experiments XII and XIII.

Experiment XII.—Monkey 26, between May 26, 1931, and July 1, 1931, received 14 injections, 5 of emulsions of fresh rabbit brain and 9 of alcohol-ether extracts of brain tissue. Shortly after the last injection the monkey was inoculated in 2 places on the skin with vaccine virus propagated in tissue cultures. 2 days after the dermal vaccination, a cisternal puncture was made, fluid was removed, and 0.5 cc. of a 1-20 Locke's solution dilution of the alcohol-ether extract of brain tissue plus 0.5 cc. of a 1-20 Locke's solution dilution of culture vaccine virus was injected. Typical lesions developed at the sites of dermal vaccination. As a result of the cisternal injection of virus, the animal developed signs of meningitis and was sacrificed 10 days after the inoculation. Examination of the brain

and cord showed a meningitis similar to that described earlier in the paper. No evidence of perivascular demyelination was found in Marchi and Weigert preparations. Monkey 27, control for No. 26, received, between May 26, 1931, and July 1, 1931, 14 injections, 5 of brain emulsions and 9 of brain extracts. This animal was not vaccinated on the skin, but received an inoculation in the cisterna magna similar to that given Monkey 26. The animal developed meningitis and was sacrificed 9 days after the cisternal inoculation. Examination of the brain and cord showed a meningitis similar to that found in Monkey 26.

Experiment XIII.—Each of 3 monkeys, Nos. 29, 32, and 33, received, between May 26, 1931, and Jan. 11, 1932, 93 injections, 52 of brain emulsions and 41 of brain extracts. A few days after the last injection the animals were inoculated in the following manner: Monkey 29, vaccinated on the skin with rabbit testicular vaccine virus, received intravenously 1 cc. of a 1-5 dilution of culture vaccine virus and intracerebrally 0.25 cc. of a 1 per cent emulsion of fresh rabbit brain. Monkey 32, vaccinated on the skin with rabbit testicular vaccine virus, received intravenously 1 cc. of a 1-5 dilution of culture vaccine virus plus 1 cc. of a 1 per cent emulsion of fresh rabbit brain mixed with 3 cc. of Locke's solution; a cisternal puncture was made and 2 cc. of fluid were withdrawn. Monkey 33, vaccinated on the skin with rabbit testicular vaccine virus, received intravenously 1 cc. of a 1-5 culture vaccine virus; a cisternal puncture was made, 1.5 cc. of fluid were withdrawn, and 0.35 cc. of a 1 per cent emulsion of fresh rabbit brain were injected. The 3 monkeys developed typical vaccinal lesions at the sites of skin inoculation, but never showed signs of central nervous system involvement. Monkeys 29, 32, and 33 were sacrificed 18, 17, and 16 days respectively after inoculation. Examination of the brains and cords revealed no evidences of meningitis, encephalitis, or perivascular demyelination.

From Experiments XII and XIII no evidence was obtained to indicate that the combined action of vaccine virus and an emulsion of fresh rabbit brain is capable of producing perivascular demyelination in monkeys that had received repeated injections of emulsions and alcohol-ether extracts of normal rabbit brains.

DISCUSSION

The acute disseminated encephalomyelitis that occasionally follows Jennerian prophylaxis, smallpox, measles, and antirabic vaccination is now a well recognized pathological picture (1, 2, 3, 20) and is particularly characterized by perivascular demyelination. Indeed, the perivascular demyelination is such an important part of the process that all investigators attempting to produce the disease experimentally should study their material by means of Marchi and Weigert stains as well as

by the ordinary stains usually employed. In the past certain workers have failed to do so, and this fact leaves one in doubt concerning the results actually obtained by them.

The results of the work reported in the first part of the paper clearly show that vaccine virus, free from bacteria, injected into the cisterna magna or into the parietal lobe of a monkey leads to a fatal disease. These findings are in accord with those of Eckstein (9) and Hurst and Fairbrother (4). The pathological picture is that of a severe meningitis accompanied by a mild encephalitis involving the superficial portions of the brain. No evidence was obtained to indicate that the direct action of vaccine virus on the brain of a normal monkey is capable of producing an acute disseminated encephalomyelitis with perivascular demyelination. In this respect our results are different from those reported by Clearkin (6) and McIntosh and Scarff (5).

The results of our work dealing with the effect of vaccine virus on the brains of partially immune and immune monkeys lend no support to the idea that postvaccinal encephalomyelitis is an hyperergic phenomenon (16). We did find, however, that the brain of a monkey vaccinated on the skin rapidly becomes refractory to the active agent placed in the cisterna magna or in the parietal lobe. Indeed, the refractory state is evident by the 4th day and quite marked by the 6th day after dermal vaccination (Table I).

A testicular extract prepared in the manner described by Reynals enhances the activity of vaccine virus. It has been suggested that the enhancement is due in part to an increased permeability of susceptible cells (12). In Experiment X, the Reynals' factor with and without vaccine virus was placed in the cisterns of monkeys, some of which had, while others had not been vaccinated on the skin. This was done in the hope that the testicular extract would break down the barrier between the subarachnoid space and brain or between the blood stream and brain in such a way as to permit the vaccine virus to produce an acute disseminated encephalomyelitis. Our hopes were not realized, however, because such an encephalomyelitis failed to be induced in this manner.

The results of repeated injections of brain emulsions and brain extracts into monkeys are interesting. The significance of the findings, however, is not clear. One animal died suddenly after an

inoculation, but showed no lesions in the brain and cord to account for the death. This is in accord with observations (14) that sudden deaths without obvious cause occur in rabbits receiving repeated inoculations of brain emulsions. Two monkeys developed clinical signs of involvement of the central nervous system. Examination of one of the animals revealed an inflammatory reaction accompanied by perivascular demyelination in the midbrain, pons, medulla, and cerebellum. Examination of the other animal brought to light pathological changes in the cerebrum suggestive of, but different from, those seen in Schilder's disease. Inasmuch as two of eight monkeys receiving repeated injections of brain emulsions and brain extracts developed central nervous system lesions with destruction of myelin sheaths, one might be tempted to ascribe the pathological changes to the treatment received by the animals. Nevertheless, the lesions were not typical of disseminated encephalomyelitis. Furthermore, from reports in the literature (21-26) it appears that monkeys may suffer from spontaneous demyelinating diseases of the central nervous system. The picture in our monkeys, however, is not identical with any of those already recorded. Consequently, at the moment we hesitate to state definitely what relation the treatment of our monkeys had to the disease found in them. The experiment should be repeated with a larger number of monkeys, and we intend to do so if the opportunity arises.

SUMMARY

No evidence was found to support the idea that vaccine virus placed in the cisterna magna is capable of producing an acute disseminated encephalomyelitis with perivascular demyelination either in normal or in partially immune monkeys.

A testicular extract (Reynals' factor) did not induce vaccine virus to cause an acute disseminated encephalomyelitis in monkeys.

Repeated intramuscular injections of brain extracts and brain emulsions into eight monkeys were followed in two instances by an inflammatory reaction, accompanied by demyelination, in the central nervous system. The exact relation of the injections to the disease of the nervous system is not clear.

The combined action of vaccine virus and an emulsion of fresh rabbit brain did not lead to the production of an acute disseminated encephalo-

myelitis in monkeys that had received repeated intramuscular injections of emulsions and alcohol-ether extracts of normal rabbit brains.

REFERENCES

1. Perdrau, J. R., *J. Path. and Bact.*, 1928, **31**, 17.
2. Marsden, J. P., and Hurst, E. W., *Brain*, 1932, **55**, pt. 2, 181.
3. Spielmeyer, W., *Z. Hyg. u. Infektionskrankh.*, 1931-32, **113**, 170.
4. Hurst, E. W., and Fairbrother, R. W., *J. Path. and Bact.*, 1930, **33**, 463.
5. McIntosh, J., and Scarff, R. W., *J. Path. and Bact.*, 1930, **33**, 483.
6. Clearkin, P. A., *Brit. J. Exp. Path.*, 1930, **11**, 329.
7. Eckstein, A., and Sarvan, M., *Z. Hyg. u. Infektionskrankh.*, 1930, **111**, 659.
8. Eckstein, A., *Z. Hyg. u. Infektionskrankh.*, 1930, **111**, 669.
9. Eckstein, A., *Z. Hyg. u. Infektionskrankh.*, 1931, **112**, 151.
10. Eckstein, A., *Z. Hyg. u. Infektionskrankh.*, 1931-32, **113**, 371.
11. Duran-Reynals, F., *J. Exp. Med.*, 1929, **50**, 327.
12. Hoffman, D. C., and Duran-Reynals, F., *Science*, 1930, **72**, 508.
13. Koritschoner, R., and Schweinburg, F., *Z. Immunitätsforsch.*, 1925, **42**, 217.
14. Hurst, E. W., *J. Hyg.*, 1932, **32**, 33.
15. Rivers, T. M., *J. Exp. Med.*, 1931, **54**, 453.
16. Glanzmann, E., *Schweiz. med. Woch.*, 1927, **57**, 145.
17. Remlinger, P., *Ann. Inst. Pasteur*, 1905, **19**, 625.
18. Stuart, G., and Krikorian, K. S., *Ann. Trop. Med. and Parasitol.*, 1928, **22**, 327.
19. Stuart, G., and Krikorian, K. S., *Lancet*, 1930, **1**, 1123.
20. Bassoe, P., and Grinker, R. R., *Arch. Neurol. and Psychiat.*, 1930, **23**, 1138.
21. Perdrau, J. R., *J. Path. and Bact.*, 1930, **33**, 991.
22. Rothmann, M., *Monatschr. Psychiat. u. Neurol.*, 1906, **20**, 204.
23. Schröder, P., *Arch. Psychiat.*, 1908, **44**, 193.
24. Schob, F., *Z. ges. Neurol. u. Psychiat.*, 1931, **135**, 95.
25. Levaditi, C., Lépine, P., and Schoen, R., *Compt. rend. Soc. biol.*, 1930, **104**, 986.
26. Bodechtel, G., *Z. Hyg. u. Infektionskrankh.*, 1930, **111**, 331.

EXPLANATION OF PLATES

PLATE 1

FIG. 1. Vaccinal meningitis in the neighborhood of the pons and cerebellum. The exudate consists of fibrin and polymorphonuclear and mononuclear cells. H. and E. \times 63.

FIG. 2. Inflammation of the meninges of the cord caused by vaccine virus. H. and E. \times 63.

FIG. 3. Inflammation of the cerebral meninges induced by vaccine virus. The exudate immediately in contact with the surface of the brain consists of mononuclear cells and is suggestive of the type of reaction caused by the activity of vaccine

virus in the skin. The substance of the brain near the surface also enters into the reaction and displays a certain amount of perivascular infiltration. H. and E. $\times 250$.

FIG. 4. Perivascular infiltration in the pons caused by vaccine virus placed in the cisterna magna. The perivascular exudate was rarely as marked as portrayed. H. and E. $\times 250$.

PLATE 2

FIG. 5. Lesions in the pons of Monkey 30. H. and E. $\times 63$.

FIG. 6. Lesions in the cerebellum of Monkey 30. H. and E. $\times 63$.

FIG. 7. Perivascular infiltration in the pons of Monkey 30. H. and E. $\times 250$.

FIG. 8. Demyelination in cerebellum of Monkey 30. Modified Weigert stain. $\times 37$.

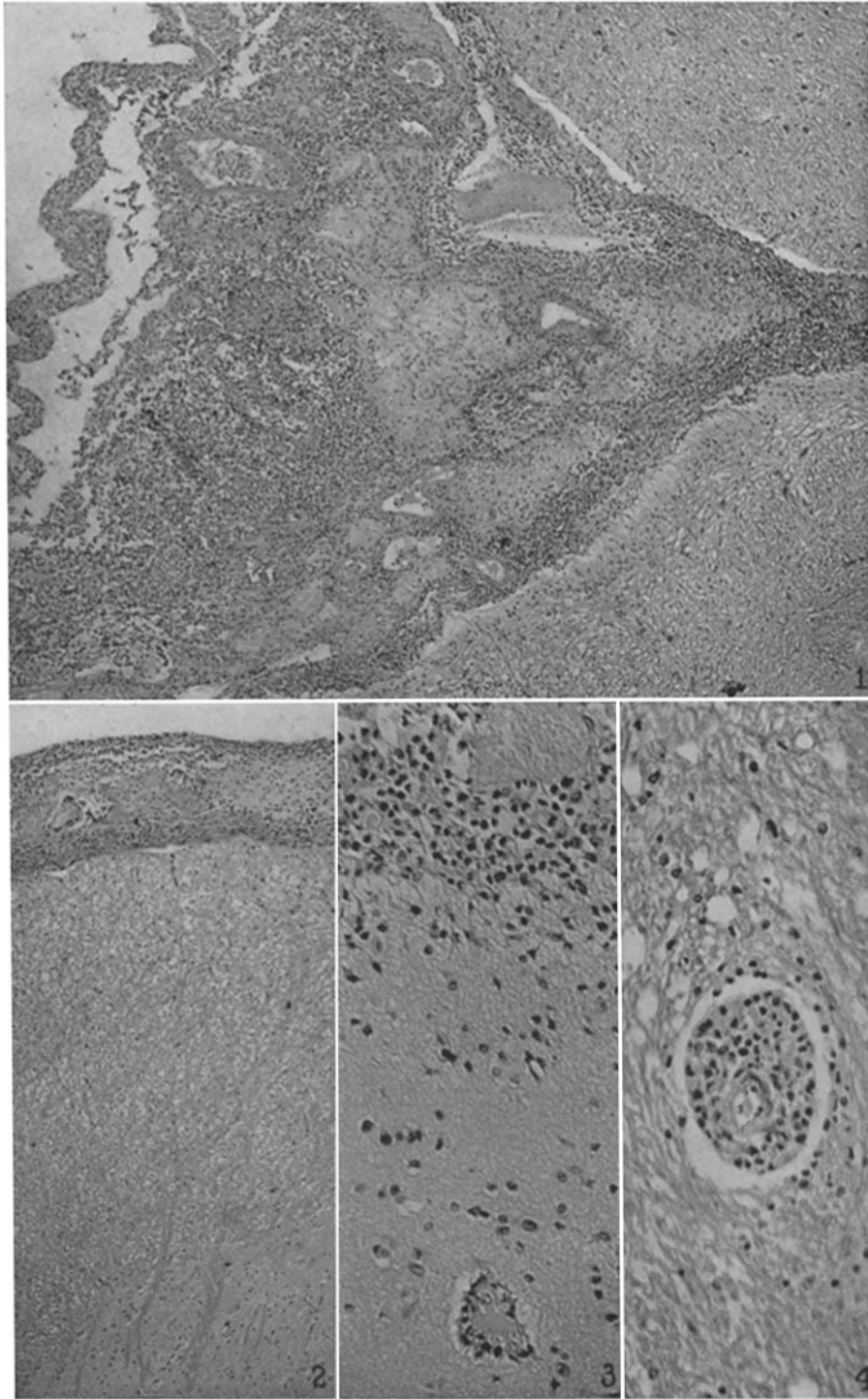
FIG. 9. Giant cells in cerebellum, and thickened cerebellar meninges infiltrated with mononuclear cells. Monkey 30. H. and E. $\times 250$.

FIG. 10. Demyelination in pons of Monkey 30. Modified Weigert stain. $\times 37$.

PLATE 3

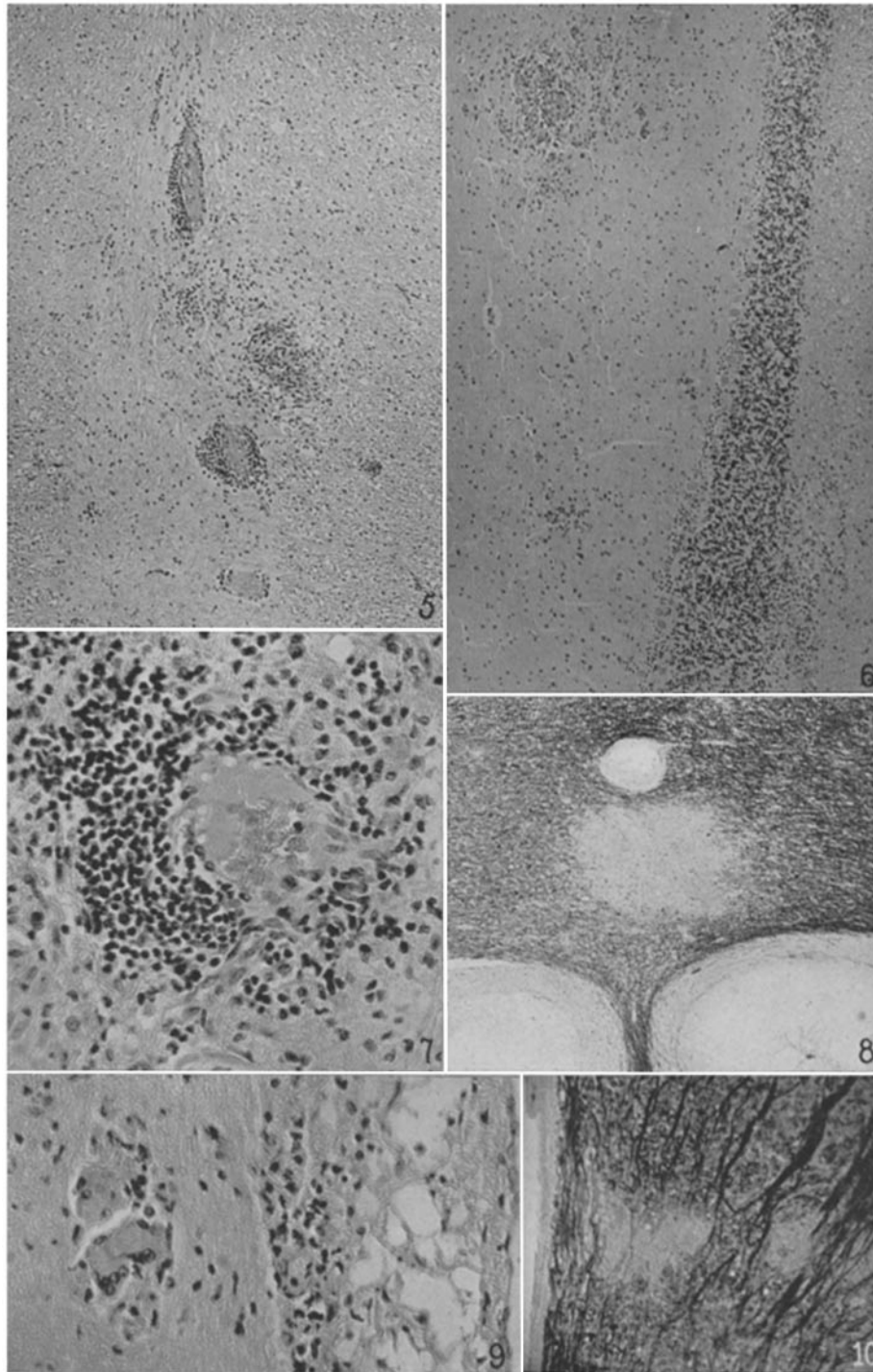
FIG. 11. Demyelination in the right parietal lobe of Monkey 31. The picture is suggestive of Schilder's disease. Modified Weigert stain. $\times 37$.

FIGS. 12-15. Lesions in the right parietal lobe of Monkey 31. Note the perivascular distribution. H. and E. $\times 250$ and $\times 63$.



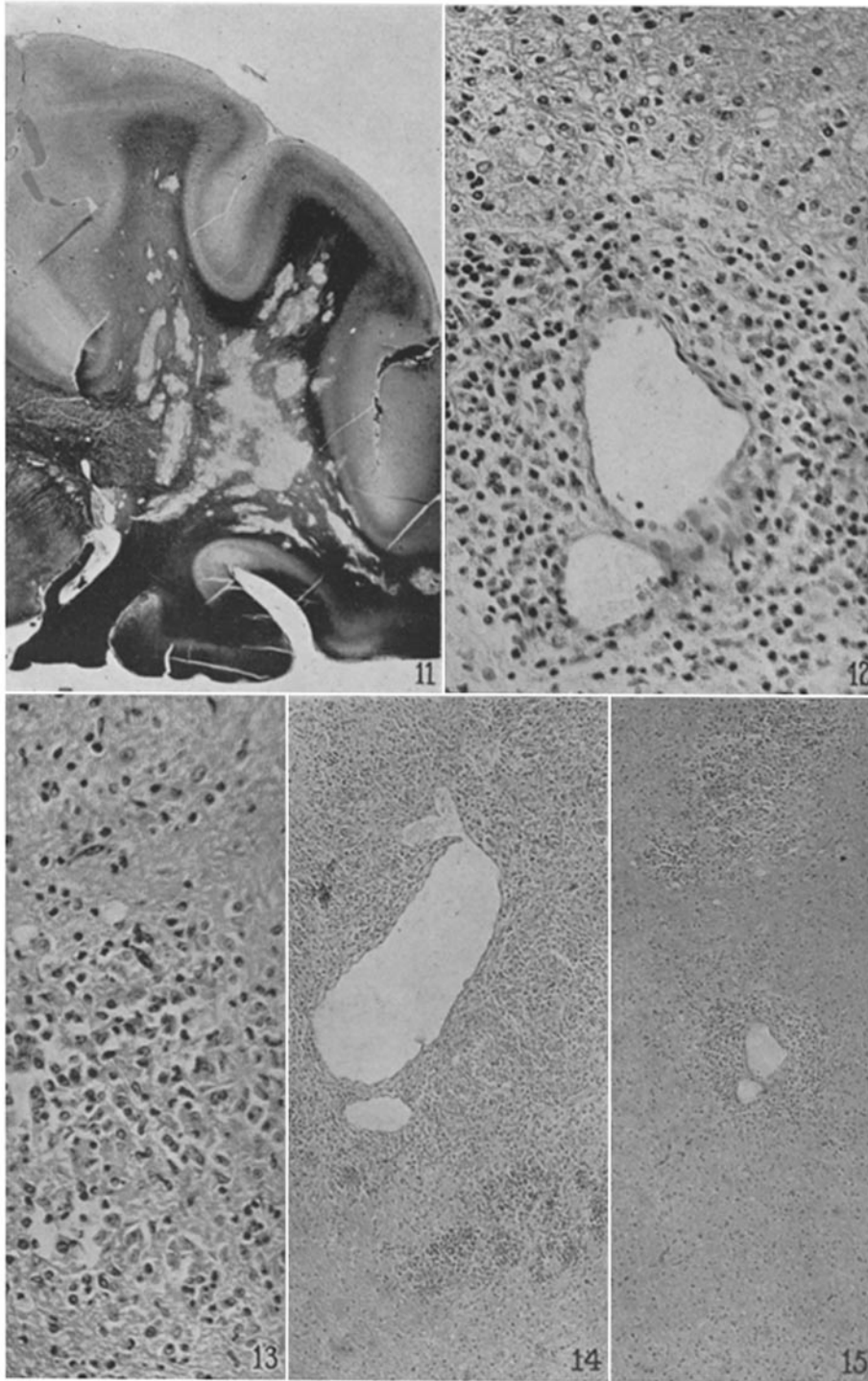
Photographed by Louis Schmidt

(Rivers *et al.*: Acute disseminated encephalomyelitis)



Photographed by Louis Schmidt

(Rivers *et al.*: Acute disseminated encephalomyelitis)



Photographed by Louis Schmidt

(Rivers *et al.*: Acute disseminated encephalomyelitis)