

OXYGEN POISONING IN COLD BLOODED ANIMALS.

BY JAMES M. FAULKNER, M.D., AND CARL A. L. BINGER, M.D.

(From the Hospital of The Rockefeller Institute for Medical Research.)

PLATE 29.

(Received for publication, January 3, 1927.)

INTRODUCTION.

In another paper (1) the effect of breathing atmospheres rich in oxygen on a variety of mammals was reported, and the nature of the injury to the lungs and the cause of death was discussed. It was pointed out that the pulmonary lesion was characterized by capillary dilatation and hemorrhagic edema. The work here to be described was undertaken not simply for the purpose of extending the study to other species but with the hope of observing the effect of high concentrations of oxygen on a capillary system more accessible to inspection than that in the lungs. For this purpose we utilized the web of frogs exposed to high concentrations of oxygen (90 to 99 per cent) over long periods. The web capillaries were examined periodically during life and after death sections were made of the skin, as well as of the lungs, heart, liver and kidney. No changes were observed in the capillaries or in the pigment cells as a result of oxygen administration. Two frogs grew definitely darker in color after 7 and 10 weeks exposure, respectively, but we attach no special significance to this, because color changes in the frog's skin are readily produced by a variety of causes difficult to control (2). In this instance inanition may have been a cause, since the frogs were not fed during the course of the experiment.

Krogh (3) has shown that the cutaneous respiratory exchange of the frog differs from its pulmonary respiration in that carbon dioxide is eliminated chiefly through the skin, while oxygen is absorbed chiefly by the lungs. Enough oxygen may be absorbed through the skin, however, to keep a frog alive for several weeks at 7-8°C. when the pulmonary ventilation is entirely cut off (4). This may be

accomplished by applying a gag to the frog in such a manner that it is unable to close its mouth, thus inhibiting the normal swallowing movements, whereby this animal forces air into its lungs (5). By placing gagged frogs in jars containing 90 to 95 per cent oxygen it was hoped to bring about changes in the skin capillaries, since the oxygen absorption would, under these circumstances, be chiefly through the skin and pharyngeal mucous membrane. None of the frogs showed any changes, however, in the skin capillaries.

These experiments, though negative with respect to the original subject of enquiry, brought out the fact that frogs could survive, apparently unharmed, in concentrations of oxygen poisonous to mammals. This observation seemed of sufficient interest to merit further study. Did it signify that cold blooded animals are resistant to the poisonous action of high concentrations of oxygen? And is the difference in their behavior from the behavior of mammals solely dependent on their differences in body temperature?

EXPERIMENTAL.

Experiments on Frogs.—Two frogs placed in a shallow dish containing a little water were continuously exposed under a bell jar to an atmosphere with an oxygen concentration averaging from 80 to 90 per cent. After 21 days exposure they were removed from the jar. Throughout the experiment and at the time of removal from the oxygen they remained apparently normal in appearance and behavior. The frogs were killed and autopsied. No gross changes in the lungs or other viscera were to be seen. Two other frogs were kept continuously in 90 to 98 per cent oxygen for respective periods of 49 and 68 days without apparent damage to their well being. At the close of the experiment they were found to be more deeply pigmented than they had been at the start, forming a marked contrast in color to two control frogs. No other changes in them were to be seen. Mammals exposed to similar environmental conditions would probably have died within the 1st week. To discover whether this difference in behavior was due to differences in body temperature an effort was made to keep frogs alive at incubator temperature (37.5°C.), but the frogs were unable to withstand this and died within 24 hours. For this reason we decided to make experiments on turtles whose life habits frequently expose them to high temperatures.

Experiments on Turtles.—Is the turtle also resistant to high concentrations of oxygen?

Protocol. Experiment 1.—A common adult pond turtle (*Chelopus guttatus*) was placed in a shallow dish containing a little water. The dish was covered with a

bell jar through which a stream of oxygen was allowed to run at the rate of 1 liter per minute. After 23 days exposure to an atmosphere containing an oxygen concentration for the most part above 90 per cent the turtle was removed in an apparently normal state. At autopsy the lungs were found to be normal in both gross and microscopic appearance (see Fig. 1).

Experiment 2.—The above experiment was repeated on another adult of the same species. After 10 days in an atmosphere of 90 per cent oxygen the turtle was removed from the bell jar in an apparently normal state.

Experiment 3.—Five young green turtles (*Chrysemes elegans*) lived for 3 weeks in 97 to 99 per cent oxygen at room temperature (23–26°C.) without appearing in any way affected by the unusual environment. A sixth member of this group was found dead after 17 days exposure, but there was no respiratory distress observed, and no definite evidence of pulmonary pathology was seen. These experiments indicate that the turtle, like the frog, can survive, unharmed, in concentrations of oxygen fatal to mammals.

Effect of Mammalian Temperature on Turtles.

Two adult specimens of *Chelopus guttatus* survived for 36 days in an incubator at 37.5°C., showing at no time loss of appetite or other signs of ill health.

An adult *Chrysemes elegans* spent 34 days, and six young individuals of the same species spent 21 days in the incubator. At the end of this time they were all lively and eating well.

From these observations it can be concluded that turtles are unharmed by prolonged exposure to room air warmed to 37.5°C.

Effect of Combination of High Concentrations of Oxygen and Mammalian Temperature on Turtles.

To find out whether the difference in the reaction of turtles exposed to high concentrations of oxygen from that of mammals was dependent upon their differences in body temperature, we exposed turtles to 90 per cent oxygen warmed to 37.5°C. Individuals of various ages and species were confined in an ordinary bacteriological incubator in which the oxygen concentration was kept above 90 per cent by blowing a stream of oxygen through it. It was soon learned that under these conditions turtles behaved like mammals in their susceptibility to oxygen, exhibiting like abnormalities in function and structure. Since young turtles behaved somewhat differently from adults the experimental results will be classed accordingly.

Experiments on Adult Turtles.

Protocol. Experiment 4.—May 22, 1926. An adult male pond turtle (*Chelopus guttatus*), kept in a shallow dish containing a little water, was put into an ordinary bacteriological incubator. This individual had previously survived, without ill effect, a 36 day exposure to room air warmed to 37.5°C. The incubator was provided with a pan of soda-lime for absorption of carbon dioxide, and a constant stream of oxygen was now run through the incubator at the rate of 1 liter per minute. Analysis at 11 p.m. showed the oxygen percentage to be 94 and the temperature 37.5°C.

May 23, 11 a.m. Oxygen concentration in the incubator 91 per cent.

May 24, 9.45 a.m. Oxygen concentration in the incubator 94 per cent.
CO₂ concentration in the incubator 0.02 per cent.

At about 11 a.m. it was noticed that the turtle was opening its mouth to breathe. It stretched its neck, opened its mouth and extended its fore legs at each inspiration. These gasping breaths increased in frequency during the afternoon.

May 25. At 10 a.m. the turtle was found dead. Autopsy showed the lungs to be opaque and blood-red instead of being of the normal pale gray transparency. Microscopic examination showed marked engorgement of the pulmonary capillaries.

Experiment 5.—May 5, 1926. Another adult turtle of the same species (*Chelopus guttatus*) was placed in an incubator containing 90 per cent oxygen, as in the experiment just reported.

May 6, 9.10 a.m. O₂ concentration 93 per cent.

7.45 p.m. O₂ concentration 94 per cent. Temperature in incubator 37.5°C.
Turtle rather inactive and refuses to eat an earthworm which is offered to it.

May 7, 12.30 p.m. O₂ concentration 95 per cent. Temperature 37°C.

May 8, 11 a.m. O₂ concentration 97 per cent. Temperature 38°C.

May 9, 12.30 p.m. O₂ concentration 95 per cent. Temperature 38.5°C.

May 10, 10 a.m. O₂ concentration 95 per cent. Temperature 38.5°C. The turtle shows a peculiar form of breathing today. It stretches its neck, then opens its mouth for several seconds and swells out its throat. It then shuts its mouth, retracting and deflating its neck, apparently forcing air into the lungs. This process is repeated about every 30 seconds.

May 11, 10.30 a.m. O₂ concentration 95 per cent. Temperature 38°C. Turtle still shows same type of breathing at a somewhat more rapid rate than yesterday. Accompanying each inspiratory gasp it extends its fore legs, as if to aid respiration.

May 12, 9.40 a.m. O₂ concentration 94.5 per cent. Temperature 37°C. Same type of breathing persists.

May 13, 9.30 a.m. Oxygen cylinder emptied during night. O₂ concentration fell to 42 per cent. Gasping for breath.

10 a.m. O₂ concentration 97 per cent.

1.15 p.m. Turtle apparently lifeless—lying with its head under water. Reflexes were still present, however. The plastron was removed and the heart was

found to be still beating. All the organs except the lungs were removed. These were left *in situ* and fixed in 10 per cent formalin. The lungs were definitely redder than normal. Microscopic examination showed a very marked vascular congestion with great dilatation of capillaries. An illustration of this may be seen in Fig. 2, which should be compared with Fig. 1, a section made from the normal turtle lung.

Experiments similar to the two just described were repeated on another individual of the same species, on two adult Cumberland terrapins (*Chrysemes elegans*) and on one box turtle (*Cistudo carolina*) approximately 15 years old. All of them ended fatally. The duration of life and the degree of pulmonary congestion found at autopsy varied in the different individuals.

These experiments show that high concentrations of oxygen, when combined with incubator temperature (37-38°C.), are fatal to adult turtles of several different species, producing changes analogous to those found in the mammal, namely: progressive dyspnea, culminating in death, with hemorrhagic changes in the lungs. Neither high concentrations of oxygen, nor warm room air alone brought about these changes.

Experiments on Young Turtles (Chrysemes elegans).

It has already been stated that young individuals of the species *Chrysemes elegans* survived unharmed exposure to 97 to 99 per cent oxygen for a prolonged period. They were found to be equally resistant to exposure to warm air, behaving in these respects just like the adults.

On exposing them to oxygen warmed to 37.5°C., it was observed that they survived longer than the adult specimens did. Eventually, however, they succumbed, showing similar hemorrhagic extravasations into the lungs.

Experiment 6.—Five young turtles (*Chrysemes elegans*), whose shells measured about 3.5 cm. in diameter, were exposed in an incubator at 37.5°C. to an oxygen concentration varying from 94 to 98 per cent of an atmosphere. After 21 days exposure, the first one died. After 24 days, a second died. After 27 days, two of the survivors showed curious wing-shaped dark areas on their backs, found at autopsy to be due to seepage of extravasated blood from the lungs. These two died respectively on the 32nd and 41st day after exposure. The lungs at autopsy were found to be very red, with extravasation of blood into the extrapulmonary tissue.

The last turtle died on the 50th day after exposure to warm oxygen. At autopsy its lungs were found to be red and edematous, with blood stains through the plastron and carapace.

DISCUSSION.

An adequate explanation for the facts presented in this paper is not at hand. It is clear that increasing the temperature does not increase the oxygen concentration in the body. The implication would seem to be that a reaction occurs between oxygen and pulmonary tissue whose temperature coefficient is such that it progresses at the temperature of the mammalian body but not at ordinary room temperature. Whether a chemical substance is produced which acts as an irritant to the lungs cannot be stated, or whether the increased temperature acts by raising the metabolic rate, which is known to enhance the toxic effect of certain substances.

SUMMARY AND CONCLUSIONS.

1. Exposure of frogs to atmospheres containing approximately 95 per cent of oxygen is without apparent effect on their state of well being, and produces no noticeable changes in the appearance of their web capillaries.
2. Turtles exposed to similar atmospheres are also apparently unaffected unless the oxygen be warmed to mammalian temperature.
3. At this temperature (37.5°C.) the turtles behave like mammals, showing loss of appetite, shortness of breath, death and, at autopsy, hemorrhagic extravasations in the lungs.
4. Young turtles are more resistant (or adaptable) to this change in environment than mature ones.

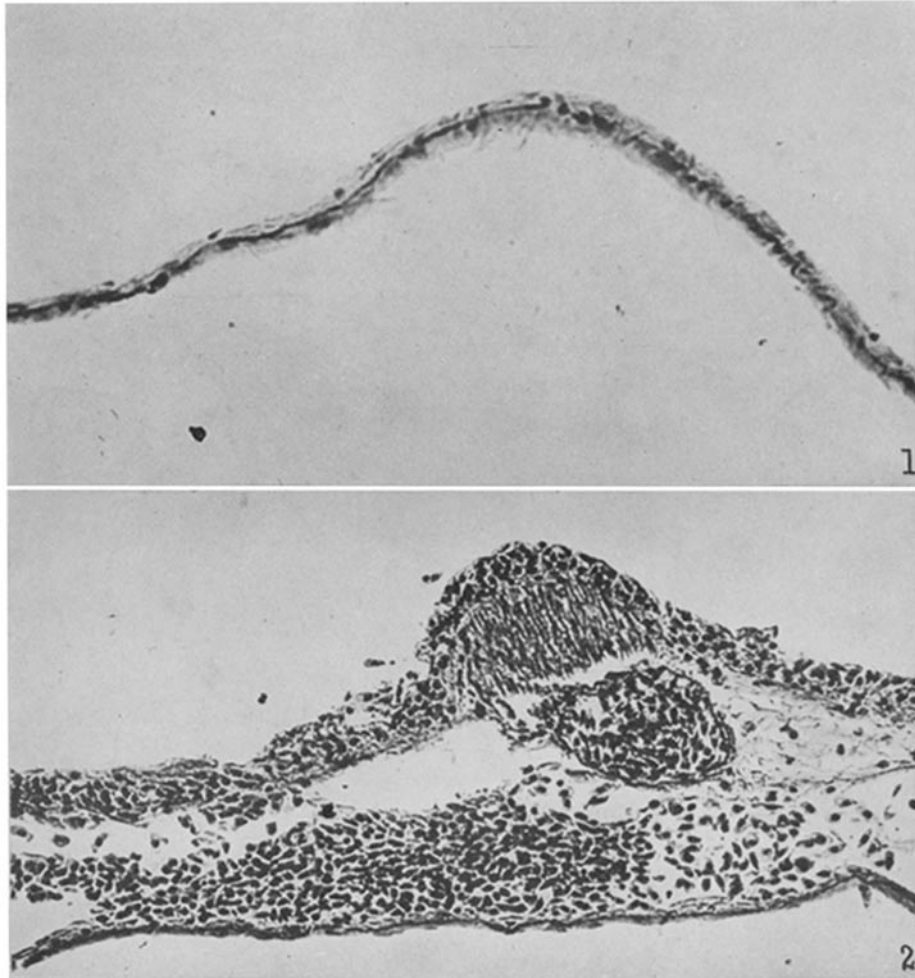
BIBLIOGRAPHY.

1. Binger, C. A. L., Faulkner, J. M., and Moore, R. L., *J. Exp. Med.*, 1927, xlv, 849.
2. Gaupp, E., in Ecker, A., and Wiedersheim, R., *Anatomie des Frosches*, Braunschweig, 2nd edition, 1904, pt. 3, 523.
3. Krogh, A., *Skand. Arch. Physiol.*, 1904, xv, 328.
4. Panizza, B., *Ann. sc. nat. zool.*, 1845, iii, series 3, 230.
5. Couvreur, E., *J. physiol. et path. gén.*, 1909, xi, 590.

EXPLANATION OF PLATE 29.

FIG. 1. Section of normal turtle lung showing thin walled respiratory membrane. Magnification $\times 240$.

FIG. 2. Section of lung taken from turtle killed by exposure to warm oxygen. Magnification $\times 240$. The photograph shows a characteristic hemorrhagic area with extravasated nucleated red blood corpuscles.



(Faulkner and Binger: Oxygen poisoning in cold blooded animals.)