

AN EXPERIMENTAL STUDY OF CIRCUMSCRIBED DILATION OF AN ARTERY IMMEDIATELY DISTAL TO A PARTIALLY OCCLUDING BAND, AND ITS BEARING ON THE DILATION OF THE SUBCLAVIAN ARTERY OBSERVED IN CERTAIN CASES OF CERVICAL RIB.*

By W. S. HALSTED, M.D.

(From the Department of Surgery of the Johns Hopkins University, Baltimore.)

PLATES 16 TO 19.

(Received for publication, June 27, 1916.)

No one, since Deitmar,¹ has attempted to collate the cases of dilation of the subclavian artery associated with cervical rib. Deitmar cites five cases (Adams, Coote, Poland, Baum, and von Heinecke), including one (von Heinecke's) which I have tabulated as doubtful. Streissler's review² is perhaps the fullest in the literature on the subject of cervical rib. Although it appeared less than 3 years ago no addition is made by this author to Deitmar's list.

From a careful study, in the original, of the reports of 716 cases of cervical rib I find that aneurysm or dilation of the subclavian artery was noted in 27 or more of them, including six (Mayo, Murphy, Russel, von Heinecke, Galloway, and Seymour) in which the surgeon believed that the vessel was abnormally large, and two (Karg and Halsted) in which the aneurysm appeared promptly after removal of the supernumerary rib. There may be numerous other instances of dilation of the subclavian associated with cervical rib—cases in which the amount of arterial expansion could not be determined in the lack of a standard of comparison.

The Dilation of the Subclavian Artery Is Distal to the Line of Constriction Made by the Rib and the Scalenus Anticus Muscle.

As to the cause of these aneurysms there is much conjecture. The comment has frequently been made that their occurrence would be

* It is possible in the limits of the permissible space to present the results of the work of Dr. Reid and myself in merest outline. A full account will probably appear next year in the *Reports of the Johns Hopkins Hospital*.

¹ Deitmar, J., Inaug. Diss., Erlangen, 1907.

² Streissler, E., *Ergebn. Chir. u. Orthop.*, 1913, v, 280.

comprehensible if they appeared on the proximal instead of the peripheral side of the compression. No one has remarked that dilation central to the site of pressure might be even more difficult to comprehend.

The suggestions which have been offered in the effort to explain the phenomenon are as follows: (1) weakening of the wall of the artery from erosion or other trauma; (2) variable or intermittent pulse pressure; (3) vasomotor and vasa vasorum disturbances.

In 1906 Dr. E. H. Richardson and I made the observation that after partial occlusion of the thoracic aorta the maximum pressure may be permanently lowered and the minimum pressure actually increased distal to the constricting band of metal. This discovery was verified by Dr. Dawson on one of my dogs (No. 96).

Dog. 96. Partial Occlusion of the Thoracic Aorta.

Operation, May 22, 1906. Killed 7 months later.

	Maximum pressure.	Mean pressure.	Minimum pressure.	Pulse pressure.
Femoral.....	116	93	88	28
Carotid.....	160	113	83	77

The dilation of the artery observed in arteriovenous fistula might, I thought, have a bearing on the interpretation of the aneurysms in cases of cervical rib. "May not both phenomena," I asked myself, "be due to degenerative changes in the arterial wall consequent upon lowered pressure?"

Inasmuch as dilation of the subclavian artery has, relatively to the number of cases of cervical rib, so seldom been observed, it seemed that if it were due merely to the lowered pulse pressure, then only a very definite absolute or relative amount of reduction of the systolic pressure would suffice to produce it. It was realized, also, that even if the amount of reduction necessary to accomplish the desired result could be determined it could not be constantly maintained, inasmuch as the peripheral resistance becomes, in great measure, rapidly restored.

For a number of years, in the course of various experiments in partial occlusion of the arteries, I had somewhat in view the chance of there being produced beyond the point of constriction a dilation of

the artery analogous to that which had been observed in cases of cervical rib.

The Degree of Constriction and the Period of Time Required for the Production of the Dilation.

2 years ago when, after many trials, I had altogether despaired of having the hope realized, I was startled, on examining the abdomen of a dog whose aorta had been constricted for 5 months and 20 days, to see that each of the branches of trifurcation was dilated almost to the size of the main aortic trunk. About to leave town for the summer, I communicated the finding to Dr. Reid, asking him promptly to repeat the experiment, as precisely as possible. In the autumn we expectantly laparotomized three dogs upon which Dr. Reid had operated in the early summer and were disappointed to find that no change had taken place in the size of the aorta or its three terminal branches. Confident that there could have been no error in the original observation, I constricted the abdominal aorta, to various degrees, just above the trifurcation in twenty dogs and, at intervals, in the course of the winter, explored and reexplored the abdominal cavities, but with negative result, at least as concerned dilation.

Finally, on opening the abdomen of our last dog (No. 7) we found the dilation which we sought. The result is depicted in Figs. 1 to 4. The occlusion of the aorta in this case made 6 months and 19 days previously was almost complete, just as it had been in the one successful case of the foregoing year—I might say, of all the foregone years.

The pressure exercised by the band in this instance had been sufficient to lessen greatly, if not to obliterate, for a few moments at least, the palpable thrill produced by the constriction, but not enough completely to shut off the palpable pulse. With this observation as a fresh incentive, Dr. Reid and I have continued the experiments during the current academic year with encouraging results.

If the occlusion must be so nearly complete in order to effect a well pronounced dilation, it will explain not only the difficulty we have had in producing it in dogs, but also the fact that it has been observed so seldom in the human subject from compression of the subclavian

artery by a cervical rib. For when in dogs the aortic pulse is occluded beyond the stage of palpable thrill the lumen is in danger of becoming obliterated, as by the formation of a cylindrical fibrous cord beneath the band, and thus cancelling the experiment; and in the cervical rib cases we may assume argumentatively that the subclavian artery compressed to the stage sufficient to produce an aneurysm might become thickened by sclerotic changes in the time required for the pronounced manifestation of a dilation. Thus, a moderate dilation, present for a brief period prior to occlusion of the subclavian, might be overlooked.

In dogs, a number of months must apparently elapse after the application of the band before a dilation in striking degree can occur. In the two cases (No. 7, 1913, and No. 7, 1914) to which reference has been made, 5 months and 20 days, and 6 months and 19 days, respectively, had elapsed. In the second of these, a dilation of the middle branch of the trifurcation of 2 mm., found at the expiration of 60 days, had increased to 4 mm. in the course of the following $4\frac{1}{2}$ months (Figs. 1 to 4). Other instances of like dilation are accurately represented in Figs. 5 to 11. The amount of constriction made in two of the illustrated cases (Dogs 3 and 15, Series II) is indicated by the concentric circles of Figs. 8 and 11.

We have found and abstracted reports of 716 instances of cervical rib, in great part from the original.

Clinical cases.....	525	
Autopsies.....	91	
Museum specimens.....	100	
	<hr/>	
Total.....	716	
		<i>per cent</i>
Cases with nerve symptoms alone.....	235	65.3
Cases with nerve and vascular symptoms.....	106	29.4
Cases with vascular symptoms alone.....	19	5.3
	<hr/>	
Total.....	360	

525 were clinical cases; 91, autopsy findings; and 100, museum specimens. 360 presented symptoms of pressure. Of these, 235 had nerve symptoms alone; 106, nerve and vascular; and 19, only vascular symptoms. Accordingly we have reports of 125 cases of cervical rib

in which vascular symptoms were noted. In 27 of these (21.6 per cent) an enlargement, fusiform, aneurysmal, or cylindrical, was observed, and, of these, in the majority, the disturbance of circulation was severe, 6 cases having gangrene of fingers on the affected side (Table I).

Of the thirty dogs with aortic constriction upon which this report is based there was pronounced dilation, for a short distance, of the vessels below the band in seven, or 23.3 per cent.

It is interesting to note the correspondence in the human (21.6) and canine (23.3) percentages. We must not, however, overvalue the result of this haphazard sort of comparison, for, as regards the human cases we have depended upon the impressions of surgeons, who, having no standards of comparison, having made no measurements, and not always being particularly concerned about the arterial feature of the case, may have overlooked or overestimated variations from the norm; and, as regards the thirty dogs, we observed, in addition to the seven designated as major dilations, ten minor ones. The seventeen dilations of all grades represent 56.6 per cent of the thirty dogs. The percentage is even greater if we include in our calculation only the dogs of the past year; and, for another year of experimentation, would probably be greater still.

We may, I think, conclude that the dilation of an artery produced experimentally is not due to any of the three factors proposed as causal for the aneurysm in cases of cervical rib.

1. *Vasomotor Paralysis*.—(a) The vasomotor nerves and the vasa vasorum are destroyed by the moderately constricting and totally occluding bands quite as surely as by those which, occluding almost totally, alone have produced the dilation. (b) Only a portion of the circumference of the subclavian artery is exposed to the pressure of the cervical rib and the scalenus anticus muscle, and hence only a fraction of the vasomotor nerves or vasa vasorum could be pressed upon.

2. *Trauma*.—(a) Usually, the dilation is fusiform and (b) distal to the rib. (c) Trauma is excluded as a factor in the experimental dilations.

3. *Inconstant Blood Pressure*.—(a) Patients suffering from the pressure-pain of cervical rib rarely make wide excursion-movements of the arm. (b) The degree of occlusion is constant in the experimentally constricted vessel.

When an arterial trunk is ligated it becomes occluded to the first proximal and first distal branches by a process of cell proliferation which ultimately reduces the artery to a fibrous strand.

Is There a Fall in Blood Pressure in the Dead Arterial Pocket Which May Anticipate and Possibly Be a Causative Factor in the Obliteration of This Portion of an Artery?

From observations which I have made on man and dogs I am quite sure that there may be a remarkable fall in blood pressure in what I have termed the "dead arterial pocket," while there is still little if any sign of diminution in the caliber of this portion of the vessel. For example, the right common carotid artery was ligated by the writer in a case of aneurysm of the external carotid. About 3 months later, in the course of an operation for the excision of the uncured aneurysm, the internal carotid, dead-pocketed between the circle of Willis and the carotid ventricle, was freely exposed for a considerable distance. It had lost its cylindrical form, being flat and tape-like, and, although evidently possessing a considerable lumen, seemed to be empty. When pricked, a few drops of blood oozed without pulse from the little cut. The artery was then resected between two ligatures. Its wall was thickened on one side (Fig. 12) but the lumen was still perhaps three times that of a radial artery. Similar observations I have made twice on the external iliac artery of the dog after occlusion of this vessel at its origin from the aorta. In the approximately dead pocket between the aorta and the origin of the circumflex iliac and common trunk of the epigastric and obturator arteries the blood pressure must have been almost nil, because from a little slit made in the apparently normal arterial wall of the relatively empty external iliac artery the blood escaped very slowly in a tiny, almost pulseless jet about 1 cm. high; whereas, from the femoral artery, below the profunda, the blood spurted normally from a similar knife-prick.

Hence in an artery doomed to obliteration, it would seem that the blood pressure may be lowered before the occlusion process sets in—the lowered pressure being, perhaps, the immediate factor leading to the obliteration.

Consideration of the Cause of the Dilation.

Can these observations have any bearing upon the explanation of the dilation of the aorta above its trifurcation, of its triad branches,

and of the carotid, which we have occasionally observed in the dog distal to the partially occluding band?

The mechanical engineer knows the effect upon pressures of constricting a rigid tube through which water is being forced at a given pressure. At the site of the constriction, of the Venturi meter, the pressure is diminished and the velocity increased, whereas immediately beyond the constriction both the normal pressure and velocity are restored. This is not, however, true of the constricted arterial tube. Beyond the band the systolic pressure may be lowered, the diastolic pressure increased, and the pulse pressure greatly reduced for many months at least.

If the constriction of the aorta is very slight the effect upon the blood pressures is usually transient, the normal pressures being reestablished within a few hours or, indeed, minutes. But if the artery is constricted to the point of almost total occlusion the pulse pressure below the band, for a time almost nil, may remain lowered and the diastolic pressure, relatively or even actually, be increased. The blood stream in this case, passing with greater velocity and less pressure through the band prevents the obliteration of the artery to the nearest branch, the pocket being not a dead one as it is in the case of total obliteration. The blood in this pocket beyond the constriction streams in whirlpools, somewhat as in the vein and, also, as in the artery in arteriovenous fistula; the thrill, not palpable at first, later may be perceived with the finger; and the bruit, always audible with the stethoscope, becomes louder as the peripheral arterial resistance increases.

To these factors, then,—to the abnormal play of the blood in the relatively, as distinguished from the absolutely dead pocket and to the absence of normal pulse pressure, essential probably to the maintenance of the integrity of the arterial wall, we may have to look for the solution of our problem.

It is not, however, denied that the paralysis of the vasomotor nerves and the occlusion of the vasa vasorum may possibly play some part in the manifestation. The dilations produced experimentally, like those observed in cases of cervical rib, are, as I have said, circumscribed. We had conjectured that the delimitation of the dilation might be influenced or determined by the location of the branches of the affected artery beyond the constriction. In one instance,

however, we observed, just distal to a partially occluding band applied to the carotid low in the neck of a dog, a circumscribed dilation of this vessel, the branches of which had been tied and divided. In this case there was a long stretch of debranched and patulous carotid between its dilated portion and the base of the skull.

Do Intimal Surfaces Brought Gently in Contact Unite, and What Is the Process by Which Obliteration of an Artery Takes Place after Occlusion by Band or Ligature?

The intimal surfaces of arteries brought intact in apposition whether by ligature or by band never, in my experience, have united. This statement will be received sceptically, for it is at variance with the quite universally accepted view, that uncrushed intimal surfaces if brought gently in contact adhere and thus occlude the artery. In the ligation of the larger arteries we have been taught to use heavy ligatures, two or three abreast, and in tightening them to employ only enough force to bring the intimal surfaces in contact, a force not sufficient to rupture or injure the intimal coat. The gross and microscopic findings in the sections of arteries ligated in this manner have been repeatedly portrayed, but the illustrations submitted as proof are not convincing.

It is my opinion that the pressure necessary to bring about the complete closure of the aorta causes atrophy of the arterial wall under the band, and that union of the apposed surfaces thus deprived of their blood supply does not occur. To accord with this view, how is to be explained the formation of the fibrous cylinder which we occasionally find encompassed by the band, and how the probable error of other investigators who believe that intimal surfaces brought gently in contact by broad ligatures unite primarily and thus interrupt the blood stream?

The process of occlusion is, I believe, somewhat as follows: The death of the arterial wall having been brought about by the pressure of the band, a gradual substitution or organization of the necrotic tissue takes place, the new blood vessels penetrating it from both ends. The absorption of the lifeless wall proceeds coordinately with its vascularization or organization.

If the band has been rolled so tightly as to occlude the lumen, the arterial wall is deeply puckered or plicated. If after a month or two the aorta is cut open at this point, the folds of the arterial wall may still be seen. They will not be adherent to each other, but atrophied possibly to the thinness of writing or tissue paper. The attenuated wall can still be completely unfolded. In some cases it is found to be abnormally thick and a very fine lumen to have been established (Fig. 13). In this event there are no folds, the thick wall consisting altogether of new tissue, and the old wall with its plication having been absorbed. Consequent upon the atrophy of the arterial wall the tension under the band is eliminated, capillaries sprout into the necrotic part, which thus becomes replaced by new connective tissue. A tiny blood stream may make its way under the band, and an endothelial lining for the new wall develop.

More often we find in the completely or almost completely occluded cases that a solid, fibrous, cylindrical cord completely fills the space within the band and replaces the original wall of the artery.

Although we are unable to share the opinion of other investigators that the uninjured intimal surfaces of large arteries adhere to each other when brought in contact, the advice to bring broad surfaces in apposition by several contiguous, coarse ligatures is good. We have found that the finer the ligature the quicker it cuts through the artery, very fine silk cutting through in a day or two. Narrow tape, constricting the artery in spiral or cuff-like form, has about the same effect upon the arterial wall as the metal band. Under three or four coarse ligatures, drawn tightly enough to occlude the lumen but not so tightly as to injure the intima, the arterial wall would behave presumably as it does under the tape or band, and occlusion take place in the described manner. I should think, however, that it would be impossible in a given case to be sure that each one of three ligatures, for example, had occluded the artery without injury to the intima. Even with the metal band, which can be rolled with great precision and in perfect, cylindrical form, it is not possible to say that occlusion has no more than just been attained, although we can be certain that the intima has suffered no trauma. But with the ligature pressure cannot be exerted in such fine and exact gradations; there is also the complication of the knot and its particular pressure.

The surgeon's conceptions as to the finer processes concerned in the occlusion of arteries after ligature are based largely upon studies undertaken before the days of perfected asepsis, in the days when thrombus formation almost invariably complicated the picture.

SUMMARY.

1. A partially occluded artery may dilate distal to the site of constriction.
2. The dilation is circumscribed.
3. When the constriction has been either slight in amount or complete, dilation has not been observed.
4. The dilation was greatest when the lumen of the artery (the aorta) was reduced to one-third or perhaps one-fourth of its original size (Figs. 8 and 11).
5. Dilation or aneurysm of the subclavian artery has been observed twenty-seven or more times in cases of cervical rib.
6. The dilation of the subclavian is circumscribed, is distal to the point of constriction, and strikingly resembles the dilation which we have produced experimentally.
7. The genesis of the experimental dilation and of the subclavian dilation occurring with cervical rib is probably the same.
8. When the lumen of the aorta is considerably constricted the systolic pressure may be permanently so lowered and the diastolic pressure so increased that the pulse pressure is greatly diminished.³
9. The experimentally produced dilations and the aneurysms of the subclavian artery in cases of cervical rib are probably not due to vasomotor paralysis, trauma, or sudden variations in blood pressure.
10. The abnormal, whirlpool-like play of the blood in the relatively dead pocket just below the site of the constriction, and the lowered pulse pressure may be the chief factors concerned in the production of the dilations.
11. Intimal surfaces brought, however gently, in contact by bands or ligatures do not, in our experience, unite by first intention, for

³See Reid, M. R., *J. Exp. Med.*, 1916, xxiv, 287.

the force necessary to occlude the artery is sufficient to cause necrosis of the arterial wall.

12. Bands, rolled ever so tightly, do not rupture the intima.

13. The death of the arterial wall having been brought about by the pressure of the band, a gradual substitution of the necrotic tissue takes place, the new vessels penetrating it from both ends. It is, I believe, in this manner that an artery becomes occluded, and it is thus that a fibrous cord forms within the constricting band.

TABLE I.
Cases of Dilation of the Subclavian Artery with Cervical Rib.

Surgeon.	Publication.	Note on dilation of subclavian artery.	Remarks.
Mayo, H.	<i>London Med. and Phys. J.</i> , 1831, N. S., xi, 40.	Right subclavian artery flattened. Unusual width.	
1. Adams, R.	<i>Dublin J. Med. Sc.</i> , 1836, xvi, 494.	Ovoid dilation of 3rd portion, left subclavian, about size of pigeon's egg. Postmortem confirmation.	Radial pulses equal.
2. Warren, J. M.	<i>Am. J. Med. Sc.</i> , 1849, xvii, 13.	Aneurysmal tumor, left subclavian, about size of pigeon's egg.	Dec. 24, 1847. Ligation of 3rd portion. Ligature came away on 96th day.
3. Coote, H.	<i>Lancet</i> , 1861, i, 360.	Pulsating swelling of left subclavian, about size of walnut.	Part of cervical rib resected. Radial pulse hardly palpable before operation.
4. Poland, A.	<i>Med.-Chir. Tr.</i> , 1869, lii, 277.	Right subclavian—"Circumscribed dilatation of entire circumference."	"Digital compression on cardiac side of tumor for 96 hours." Cure of aneurysm.
5. Baum, W.	<i>Deutsch. Chir.</i> , 1880, Liefg. 34, 25. (Fischer, G.)	"Left subclavian aneurysm."	Ice, elevation of arm, compression. Aneurysm cured. Pulse absent in radial and ulnar, but present in brachial.
6. Gould, A. P.	<i>Tr. Clin. Soc.</i> , 1884, xvii, 95.	"Right subclavian artery projected even beyond clavicle as tense pulsating cylinder."	No operation. Progressive obliterative arteritis. Dilation uninfluenced.
7. Morris, W. C.	<i>Lancet</i> , 1885, ii, 152.	Fusiform aneurysm of right subclavian, $\frac{3}{4}$ in. in width.	Operation. Central ligation of 3rd portion. Radial pulse before operation weak—absent after operation—but reappeared in 1 month or less.

* Karg.	<i>Beitr. klin. Chir.</i> , 1895, xiv, 215. (Ehrlich, E.)	Aneurysm of left subclavian appeared after removal of the cervical rib.	Artery compressed between 2 cervical ribs. Both ribs removed. Aneurysm cured by compression.
8. Stifler.	<i>Munch. med. Woch.</i> , 1896, xliii, 544.	Pulsating tumor of left subclavian. Sud- den appearance.	Blood pressure, left 120; right 140. No operation.
9. Cohen, J.	Inaug. Diss., Göt- tingen, 1898.	"Left subclavian aneurysm size of plover's egg."†	"Weaker radial pulse." Fusiform dilata- tion.—"7 cm. long and 1½ fingers thick." Aneurysm excised.
10. Grisson.	<i>Fortschr. Geb. Rönt- genstrahlen</i> , 1898-99, ii, 103.	Right subclavian, "pulsating cord, thick- ness of little finger."	Pulseless axillary, brachial (hard cord), and radial. Aneurysm cured by suspension, Priesnitz bandage, etc.
11. Winkler, C.	<i>Nederl. Tyschr. Geneesk.</i> , 1904, xl, 589; <i>Munch. med. Woch.</i> , 1904, li, 2111.	Left subclavian—"Locally aneurysmally dilated."	Cyanosis of left hand.
12. Murphy, J. B.	<i>Ann. Surg.</i> , 1905, xli, 399.	Left subclavian "flattened and circular."	Brachial and radial pulses normal with arm extended. Operation. Dilation questioned by author in 1905, but called abnormal dilation in 1906.
? Murphy, J. B.	<i>Surg. Gynec. and Obst.</i> , 1906, iii, 514.	Right subclavian flattened out on surface of rib.	(Circulation?) Dilation questioned by author. (Exophthalmic goiter.)

TABLE I.—Continued.

Surgeon.	Publication.	Note on dilation of subclavian artery.	Remarks.
13. Conner, L.	<i>Med. Rec.</i> , 1906, lxxix, 775.	Left subclavian—"Broad pulsating mass suggestive of aneurysm."	No note as to circulation or treatment.
14. Keen, W. W.	<i>Am. J. Med. Sc.</i> , 1907, cxxxiii, 173.	Left subclavian dilated to nearly twice width of artery.	Gangrene. Operation. Cylindrical dilation to clavicle or beyond.
? Russel, C. K.	<i>Med. Rec.</i> , 1907, lxxi, 253.	<i>Autopsy Note.</i> —Right subclavian proximal to thyroid axis, large and soft; distal to this, contracted and cord-like. Left subclavian enlarged.	Gangrene. Amputation of index finger, and later of arm. Patient would not consent to operation on rib. Suicide.
? von Heinecke, W. H.	Inaug. Diss., Erlangen, 1907, 40. (Deitmar.)	Left subclavian "surprisingly broad."	Left radial pulse weaker than right, not improved by resection of rib.
* Halsted, W. S.	Unpublished (1909).	Dilation of right subclavian developed after removal of cervical rib.	The aneurysm, size of plover's egg, seemed to involve the artery central to the site of constriction.
15. Hamann, C. A.	<i>Cleveland Med. J.</i> , 1910, ix, 453.	Right subclavian beyond rib enlarged and filled with clot.	Gangrene of fingers. Bursa $\frac{3}{4}$ in. in diameter between artery and rib. Resection of part of the rib.
16. Pringle, J. H.	<i>Edinburgh Med. J.</i> , 1911, vii, 253.	Left subclavian—fusiform aneurysm distal to rib—sacculated at its proximal part under outer edge of scalenus.	Aneurysm twice needed (before discovery of rib). Finally opened and rib removed. Radial pulse "feeble;" became fair after operation.

17. Miller, J. L.	<i>Am. J. Med. Sc.</i> , 1911, cxlii, 811.	Side not stated. Slight dilatation above the notch in cervical rib.	Cyanosis of hand.
Galloway, J.	<i>Proc. Roy. Soc. Med.</i> , 1911-12, v, 112.	Left subclavian—"pulsating tumor."	Unoperated.
? Seymour, N. G.	<i>Am. J. Med. Sc.</i> , 1913, cxlvi, 396.	Right subclavian—small pulsating tumor, "simulating" aneurysm.	Female, 16 years. Radial pulse unaffected.
18. Law, A. A.	<i>J. Lancet</i> , 1914, xxxiv, 333.	"Right subclavian dilated distal to rib." "Left subclavian flattened."	Gangrene of fingers. Resection of rib on both sides.
19. Potter, C.	<i>J. Missouri Med. Assn.</i> , 1914-15, xi, 74.	Left subclavian—"Pouch-like dilatation of the wall of the artery over groove in cervical rib."	Male, 17 years. Ulcers and gangrene of thumb and ring finger. Brachial and radial pulses absent.

In the unnumbered cases the dilatation is questionable. In the cases marked with an asterisk the aneurysm appeared after removal of the rib.

† Possibly due to fracture of the clavicle.

EXPLANATION OF PLATES.

PLATE 16.

DOG 7, SERIES I. THE FIGURES ARE ACTUAL SIZE.

- FIG. 1. Aorta before the band was applied.
 FIG. 2. Immediately after application of the band.
 FIG. 3. 2 months thereafter.
 FIG. 4. 6 months and 19 days thereafter.

PLATE 17.

DOG 3, SERIES II. THE FIGURES ARE ACTUAL SIZE.

- FIG. 5. Aorta before the band was applied.
 FIG. 6. Immediately after application of the band.
 FIG. 7. 97 days thereafter.
 FIG. 8. 9 months thereafter. The outer of the two concentric circles indicates the circumference of the aorta at the site of the band before its application; the inner circle, the precise lumen of the aorta under the band when the dog was killed.

PLATE 18.

DOG 15, SERIES II. THE FIGURES ARE ACTUAL SIZE.

- FIG. 9. Aorta before the band was applied.
 FIG. 10. Immediately after application of the band.
 FIG. 11. 160 days thereafter. The outer of the two concentric circles indicates the circumference of the aorta at the site of the band before its application; the inner circle, the precise lumen of the aorta under the band when the dog was killed.

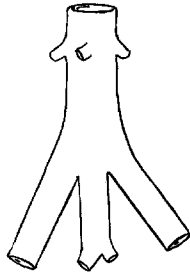
PLATE 19.

SECTION OF HUMAN INTERNAL CAROTID.

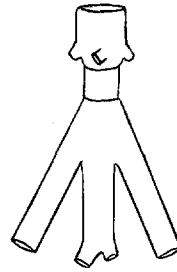
- FIG. 12. Section of human internal carotid, showing the process of obliteration after ligation of the common carotid. When removed at a subsequent operation this artery was found pulseless and almost empty notwithstanding the size of its lumen. $\times 25$.

DOG 9, SERIES II. THE FIGURE IS ACTUAL SIZE.

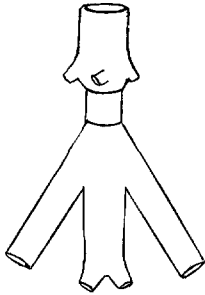
- FIG. 13. The band was rolled so tight as to shut off the palpable thrill but not the pulse. When killed after 6 months and 8 days the lumen at the lower edge of the band was 1.2 mm. in diameter. A new wall had been formed under the band, thick throughout, but particularly so at the lower and upper borders of the band. It is probable that, in this case, a fibrous cord ultimately would have formed.



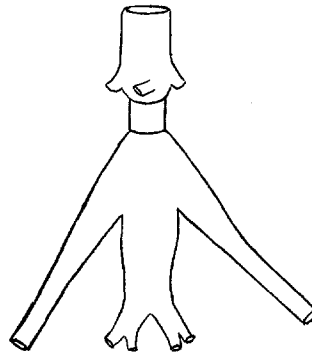
1



2

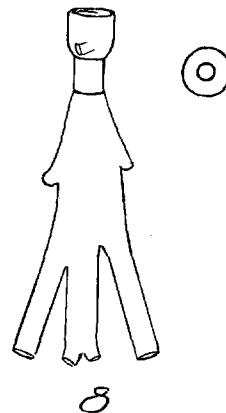
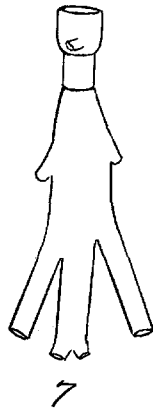
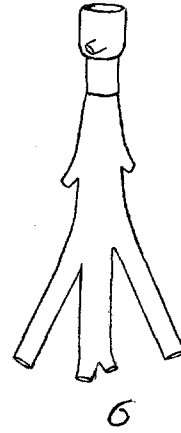
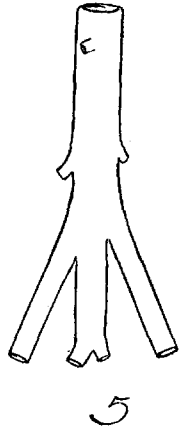


3

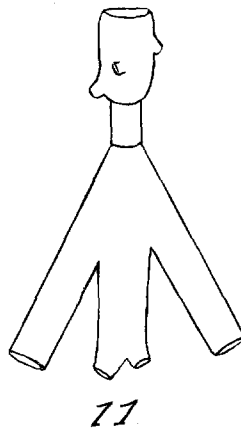
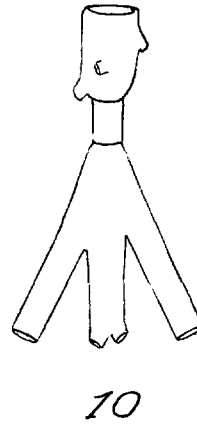
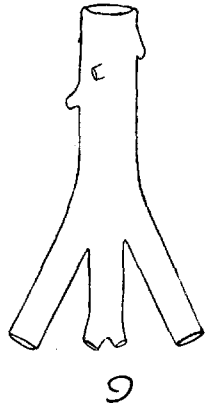


4


(Halsted: Circumscribed Dilation of an Artery.)



(Halsted: Circumscribed Dilation of an Artery.)



(Halsted: Circumscribed Dilation of an Artery.)



12



E. Norris.

13

(Halsted: Circumscribed Dilation of an Artery.)