


INSIGHTS

OTULIN and Muller’s morphs

András N. Spaan¹ 

In this issue of *JEM*, Davidson et al. (<https://doi.org/10.1084/jem.20222171>) and Takeda et al. (<https://doi.org/10.1084/jem.20231941>) independently report on a dominant negative form of OTULIN deficiency in three unrelated patients.

Autoinflammation is the term used to describe disorders of hyperactivation of the immune system in the absence of autoimmunity. Around 50 monogenic inborn errors of immunity are known to underlie autoinflammatory syndromes. In an apparent paradox, autoinflammation can be associated with immunodeficiency. This paradox is illustrated by human deficiencies of the linear ubiquitin homeostasis. Linear ubiquitin chains are linked by their N-terminal methionine residues and are involved in signal transduction, among others of the TNF-signaling pathway (Gerlach et al., 2011). Linear ubiquitin chains are assembled by the linear ubiquitin chain assembly complex (LUBAC), composed of the subunits HOIL-1L interacting protein (HOIP), HOIL-1, and SHANK-associated RH domain-interacting protein (Ikeda et al., 2011; Tokunaga et al., 2011). In return, the OTU deubiquitinase with linear linkage specificity (OTULIN) selectively hydrolyzes linear ubiquitin chains (Keusekotten et al., 2013; Rivkin et al., 2013). OTULIN also antagonizes autoubiquitination of LUBAC. LUBAC-deficient patients present a combination of autoinflammation and susceptibility to bacterial diseases (Boisson et al., 2012, 2015). Autosomal recessive OTULIN deficiency, in which both alleles are amorphs or severe hypomorphs, manifests early in life as the potentially lethal OTULIN-related autoinflammatory syndrome (ORAS) (Damgaard et al., 2016; Zhou et al., 2016). Autoinflammation in ORAS patients is largely driven by a defective down-

regulation of NF-κB-dependent signaling in hematopoietic cells. OTULIN haploinsufficiency, an autosomal dominant disorder in which one allele is amorphic or severely hypomorphic, instead predisposes to necrosis typically triggered by infections with *Staphylococcus aureus* (Spaan et al., 2022). This disorder underlies an increased susceptibility of tissue-resident, nonhematopoietic cells to the staphylococcal virulence factor α-toxin. The combination of autoinflammation and immunodeficiency seen in patients with LUBAC and OTULIN deficiencies highlights the complex role of linear ubiquitin in balancing inflammation and immunity.

Two independent papers in this issue of *JEM* now provide comprehensive evidence for an autosomal dominant OTULIN deficiency by means of negative dominance (Davidson et al., 2024; Takeda et al., 2024). The three reported patients manifested an ORAS-like disease but carried mono-allelic instead of bi-allelic disease-causing mutations in *OTULIN* (see Table 1). The patients’ missense variants were absent in public databases or ultra-rare, indicating that the consequences of the mutations are poorly tolerated at the population level. Indeed, segregation analyses indicated that these mutations had occurred de novo. Two of the three patients were born preterm, a feature also observed in ORAS patients. All three patients presented in the first months of life with systemic inflammation combined with panniculitis, pustulosis, and necrotic skin lesions requiring surgical debridement.



Insights from András N. Spaan.

Skin lesions occurred spontaneously or following minor trauma, and two neonates presented necrotizing omphalitis. Histological examinations of skin lesions showed neutrophilic infiltration. In two of the three patients, the clinical course during admission was accompanied by acute respiratory distress. Extensive microbiological cultures, albeit obtained under antibiotic treatment, remained nonexplanatory and the disease in the patients responded insufficiently to broad-spectrum antibiotics alone. Nonetheless, omphalic cultures taken from the necrotizing skin in two of the three patients returned low amounts of *S. aureus*. Besides leukocytosis with a marked neutrophilia and elevated C reactive protein (CRP) levels, routine systemic immunological diagnostics revealed no overt abnormalities. Steroids, started as a supportive measure, resulted in clinical improvement in all three patients

¹Department of Medical Microbiology, University Medical Center Utrecht, Utrecht University, Utrecht, Netherlands.

Correspondence to András N. Spaan: a.n.spaan@umcutrecht.nl

© 2024 Spaan. This article is distributed under the terms of an Attribution–Noncommercial–Share Alike–No Mirror Sites license for the first six months after the publication date (see <http://www.rupress.org/terms/>). After six months it is available under a Creative Commons License (Attribution–Noncommercial–Share Alike 4.0 International license, as described at <https://creativecommons.org/licenses/by-nc-sa/4.0/>).

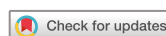

Table 1. Patient characteristics

		Patient 1	Patient 2	Patient 3
JEM report		Davidson et al., 2024	Davidson et al., 2024	Takeda et al., 2024
OTULIN allele		p.C129S	p.C129S	p.R306Q
Age	Gestational age at birth	31 wk	Full-term	33 wk
	Disease onset	4 days	7 mo	At birth
Manifestations	Skin	Necrotizing omphalitis; panniculitis; pathergy	Necrotizing fasciitis; panniculitis	Necrotizing omphalitis; pustulosis
	Lungs	Acute respiratory distress	Recurrent respiratory tract infections	Acute respiratory distress
Laboratory results	Inflammation	Neutrophilia; monocytosis; thrombocytopenia; elevated CRP	Neutrophilia; elevated CRP	Neutrophilia; thrombocytosis; elevated CRP
	Autoimmunity	Not reported	Absent	Absent
	Cultures	<i>S. aureus</i> (trace)	Negative	<i>S. aureus</i> (trace)
Treatment (response)		Steroids (+); Adalimumab (+); antibiotics (±)	Steroids (+); Infliximab (+); antibiotics (±)	Steroids (+); Etanercept (+); antibiotics (±)

and long-term resolution was achieved with TNF inhibitors (see Table 1). Although TNF inhibition continues to serve as a therapeutic backbone, the addition of supportive or prophylactic antibiotics has resulted in the further clinical improvement in two of the three patients.

Linear ubiquitin accumulated in cells from all patients and the cells were—similar to cells from ORAS patients but in contrast to cells from OTULIN-haploinsufficient patients—susceptible to TNF-induced cell death. Given the autoinflammatory features reminiscent of autosomal recessive OTULIN deficiency, the authors considered negative dominance of the alleles carried by their patients in heterozygosity. For negative dominance to occur, the wild type and antimorphic proteins must both be expressed. Indeed, wild type and mutant proteins were detected in equal amounts in the patients' cells. OTULIN has two functional domains: the N-terminal PUB-interactive motif domain responsible for binding to HOIP, and the C-terminal OTU domain harboring the catalytic sites (Keusekotten et al., 2013). The catalytic triad, formed by amino acid residues at positions 129, 339, and 341 in the OTU domain, is conformationally assisted by ubiquitin binding sites elsewhere in the OTU domain. In two patients, the different genomic mutations resulted in the same amino acid substitution in one of the catalytic sites

(p.Cys129Ser). Although this variant had very high affinity for linear ubiquitin, it failed to hydrolyze it. The amino acid residue affected by the mutation in the third patient (p.Arg306Gln) is thought to play a role in linking ubiquitin binding and active center formation, and this allele combined an impaired ubiquitin binding capacity with a reduced hydrolytic activity. Using complementary biochemical approaches, both mutant alleles were shown to suppress the wild type protein in a dosage-dependent manner by antagonizing its capacity to hydrolyze linear ubiquitin and to downregulate TNF-induced NF- κ B signaling. Further establishing causality, negative dominance was reversed in cells from one patient by gene editing of the antimorphic allele into wild type.

Based on the elegant experimental proof provided by both teams, negative dominant OTULIN deficiency can now be established as the molecular explanation for the ORAS-like phenotype in their patients. But how do the patients' mutant alleles exert their antimorphic nature over the wild type allele? OTULIN exists in at least two cellular pools: a free cytosolic fraction, and one in complex with LUBAC (Elliott et al., 2014). In a series of well-conducted experiments with complementary readouts, the p.Cys129Ser variant acted by negative dominance in a cellular but not in a purified system, indicating that this allele exercises its negative dominance at the

interface of OTULIN and LUBAC. In patient cells, LUBAC was “quenched” by the high-affinity but catalytically inactive p.Cys129Ser protein. Based on the mutual exclusiveness for OTULIN and the combined lysine-63 and linear ubiquitin-specific deubiquitinase CYLD (via SPATA2) to bind HOIP (Draber et al., 2015), crosstalk with other polyubiquitin chains is expected. Negative dominance of the p.Arg306Gln allele was tested in cellular assays only, and no abnormal binding to LUBAC was detected. The molecular mechanism of negative dominance of the p.Arg306Gln variant remains, thus, to be elucidated. Nonetheless, both OTULIN antimorphs promote autoubiquitination of LUBAC, and dysregulation of LUBAC likely underlies the inflammatory sequelae observed in the patients. If negative dominance of these OTULIN alleles is exclusively exerted at the LUBAC interface, the patients are haploinsufficient in their free OTULIN pool. Such a pool-dependent deficiency may explain the observed partial phenotypic overlaps with autosomal recessive OTULIN deficiency and OTULIN haploinsufficiency. Collectively, the two human studies in this issue of JEM offer a starting point to uncouple the roles of the different cellular OTULIN fractions at the molecular level.

OTULIN is a fascinating molecule, and the human gene encoding it is just as remarkable. The phenotypes associated

with OTULIN deficiencies offer a portfolio of genetic archetypes, as these diseases span the spectrum of inheritance with an autosomal recessive disorder and now two distinct autosomal dominant disorders: negative dominance and haploinsufficiency. Of the two dominant traits, OTULIN haploinsufficiency includes the 5p- chromosomal deletion syndrome and demonstrates nature's complexity with its incomplete penetrance, variable expressivity, and phenotypic heterogeneity (Spaan et al., 2022). The intermediate accumulation of linear ubiquitin seen in patients with OTULIN haploinsufficiency, insufficient to provoke TNF-induced cell death but sufficient to derange crosstalk with other ubiquitin ligases and hydrolases, suggests that OTULIN acts in a cell type- and gene dosage-dependent manner. By studying additional patients, future research will reveal more clinical and biological details of the overlap and differences between autosomal recessive and dominant negative OTULIN deficiency, and OTULIN haploinsufficiency. It remains to be proven by the study of experiments of nature if patients carrying bi-allelic, mildly hypomorphic alleles phenocopy OTULIN haploinsufficiency. Similarly, phenotypic consequences of the two

remaining Muller's morphs (Muller, 1932) remain to be revealed in humans: hypermorphs and neomorphs, which may underlie OTULIN-related gain-of-function diseases. Given the intricate and complex role of OTULIN in maintaining the cellular linear ubiquitin homeostasis, it is probably oversimplified to expect a phenocopy of the LUBAC deficiencies. Rather, an OTULIN-related gain-of-function disorder may be cell type or stimulus dependent. Moreover, the future study of OTULIN in human disease might reveal other, as of today unknown, functions of OTULIN.

The combination of autoinflammation and immunodeficiency, seen in LUBAC and OTULIN deficiencies, is less contradictory when considering the triggers inducing hyperinflammation. These triggers being mechanic (traumas), infectious (the staphylococcal α -toxin), or unknown (with apparently spontaneous disease), the threshold to respond with inflammation is governed by linear ubiquitin. This threshold is cell type specific, as demonstrated by the cell-intrinsic defect of immunity in OTULIN haploinsufficiency. Future studies will have to reveal in more detail the nature and sequential order of the cells contributing to the hyperinflammatory states in the OTULIN deficiencies.

Acknowledgments

This work was in part supported by the Dutch Research Council, project number 09150172110006.

Disclosures: The author declares no competing financial interests.

References

- Boisson, B., et al. 2015. *J. Exp. Med.* <https://doi.org/10.1084/jem.20141130>
- Boisson, B., et al. 2012. *Nat. Immunol.* <https://doi.org/10.1038/ni.2457>
- Damgaard, R.B., et al. 2016. *Cell.* <https://doi.org/10.1016/j.cell.2016.07.019>
- Davidson, S., et al. 2024. *J. Exp. Med.* <https://doi.org/10.1084/jem.20222171>
- Draber, P., et al. 2015. *Cell Rep.* <https://doi.org/10.1016/j.celrep.2015.11.009>
- Elliott, P.R., 2014. *Mol. Cell.* <https://doi.org/10.1016/j.molcel.2014.03.018>
- Gerlach, B., et al. 2011. *Nature.* <https://doi.org/10.1038/nature09816>
- Ikeda, F., et al. 2011. *Nature.* <https://doi.org/10.1038/nature09814>
- Keusekotten, K., et al. 2013. *Cell.* <https://doi.org/10.1016/j.cell.2013.05.014>
- Muller, H.M. 1932. Further Studies on the Nature and Causes of Gene Mutations.
- Rivkin, E., et al. 2013. *Nature.* <https://doi.org/10.1038/nature12296>
- Spaan, A.N., et al. 2022. *Science.* <https://doi.org/10.1126/science.abm6380>
- Takeda, Y., et al. 2024. *J. Exp. Med.* <https://doi.org/10.1084/jem.20231941>
- Tokunaga, F., et al. 2011. *Nature.* <https://doi.org/10.1038/nature09815>
- Zhou, Q., et al. 2016. *Proc. Natl. Acad. Sci. USA.* <https://doi.org/10.1073/pnas.1612594113>