

EXPERIMENTS ON THE CULTIVATION OF SO CALLED TRACHOMA BODIES.*

BY HIDEYO NOGUCHI, M.D., AND MARTIN COHEN, M.D.

(From the Laboratories of The Rockefeller Institute for Medical Research,
New York.)

PLATE 46.

In 1907 von Prowazek and Halberstaedter¹ described certain cell inclusions in the conjunctival epithelia of persons suffering from trachoma. The inclusions were composed of coarse coccoid and more numerous minute granular bodies that were partially embedded in an irregular, indefinite, and homogeneous substance or matrix. The coarser bodies stained bluish and the minute ones reddish in Giemsa solution. When the scrapings from the conjunctiva showing the cell inclusions were introduced into the eye of orangoutangs there appeared after several days in the conjunctiva similar inclusions accompanied by a mild form of conjunctivitis. The two disappeared together. von Prowazek and Halberstaedter concluded that the inclusions are the etiological agents of trachoma; and von Prowazek has proposed for them the name of chlamydozoa.

This discovery was speedily confirmed, and the bodies were viewed as the etiological cause of trachoma when von Prowazek and Halberstaedter² detected similar inclusions in the conjunctiva in cases of uncomplicated blennorrhoea neonatorum. Thus a discussion arose as to the specificity of the trachoma bodies, and Herzog advanced the theory³ that under certain conditions the gonococcus undergoes transformation into small forms which, when accumulated within the protoplasm of epithelia, assume the appearance of so called trachoma bodies. Herzog believed that this transformation was accomplished by a rapid succession of transplantations of

* Received for publication, July 1, 1913.

¹ Halberstaedter, L., and von Prowazek, S., *Deutsch. med. Wchnschr.*, 1907, xxxiii, 1285; *Arb. a. d. k. Gsndhtsamte.*, 1907, xxvi, 44.

² Halberstaedter, L., and von Prowazek, S., *Berl. klin. Wchnschr.*, 1909, xlv, 1110.

³ Herzog, H., *Arch. f. Ophth.*, 1910, lxxiv, 520.

the gonococcus *in vitro*, and he stated that trachoma is caused by infection with the transformed or mutated gonococcus (his microgonococcus). The present authors⁴ studied cell inclusions in various conjunctival affections, and came to view the trachoma bodies as a definite pathogenic organism which can bring about a fairly well defined clinical condition peculiar to itself. They regarded the occasional occurrence in gonorrhoeal conjunctivitis of the gonococcus and the trachoma inclusion bodies as accidental and coincidental; and they considered that this coincidence could not be explained by the transformation of the gonococcus into the trachoma bodies or that the two separate etiological factors operate to produce trachoma. Williams,⁵ on the other hand, has come to regard the inclusion as degenerated forms of the Koch-Week's bacillus.

Hence it appears that the so called trachoma bodies have been treated as definitely living organisms by von Prowazek who regards them as a new protozoan; by Herzog who considers them a mutated gonococcus; and by Williams who regards them as degenerated Koch-Week's bacilli. Others consider them to be parasitic without definite orientation, and still others as products of degeneration, due to the invasion of cells by a still undetected etiological agent, analogous to those found in carcinoma, variola, rabies, and some other diseases. It has not been shown that the inclusions are the parasites themselves, and in order to settle this point proof must be brought that they are actually living, for which cultivation outside the body supplies the clearest evidence. What follows is in the nature of a preliminary report of our studies, in which the clinical part has been contributed by Cohen and the cultural by Noguchi.

Sources of Materials.—Three different groups of conjunctival affections were selected: (1) cases of conjunctivitis combined with so called trachoma body inclusions;⁶ (2) cases of typical trachoma without the so called trachoma bodies; (3) cases of acute catarrhal conjunctivitis in which neither trachoma nor the cell inclusion affection occurred. To obtain the material the lid was inverted and carefully rinsed with sterile physiological salt solution, after which the

⁴ Noguchi, H., and Cohen, M., *Arch. Ophth.*, 1911, xl, 1.

⁵ Williams, A. W., *Arch. Ophth.*, 1913, xlii, 506.

⁶ Cohen, M., *Arch. Ophth.*, 1913, xlii, 29.

surface of the conjunctiva was scraped with the edge of a sterile slide. The scraping was collected with a sterile platinum spatule and mixed in a tube with a small quantity of sterile ascitic fluid. In old trachoma cases where the conjunctivæ and tarsi were removed the tissues were immersed in a small amount of ascitic fluid to prevent desiccation. The materials were carried to the laboratory without delay.

Cultivation.—The usual culture media and methods were first employed without success. Then the procedure used for cultivating spirochætæ was adopted.⁷ The scraping or piece of tissue was placed in a culture tube in which a piece of fresh sterile animal tissue (rabbit kidney) and a large quantity of sterile ascitic fluid were already present. The tube employed measures 1.2 by 20 centimeters, and the amount of ascitic fluid used is about ten cubic centimeters in each tube. After the inoculation a layer of sterile paraffin oil (two or three centimeters high) is poured upon the ascitic fluid and the tube is placed in an anaerobic jar. Usually two or three tubes are made with each specimen of scraping or tissue, and several specimens cultured on each occasion. Cultivation is conducted at 37° C.

The organism to be described was isolated in all cases of conjunctivitis with cell inclusions, and in one of three cases of trachoma without the inclusions. It was absent from all the control cases. The fact should be emphasized that the organism could not be cultivated at each trial, but at times repeated attempts were necessary for success. The failure with old cases of trachoma may be due to the removal of conjunctivæ and tarsi, so that further attempts at cultivation could not be made.

The tubes remain in the anaerobic apparatus about ten days, at which time films from each tube are made by removing the fluid with a sterile capillary Pasteur pipette. The air-dried films are fixed in methyl alcohol (Merck's reagent) for thirty minutes and stained with Giemsa solution for one hour. Films from cultures in which the inclusion bodies are growing show many extremely minute coccoid organisms, mostly in pairs, but some in heaps of varying numbers. The cultures contain, of course, ordinary bacteria, such

⁷ Noguchi, H., *Jour. Exper. Med.*, 1912, xvi, 199, 211.

as staphylococci, streptococci, diplococci and certain bacilli; but the minute size of the inclusion bodies and their reddish stain enables one to recognize them without much difficulty.

The purification of the culture is the most tedious phase of the work, and much patience is required to accomplish it. The cultures usually contain many organisms growing profusely on the surface of the ascitic fluid agar, while the colonies of the inclusion organism are slow to develop and extremely minute. They do not attain a size easily visible to the naked eye, and as they are almost transparent are easily overlooked. They do not grow on the surface of the agar unless ascitic fluid or other suitable serum components are present. The medium found best suited thus far consists of two parts of slightly alkaline beef infusion agar and one part of ascitic fluid with 0.5 per cent. of glucose. To obtain colonies sufficiently isolated for fishing many dilutions of the original culture must be made; and inoculation may be made in the anaerobic apparatus or without it, but the former gives better results, since certain aerobic organisms are partially or completely prevented from developing. The minute organism is a facultative anaerobe which during the first two or three generations grows better in the absence of oxygen, while in later generations it is unaffected by the air.

In order to obtain pure growth a culture showing discrete, almost invisible colonies is selected, and by means of a fine platinum needle a single colony is touched and transferred to a new tube of medium containing a piece of sterile kidney and ascitic fluid. The sterile paraffin oil having been added, the tube is placed at 37° C. From now on the anaerobic apparatus is not employed. When transfers are made into various other media without the addition of fresh tissue the result is usually negative. For some generations the organism fails to grow on the surface of agar even when ascitic fluid and glucose are present.

After three or four days the fluid culture shows slight turbidity about the tissue, but no gross change takes place. Films made from the bottom of the tube and stained with Giemsa solution reveal the organism, usually in two main and many intermediate forms. The first form consists of rather large, lanceolate, or ovoid bodies, some occurring singly, others in pairs and groups or rosettes (figures 3,

4, and 5). The second variety are extremely minute, round or somewhat ovoid in shape, arranged usually in heaps or pairs (figures 17 and 18). The coarse forms take a blue, the finer a red stain. The two forms may be separate, but usually occur mingled in a single mass, the coarser occupying the outer and the minuter bodies the inner zone. A few coarse forms may lie among the minute ones, the two thus representing a typical trachoma body. Intermediate forms are always present, but they appear merely to constitute a stage during which the coarse forms are undergoing transformation into minute granules (figures 9, 10, 13, and 14). By starting with a single colony and following its development day by day it can easily be demonstrated that the different morphological elements are not due to contamination one with another. The coarse bodies predominate during the first two days, and are replaced by the minute ones. A comparison between the cultivated organism and the cell inclusions in corresponding developmental stages reveals a striking similarity (figures 1, 2, 6, 7, 8, 11, 12, 15, and 16).

Although when freshly isolated the organism grows best under anaerobic conditions, after several generations a good growth may be obtained in the presence of oxygen. During the anaerobic period the organism develops only in media containing animal protein, but after it has become aerobic it will grow without the addition of serum, although development is less free than when the latter is present. The colonies developed on the surface of the agar slant vary according to the degree of removal from the parent culture. Thus, during the anaerobic phase the colonies assume the appearance of minute, transparent, and almost invisible specks, whereas in the aerobic phase they are more distinct, though still extremely minute. In the depth of the agar they develop throughout the entire column within forty-eight hours as minute specks of greyish white color. No turbidity is produced in serum agar and no gas in glucose media. In neutral or slightly alkaline bouillon (beef infusion, peptone) the organism grows slowly in fine, powdery, slightly opalescent masses. The tissue at the bottom (if such has been added) becomes pale and grey. No odor is produced in any medium. The best medium is ascitic fluid tissue, covered with a layer of paraffin oil, in which the

organism grows well after forty-eight hours, the organisms remaining transplantable for a period of two months at 37° C. Blood is not hemolyzed.

Morphological Properties.—This organism is Gram amphiol and throws off the stain completely if decolorized long enough. It is distinctly stained by carbolized fuchsin or gentian violet, and only faintly by Loeffler's methylene-blue.

Various strains obtained from different cases present slight morphological deviations, and a strain obtained from one patient may appear somewhat coarser than that derived from another. The initial body forms may be arranged in rosettes or in irregular heaps, or even in short chains. The individuals in some strains are more round or oval in shape, and in others preponderatingly spindle-shaped, triangular, or crescentic. When the organism enters upon the elementary body stage some strains form much more minute granules than others. Similar variations occur among the cell inclusions which exist in cases of trachoma, blennorrhoea neonatorum, and inclusion conjunctivitis.

Animal Inoculation.—Repeated attempts to produce the cell inclusions in various kinds of monkeys (*Macacus* and *Papio*) by means of pure cultures of this organism failed. In some instances a transient papillary conjunctivitis lasting about one week was produced, but the films showed only initial body forms, without cell inclusions.

SUMMARY.

1. An organism was isolated and studied in pure cultures from cases of conjunctivitis accompanied by the so called trachoma body inclusions, as well as from a case of old trachoma without inclusions.
2. This organism was not found in the cultures made from other forms of conjunctivitis in which the inclusions were absent.
3. The organism presents the morphological features characteristic of so called trachoma bodies. It undergoes an early transformation, during which the forms known as initial bodies appear, and a later change, during which forms resembling elementary granules arise, while certain intermediate forms between these occur simultaneously.
4. No definite cell inclusions could be produced in monkeys by inoculating pure cultures of the organism.

5. The cultivation of this organism from a case of trachoma without the cell inclusions, together with the previously ascertained fact that the inclusions can be produced in suitable animals by inoculating such material directly from a human case, suggests the possibility of the organism being still present in such cases of trachoma, although not in the form of cell inclusions.

6. The facts presented justify the statement that by a suitable method an organism resembling the various important stages of the trachoma bodies and totally distinct from the gonococcus has been obtained in a living condition capable of indefinite cultivation from cases of human trachoma and inclusion conjunctivitis. Whether the organism and trachoma bodies are identical cannot be positively stated at present. But the way is now opened to determine this point, as well as the specificity of the trachoma bodies.

EXPLANATION OF PLATE 46.

All the figures are from film preparations stained with Giemsa solution. Magnification $\times 1,000$.

FIG. 1. Initial stage of the so called trachoma bodies in a conjunctival epithelium from a case of trachoma.

FIG. 2. Similar inclusion from a case of so called inclusion conjunctivitis.

FIGS. 3, 4, and 5. Initial stage of the cultivated organism, forty-eight hours old in ascitic fluid tissue media.

FIGS. 6 and 7. Intermediary stages of the trachoma bodies from a case of trachoma.

FIG. 8. Intermediary stage of similar inclusion from a case of so called inclusion conjunctivitis.

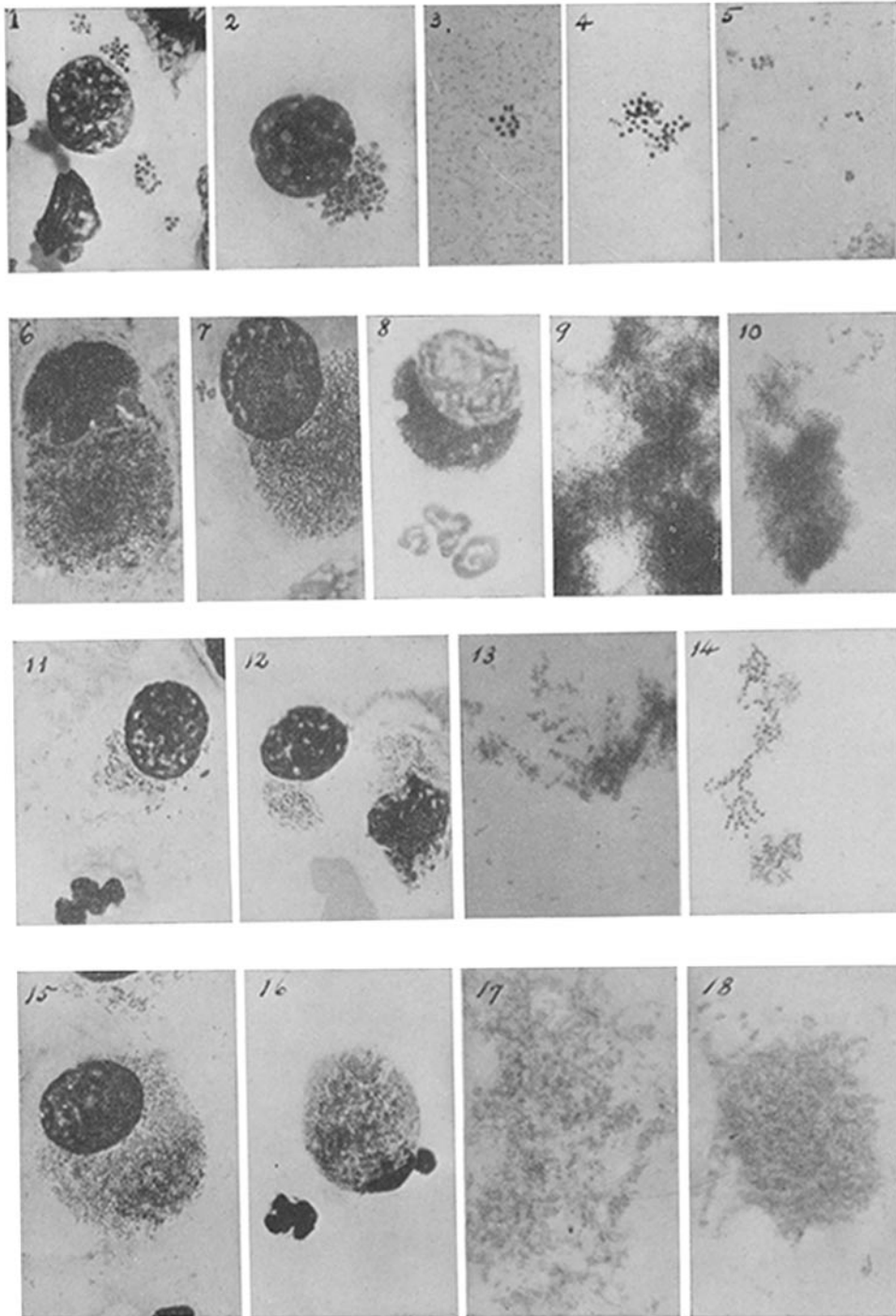
FIGS. 9 and 10. Intermediary stage of the cultivated organism, three to four days old in ascitic fluid tissue media.

FIGS. 11 and 12. Inclusions consisting of intermediary and elementary forms of the trachoma bodies, from a case of trachoma and one of inclusion conjunctivitis.

FIGS. 13 and 14. The cultivated organism showing stages where intermediary and elementary forms are mingled, four to five days in ascitic fluid tissue media.

FIGS. 15 and 16. Inclusions consisting exclusively of minute (elementary) granules from similar cases.

FIGS. 17 and 18. The cultivated organism which entered the stage corresponding to the elementary granules of the inclusions, seven days in ascitic fluid tissue media.



(Noguchi and Cohen : Cultivation of So Called Trachoma Bodies.)