

TUMOR NECROSIS FACTOR/CACHECTIN PLAYS A KEY ROLE IN BLEOMYCIN-INDUCED PNEUMOPATHY AND FIBROSIS

BY PIERRE F. PIGUET, MARTINE A. COLLART, GEORGES E. GRAU,
YUSUF KAPANCI, AND PIERRE VASSALLI

From the Department of Pathology, University of Geneva, 1211 Geneva, Switzerland

Pulmonary fibrosis corresponds to the end stage of various pulmonary diseases that are characterized by the growth of fibroblasts and the increase of collagen deposition within the alveolar walls (reviewed in references 1-3). Their pathogenesis is poorly understood and the involvement of fibroblast growth factors, known to be produced by alveolar macrophages, is suspected (4, 5). TNF- α /cachectin is one of the cytokines produced by macrophages activated by inflammatory agents such as bacterial LPS. TNF has a wide range of activities (reviewed in references 6 and 7), one of these being a growth-promoting activity upon fibroblast cell lines (8). In vivo, we recently found that a continuous infusion of TNF within the hypodermis stimulated the growth of fibroblasts and led to an increase of the local collagen deposition (Piguet, P. F., G. E. Grau, and P. Vassalli, manuscript submitted for publication).

Bleomycin corresponds to a group of glycopeptides that are used for the chemotherapy of cancer, a therapy that is, however, limited by the occurrence of pulmonary fibrosis. In rodents the administration of bleomycin has been extensively used as a model of pulmonary fibrosis (reviewed in reference 2). In the present study, the role of TNF in the bleomycin-induced pneumopathy and fibrosis was investigated. The evolution of the fibrotic process was found to be associated with an increase in the level of lung TNF mRNA, suggesting an increase in local TNF production. Furthermore, injection of rabbit anti-TNF antibody markedly prevented the development of pulmonary lesions and fibrosis. These experiments are consistent with a key role for TNF in at least some types of pulmonary fibrosis.

Materials and Methods

Mice. CBA/Ca and C57BL/10 (B10) mice were purchased from OLAC Ltd. (Blackthorn, UK) and bred for two to three generations in our animal facilities.

Bleomycin Administration. Bleomycin (Lundbeck AVS, Copenhagen, Denmark) was dissolved in HBSS and 0.1 U in 0.1 ml was injected intratracheally. 0.1 U of bleomycin contained 1 ng of LPS in a limulus amoebocyte lysate assay. The controls were injected with HBSS only. Continuous intraperitoneal administration was performed using an Alzet osmotic minipump (no. 2002 Alza Corp., Palo Alto, CA) delivering a total dose of 2 U within 15 d.

Deletion of the CD4⁺ (L3T4⁺) and CD8⁺ (Lyt-2⁺) T Lymphocyte Subsets. Mice were injected every other day with ascitic fluid produced by hybridoma H-35-17.2, a rat IgG2b anti-CD8,

This work was supported by grant 3.650.87 from the Swiss National Science Foundation.

or GK 1.5, a rat IgG2b anti-CD4, as described previously (9). The controls were injected with HBSS only.

Assay for TNF. TNF activity was determined using the lysis of the L929 cell line (10).

Light and Electron Microscopy. The lungs were fixed by intracheal instillation of formol sublimate and embedded within paraffin. Sections were stained by the hematoxylin-eosin and Masson trichrome stains. For a semiquantitative evaluation of the extent of lung damage, sections from the right and left lung of individual mice were projected on a multipurpose grid with 168 points. The number of points falling on normal or severely damaged tissue was established. This gave an approximative evaluation of the percentage of damaged parenchyma. For embedding in epon, the lungs were fixed by intratracheal instillation of 2% glutaraldehyde in cacodylate buffer (0.1 M, pH 7.2). Sections were prepared from three blocks from the left lung for each individual mouse and were stained with toluidine blue. For EM, 700-A ultrathin sections were stained with 1% uranyl acetate in 100% methanol and lead citrate and were examined with an electron microscope (400; Philips Electronic Instruments, Inc., Mahwah, NJ) at 80 Kv.

Northern Blot Analysis of TNF- α , IL-1- α , and Granulocyte-macrophage CSF (GM-CSF)¹ mRNAs in Total Lung RNA. The lungs were washed with saline and frozen in liquid nitrogen. They were subsequently thawed by mincing in a guanidine-thiocyanate solution and the total lung RNA was isolated by guanidine-thiocyanate/cesium chloride centrifugation (11). Northern blots were performed as described elsewhere (12). Briefly, RNAs denatured with glyoxal were separated on 1.2% agarose gels (4 μ g/lane) and were transferred onto nylon membranes. Equality of sample loading and efficiency of the transfer were controlled by staining with methylene blue. Filters were hybridized with ³²P-labeled cRNA probes (13). The probes for TNF- α , IL-1- α , and GM-CSF have been described elsewhere (12, 13).

Rabbit Anti-mouse TNF Antibodies. Mouse rTNF- α was a kind gift from B. Allet Glaxo, IMB, Geneva, Switzerland. Purification of the cytokine and the preparation of rabbit anti-TNF antibody have been described previously (14). IgG fraction from anti-TNF or normal serum were deaggregated by ultracentrifugation at 150,000 g for 150 min, and 1 mg was injected intravenously.

Evaluation of the Lung Hydroxyproline Content. The total lung hydroxyproline concentration was determined using described methods (15). Briefly, the lungs were submitted to an acid hydrolysis, the hydrolysate was neutralized, extracted with phenol-chloroform-isoamylalcohol, and the hydroxyproline concentration was determined colorimetrically (15).

Statistical Evaluation. Statistical analysis was performed using the nonparametric Mann-Whitney U test.

Results

Intratracheal Instillation of Bleomycin Increases the TNF mRNA Level in the Lung Whereas Those of Interleukin 1 and GM-CSF Remain Undetectable. Bleomycin administration did not lead to a detectable increase of the serum TNF activity (not shown). However, evidence for a local increase of TNF production was provided by the analysis of the lung TNF mRNA level. RNA from the lungs of individual mice were extracted and analyzed by Northern blot hybridization at various times after intracheal instillation of bleomycin (Fig. 1). An increase of TNF mRNA level was not apparent 2 d after bleomycin instillation (not shown), but was detectable in 12 mice killed between day 5 and 15 (Fig. 1). In contrast, the mRNAs for IL-1 and GM-CSF were not detectable after instillation of bleomycin, but evident 1–2 h after LPS injection (Fig. 2).

Influence of Anti-TNF- α Antibody upon the Systemic and Pulmonary Effects of Bleomycin Administration. 1 mg of control or anti-TNF IgG was injected on days 1 and 8 after

¹ Abbreviation used in this paper: GM-CSF, granulocyte-macrophage CSF.

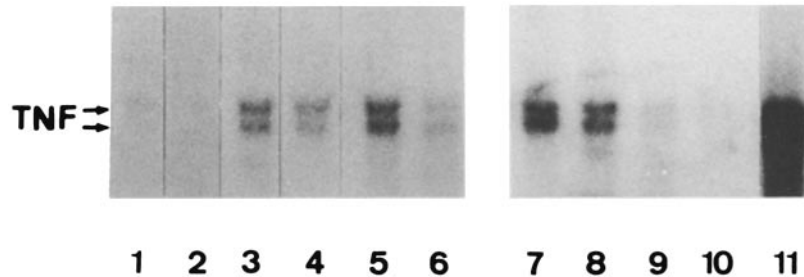


FIGURE 1. After isolation of the total lung RNA from individual mice, TNF- α mRNA was detected by Northern blot hybridization (4 μ g/lane). (Lanes 1 and 2) Mice killed 5 d after an intratracheal instillation of solvent; (lanes 3 and 4) 5 d after 0.1 U of bleomycin; (lanes 5 and 6) 15 d after 0.1 U of bleomycin; (lanes 7-10) mice instilled with bleomycin and treated with solvent (lanes 7 and 8) or anti-CD4 plus anti-CD8 mAb (lanes 9 and 10) and killed on day 5; (lane 11) mouse killed 90 min after an intravenous injection of 200 μ g of *Escherichia coli* LPS. Arrows indicate the position of the TNF mRNA.

the intratracheal administration of 0.1 U of bleomycin, and the mice were killed on day 15. Anti-TNF activity was detectable in the serum during the treatment (14). The bleomycin instillation induced some mortality, ranging between 0 and 30% in different experiments, and this was not significantly affected by the treatment with anti-TNF IgG (not shown). Study of histological sections suggested that mortality was related either to extensive lung damage (see below) or to infectious complications that were occasionally observed in mice receiving anti-TNF IgG. Indeed, this treatment is known to compromise the resistance to some bacteria (16). Bleomycin administration also led to a weight loss that was partially prevented by anti-TNF antibody. The body weight of the saline instilled controls were of 77% (\pm 12) or 85% (\pm 17) for the mice treated with nonimmune or anti-TNF IgG, respectively (mean \pm SD on day 15 after bleomycin intratracheal instillation, difference not significant at $p > 0.05$).

Study of the lung by light microscopy 15 d after intratracheal instillation of bleomycin

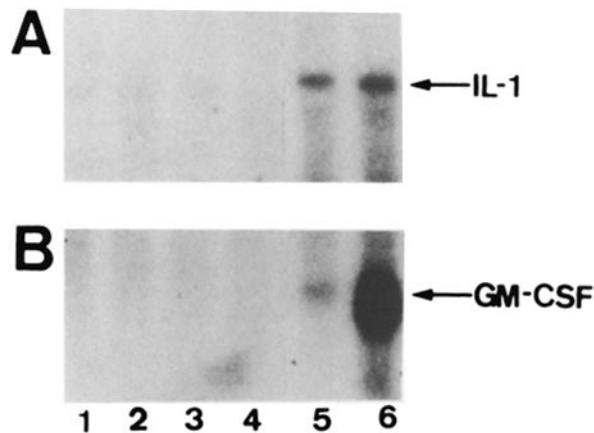


FIGURE 2. Expression of IL-1- α and GM-CSF mRNA in the whole lung RNA. (Lanes 1 and 2) Mice instilled with the solvent; (lanes 3 and 4) with bleomycin; (lanes 5 and 6) mice killed 30 and 90 min after an intravenous injection of 200 μ g of *E. coli* LPS. Arrow indicates the position of the GM-CSF and IL-1 mRNA.

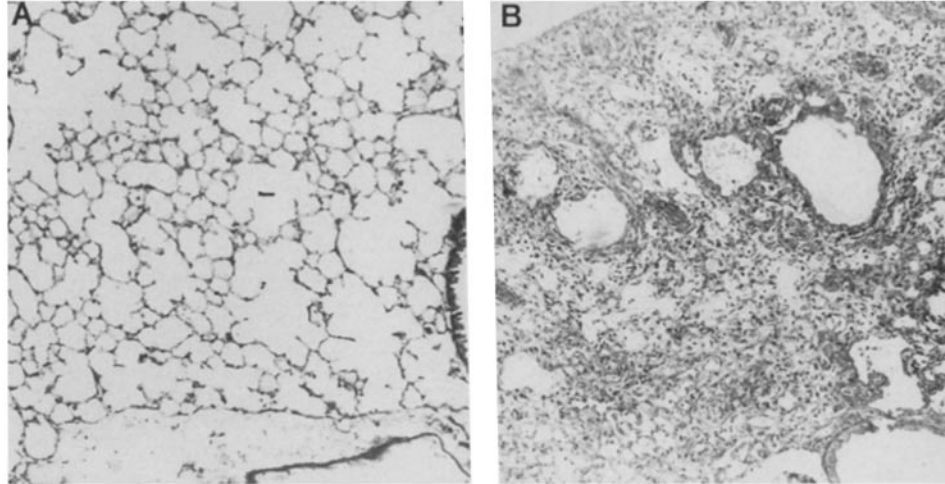


FIGURE 3. Histologic sections from the left lung of CBA mice 15 d after an intratracheal instillation of 0.1 U of bleomycin and treated with anti-TNF (A) or control (B) IgG ($\times 40$).

showed areas of increase of the cellularity of the alveolar septa associated with a total disruption of the alveolar architecture (Fig. 3). Collagen deposition, revealed with the trichrome stain, was seen in the most severely damaged area. Because of their heterogeneity in the different lobes, these alterations were difficult to quantify. Sections from the right and left lungs of seven mice treated with anti-TNF or nonimmune IgG were examined. The severely damaged area (i.e., disruption of the alveolae and presence of collagen) represented $45 (\pm 25)$ and $15\% (\pm 12)$ for the mice treated with nonimmune and anti-TNF IgG, respectively (mean \pm SD).

To evaluate more directly the collagen deposition, the total lung hydroxyproline content was determined. After single intratracheal administration of bleomycin, the lung hydroxyproline content was increased by $\sim 50\%$ after 15 d. This increase was nearly completely prevented by injection of anti-TNF antibody (Fig. 4).

Role of T Lymphocytes in the Pneumopathy and the TNF mRNA Accumulation. Since athymic nude mice are resistant to the bleomycin-induced pneumopathy (17), T lymphocytes are suspected of being involved. It has been shown previously that treatment in vivo with anti CD4 or CD8 mAb results in significant or complete depletion of the respective T lymphocyte subset (9). The pulmonary fibrosis, measured by the lung hydroxyproline content, was to some extent attenuated by the deletion of the CD4 or the CD8 T lymphocyte subset and completely prevented by treatment

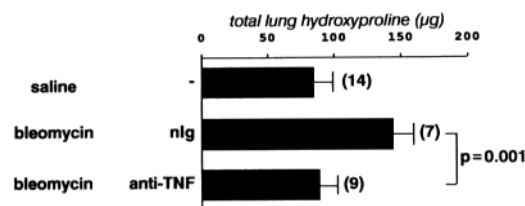


FIGURE 4. Total lung hydroxyproline of CBA mice killed 15 d after an intratracheal instillation of 0.1 U of bleomycin. In parentheses are the number of animals studied. Mice were injected with nonimmune or anti-TNF rabbit IgG (see Materials and Methods).

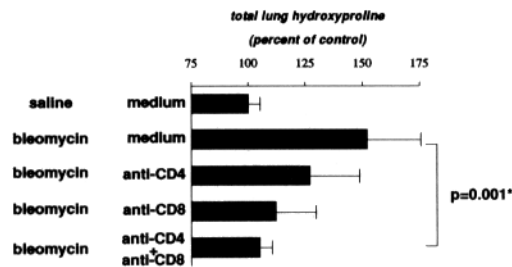


FIGURE 5. Total lung hydroxyproline of mice instilled with bleomycin and treated with anti-T lymphocyte subset mAb. Mean (\pm SD) of the values observed with more than six mice per group.

with both mAbs (Fig. 5). Furthermore, the bleomycin-induced increase of TNF mRNA level was prevented by the combined treatment with the anti-CD4 and CD8 mAbs, when examined on day 5 (Fig. 1) or 15 (not shown).

Effect of Anti-TNF Antibody on Pulmonary Lesions Produced by Intraperitoneal Administration of Bleomycin. Administration of bleomycin by intraperitoneal injection does not lead to a rapid fibrosis (18); 15 d after a continuous injection of a total dose of 2 U of bleomycin, the increase of the lung collagen content, measured by the total hydroxyproline content, was \sim 5% above the controls receiving the solvent only (not shown). However, an alveolar damage was evident that, in contrast to that induced by intratracheal instillation, was diffuse and therefore easier to quantify. Alveolar oedema and thickening of the alveolar septa were evident by light microscopy (Fig. 6 B), while epithelial and endothelial cells damage were evident when examined on the electron micrographs (Fig. 6 D). These alterations were attenuated or absent in mice passively immunized with anti-TNF IgG (Fig. 6, A-D).

Discussion

The administration of bleomycin in rodents is a model for alveolar damage and pulmonary fibrosis (2). The reason for the predominant pulmonary damage after bleomycin injection is probably related to the fate of the drug, which is found localized within the alveolar epithelium 3–4 d after an intravenous injection (19). 5 d after intratracheal injection, an increase of the TNF mRNA level is evident (Fig. 1). This increase is relatively moderate in comparison with that induced by a lethal dose of LPS (Fig. 1), but much more sustained since it is detectable during 2 wk after a single bleomycin injection, compared with only 2–3 h after LPS. This observation raises the question of whether a local increase of the TNF production plays some role in the antineoplastic effects of bleomycin.

The bleomycin-induced pneumopathy is not a direct result of a toxicity of the drug since it involves a T cell-mediated immune response. This is indicated by an influx of T lymphocytes within the lung 3–4 d after bleomycin instillation (20) and by the resistance of the athymic nude mice to bleomycin (17). In agreement with those observations, the present experiments provide two additional informations. First, either the CD4⁺ or CD8⁺ T lymphocyte subset alone is capable of inducing some degree of fibrotic response (Fig. 5), and second, the presence of the T lymphocytes is required for an increase of pulmonary TNF mRNA level (Fig. 1).

The cellular origin of the pulmonary TNF has not yet been established and may involve more than one cell variety. Macrophages are in quantitative terms the most

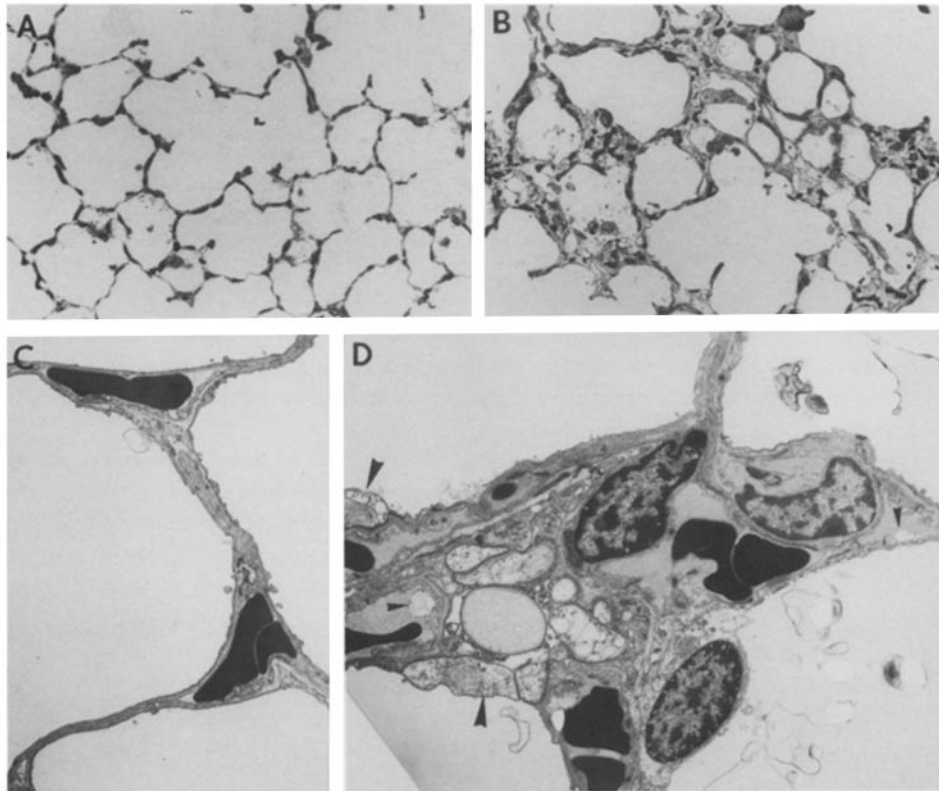


FIGURE 6. Alveolitis produced by an intraperitoneal administration of bleomycin. Mice were treated with nonimmune (*B* and *D*) or anti-TNF (*A* and *C*) rabbit IgG. (*A*) The alveola have a normal appearance, while in *B*, oedema and thickening of the alveolar septa are evident (toluidine blue, $\times 125$). Endothelial (*small arrow*) and epithelial (*wide arrow*) cell damage are evident on EM in *D*, while the alveolar septa are unaltered in *C* ($\times 2,800$). Two blocks from three mice in each group were examined with similar observations.

important producers of TNF (6, 7), and the involvement of the alveolar and interstitial population is likely. T lymphocytes can also release TNF (21), but the absence of detectable GM-CSF mRNA (Fig. 2), a cytokine usually produced by activated T lymphocytes, suggests that their number within the lung and their direct contribution to the TNF production is moderate. It appears more likely that T lymphocytes increase, by the secretion of other cytokines, both the number of macrophages and their activation to secrete TNF, as appears to be the case in other types of T cell-induced and TNF-mediated immunopathological reactions (22).

The various components of bleomycin-induced pneumopathy (i.e., alveolar damage, growth of interstitial fibroblasts, deposition of collagen [18, 19, 23]) were influenced by the administration of anti-TNF antibody. This observation has to be related to the effects of TNF upon the alveolar walls and the fibrotic process. When delivered intravenously, TNF induces a diffuse alveolar damage, notably with necrosis of alveolar epithelial and endothelial cells (24, 25). TNF also exerts a growth-promoting activity upon fibroblasts, since a subcutaneous continuous infusion leads to a marked

increase of fibroblast proliferation and collagen deposition (Piguet, P. F., G. E. Grau, and P. Vassalli, manuscript submitted for publication). Thus, the susceptibility of the lesions to the anti-TNF antibody, as well as the capacity of TNF to induce alveolar damage and fibrosis, strongly suggests that TNF is indeed the effector of both alveolar damage and fibrosis. A variety of other cytokines have been shown to influence fibroblasts in vitro, such as platelet-derived growth factor (26), IL-1 (27), and TGF- β (28). A further element of complexity results from the possibility that these mediators may induce each other, as it has been demonstrated for the induction of platelet-derived growth factor and IL-1 by TNF (29). In this context, the striking influence of anti-TNF antibody upon the collagen deposition might indicate that other mediators are not produced in significant quantities, an interpretation that, in the case of IL-1, is supported by the absence of detectable IL-1 mRNA (Fig. 2). Alternatively, or in addition, their involvement might be dependent upon TNF.

In conclusion, the following evidences are in favor of a key role of TNF in the various components of the bleomycin-induced pneumopathy: first, TNF can induce alveolar damage, fibroblast growth, and collagen deposition; second, a single injection of bleomycin induces a sustained increase of the TNF mRNA level within the lung; and third, anti-TNF antibody prevents the bleomycin-induced alveolar damage, growth of fibroblasts, and collagen deposition. Recent experiments in our laboratory indicate that this conclusion is also valid for pulmonary fibrosis induced by silica particles.

Summary

The role of TNF- α /cachectin in the pneumopathy elicited by bleomycin has been investigated. After a single intratracheal bleomycin instillation, an increase of the lung TNF- α mRNA level was evident, from days 5 to 15, as shown by Northern gel analysis of whole lung RNA. In contrast, lung IL-1- α and GM-CSF mRNA were not detectable. In mice passively immunized with rabbit anti-mouse TNF- α IgG, the bleomycin-induced collagen deposition, evaluated by the total lung hydroxyproline assay on day 15, was prevented. Depletion of the CD4 and CD8 T lymphocytes by an in vivo treatment with mAb prevented the bleomycin-induced increase of TNF mRNA level and fibrosis. After an administration of bleomycin in continuous intraperitoneal perfusion, the diffuse alveolar damage observed by light and electron microscopy was almost completely prevented by anti-TNF antibody. These results indicate that in response to bleomycin, the T lymphocytes induce, by an undefined mechanism, an increase of the pulmonary TNF production, which leads to alveolar damage, growth of fibroblast, and collagen deposition.

We are grateful to D. Belin, J. J. Mermoud, and S. de Kossodo for the preparation of the probes for TNF, GM-CSF, and IL-1. The technical collaboration of A. F. Rochat, M. C. Pecclet, C. Briottet, G. Leyvraz, Joan Stalder, and C. Vesin is gratefully acknowledged.

Received for publication 21 March 1989 and in revised form 15 May 1989.

References

1. Colby, T. V., and A. C. Churg. 1986. Patterns of pulmonary fibrosis. *Pathol. Annu.* 21:277.
2. Bowden, D. H. 1984. Unraveling pulmonary fibrosis: the bleomycin model. *Lab. Invest.* 50:487.

3. Reiser, K. M., and J. A. Last. 1986. Early cellular events in pulmonary fibrosis. *Exp. Lung Res.* 10:331.
4. Kovacs, E. J., and J. Kelly. 1985. Secretion of macrophage-derived growth factor during acute lung injury induced by bleomycin. *J. Leukocyte Biol.* 37:1.
5. Suwabe, A., K. Takahashi, S. Yasui, S. Arai, and F. Sendo. 1988. Bleomycin-stimulated hamster alveolar macrophages release interleukin-1. *Am. J. Pathol.* 132:512.
6. Beutler, B., and A. Cerami. 1988. Tumor necrosis, cachexia, shock and inflammation: a common mediator. *Annu. Rev. Biochem.* 57:505.
7. Le, J., and J. Vilcek. 1987. Biology of disease. Tumor necrosis factor and interleukin 1: cytokines with multiple overlapping activities. *Lab. Invest.* 56:234.
8. Sugarman, B. J., B. B. Aggarwal, I. S. Figari, and M. A. Palladino. 1985. Recombinant human tumor necrosis factor α : effects on proliferation of normal and transformed cells in vitro. *Science (Wash. DC)*. 230:943.
9. Pigué, P. F. 1988. Helper T lymphocytes which recognize the MHC class I alloantigens in vivo are CD4⁺ CD8⁻. *J. Immunol.* 141:4129.
10. Ruff, M. F., and G. E. Gifford. 1980. Purification and physico-chemical characterization of tumor necrosis factor. *J. Immunol.* 126:1671.
11. Glisin, V., R. Crkverijakov, and C. Byus. 1974. Ribonucleic acid isolated by cesium chloride centrifugation. *Biochemistry.* 13:2633.
12. Collart, M. A., D. Belin, J. D. Vassalli, S. de Kossodo, and P. Vassalli. 1986. Interferon enhances macrophage transcription of the tumor necrosis factor/cachectin, interleukin 1, and urokinase genes, which are controlled by short-lived repressors. *J. Exp. Med.* 164:2113.
13. Thorens, B., J. J. Mermoud, and P. Vassalli. 1987. Phagocytosis and inflammatory stimuli induce GM-CSF mRNA in macrophages through posttranscriptional regulation. *Cell.* 48:671.
14. Grau, G. E., L. Fajardo, P. F. Pigué, B. Allet, P. H. Lambert, and P. Vassalli. 1987. Tumor necrosis factor (cachectin) as an essential mediator in murine cerebral malaria. *Sciences (Wash., DC)*. 237:1210.
15. Huszar, G., J. Maiocco, and F. Naftolin. 1979. Monitoring of collagen and collagen fragments in chromatography of protein mixtures. *Anal. Biochem.* 105:424.
16. Kindler, V., A. P. Sappino, G. E. Grau, P. F. Pigué, and P. Vassalli. 1989. The inducing role of tumor necrosis factor in the development of bacterial granulomas during BCG infection: a focal autoamplifying process of tissue organisation. *Cell.* 56:731.
17. Schrier, D. J., S. H. Phan, and B. M. McGarry. 1983. The effects of the nude (nu/nu) mutation on bleomycin-induced pulmonary fibrosis. *Am. Rev. Respir. Dis.* 127:614.
18. Collins, J. F., B. McCullough, J. J. Coalson, and W. G. Johanson. 1981. Bleomycin-induced diffuse interstitial pulmonary fibrosis in baboons. *Am. Rev. Respir. Dis.* 123:305.
19. Adamson, I. R., and B. H. Bowden. 1979. Bleomycin-induced injury and metaplasia of alveolar type 2 cells. Relationship of cellular responses to drug presence in the lung. *Am. J. Pathol.* 96:531.
20. Thrall, R. S., and R. W. Barton. 1984. A comparison of lymphocyte populations in lung tissue and in bronchoalveolar lavage fluid of rats at various times during the development of bleomycin-induced pulmonary fibrosis. *Am. Rev. Respir. Dis.* 129:279.
21. Cuturi, M.C., M. Murphy, M. P. Costa-Giomi, R. Weinman, B. Perussia, and G. Trinchieri. 1987. Independent regulation of tumor necrosis factor and lymphotoxin production by human peripheral blood lymphocytes. *J. Exp. Med.* 165:1581.
22. Grau, G. E., V. Kindler, P. F. Pigué, P. H. Lambert, and P. Vassalli. 1988. Prevention of experimental cerebral malaria by anticytokine antibodies. Interleukin 3 granulocyte macrophage colony-stimulating factors are intermediates in increased tumor necrosis factor production and macrophage accumulation. *J. Exp. Med.* 168:1499.

23. Jones, A. W., and L. Reeve. 1977. Ultrastructural study of bleomycin-induced pulmonary changes in mice. *Am. J. Pathol.* 124:227.
24. Tracy, K. J., H. Wei, K. R. Manogue, Y. Fong, D. G. Hesse, H. T. Nguyen, G. C. Kuo, B. Beutler, R. S. Cotran, A. Cerami, and S. F. Lowry. 1988. Cachectin/tumor necrosis factor induces cachexia, anemia, and inflammation. *J. Exp. Med.* 167:1211.
25. Piguet, P. F., G. E. Grau, B. Allet, Y. Kapanci, and P. Vassalli. 1986. Diffuse alveolar damage elicited by perfusion with tumor necrosis factor (TNF). *Int. Arch. Allerg. Appl. Immunol.* 83:18. (Abstr.)
26. Ross, R., E. W. Raines, and D. F. Bowen-Pope. 1986. The Biology of Platelet-derived growth factor. *Cell.* 46:155.
27. Schmidt, J. A., S. B. Mizel, D. Cohen, and I. Green. 1982. Interleukin-1, a potential regulator of fibroblast proliferation. *J. Immunol.* 128:2177.
28. Roberts, A. B., M. B. Sporn, R. K. Assoian, J. M. Smith, N. S. Roche, L. M. Wakefield, U. I. Heine, L. A. Liotta, V. Falanga, J. H. Kehrl, and A. S. Fauci. 1986. Transforming growth factor type-beta: rapid induction of fibrosis and angiogenesis in vivo and stimulation of collagen formation in vitro. *Proc. Natl. Acad. Sci. USA.* 83:4167.
29. Hajjar, K. A., D. P. Hajjar, R. L. Silverstein, and R. L. Nachman. 1987. Tumor necrosis factor-mediated release of platelet-derived growth factor from cultured endothelial cells. *J. Exp. Med.* 166:235.