

THE LOCALIZATION OF AUSTRALIA ANTIGEN BY IMMUNOFLUORESCENCE*

BY VERONICA E. COYNE(ZAVATONE), M.D., IRVING MILLMAN, PH.D.,
JAMES CERDA, M.D., B. J. S. GERSTLEY, M.D., THOMAS LONDON, M.D.,
ALTON SUTNICK, M.D., AND BARUCH S. BLUMBERG, M.D.

*(From The Institute for Cancer Research, Fox Chase,
Philadelphia, Pennsylvania 19111)*

(Received for publication 8 September 1969)

Since the discovery of Australia antigen, Au(1), by Blumberg et al. in 1965 (1) the association of this antigen with viral hepatitis has been well established (2-4). Au(1) is present in 58% of patients with posttransfusion hepatitis and in 38% of patients with infectious hepatitis (5). When patients are tested serially after blood transfusion, the incidence of Au(1) was found to be 74% (6). In most acute cases, the antigen appears in the blood early in the disease and disappears within 2-3 wk as clinical improvement occurs.

In addition to the epidemiologic association, there are several findings which provide strong support for the hypothesis that Au(1) is an antigenic determinant of a virus capable of causing hepatitis. (a) Purified Au(1), isolated from serum of patients with hepatitis, consists of virus-like particles, 200 A in diameter, which are agglutinated by specific anti-Au(1) antiserum (7). (b) Patients who have received blood containing Au(1) have developed hepatitis with Au(1) in their blood or remained healthy and developed antibody to Au(1) (4). (c) With the use of a specific fluorescein-conjugated antibody to Au(1) we were able to demonstrate fluorescent granules in or on the surface of nuclei of cells from liver tissue in four patients with hepatitis and Au(1) in their serum. Five control patients who had neither hepatitis nor serum Au(1) did not have fluorescent granules (8).

The purpose of the present study is to determine whether the fluorescent particles in liver tissue are associated with Au(1) in the blood and whether the particles are present in tissues other than liver. This study involves 61 liver biopsy specimens, 25 specimens of other human tissues, cells from 8 samples of bile or duodenal drainage and peripheral lymphocyte cultures from 8 patients. This study confirms our previous results and establishes: (a) that the fluorescent particles in the cells are related to Au(1) in the serum and to the diagnosis of hepatitis. (b) The fluorescent particles are present in tissues other than liver in some patients.

* This work was supported in part by United States Public Health Service Grants CA-08069, CA-06927, FR-05539, FR-0040, and 5 MO1 RR40 from the National Institutes of Health, the Brian William Donovan Memorial Fund, and by an appropriation from the Commonwealth of Pennsylvania. V.C. was in receipt of a Damon Runyon Cancer Research Fellowship.

Materials and Methods

Collection of Specimens.—61 liver biopsy specimens were obtained from 58 patients in hospitals in the Philadelphia area and one from elsewhere.¹ In 57 cases needle biopsies were performed using a Menghini needle. Two liver specimens were obtained at surgery and two at autopsy. Two patients had a second biopsy performed 4–6 wk after the initial biopsy. The second specimen in each case was treated and recorded as a separate specimen for statistical analysis. Eight bone marrow specimens were obtained by needle aspiration of the sternum. The other tissues were obtained from organs removed at surgery for therapeutic reasons. Buffy coat smears and peripheral lymphocytes were obtained from patients in our Clinical Research Unit. Seminal fluid was obtained from one patient with acute hepatitis who also had Au(1) in his serum. A blood sample was obtained from each patient at the time of liver biopsy or collection of other specimens.

One patient in our Clinical Research Unit was studied in detail and will be reported elsewhere (9). He was a 21 year old male (D.M.) with Down's syndrome and chronic hepatitis and Au(1) in his blood who later developed acute myelogenous leukemia. A bone marrow specimen was obtained 3 wk prior to death, and immediately after death specimens of liver, spleen, mesentery, and testis were taken.

Preparation of Tissues for Examination.—Each tissue specimen was placed in a small volume of McCoy's 5a tissue culture medium (Grand Island Biological Co., Grand Island, N.Y.) containing 30% newborn calf serum (Hyland Laboratories, Los Angeles, Calif.) and was minced to produce a cell suspension.² A drop of the cell suspension was placed on a clean slide, air-dried and fixed in acetone at room temperature for 10 min.³ At the same time, a piece of tissue was placed in formalin and processed for routine histologic examination by the clinical pathology departments of the respective hospitals. The bone marrow specimens were prepared by placing a drop of the marrow directly on a glass slide, air-drying and fixing as above. Cells were obtained from bile, duodenal drainage, and seminal fluid by centrifugation for 10 min in a clinical centrifuge, washing the cell pellet in Earle's balanced salt solution (Grand Island Biological Co.), resuspending in McCoy's medium, and preparing slides as above. Buffy coat smears were made from peripheral blood and fixed in acetone for 10 min. Peripheral lymphocyte cultures were prepared by the method of Hungerford (10) with the omission of colchicine.

Preparation of Reagent and Staining of Slides.—Fluorescein-conjugated rabbit anti-Au(1) antiserum was prepared and direct fluorescent staining of slides was performed by the methods previously published (8). Replicate slides were stained with fluorescein-conjugated goat vs. human antiserum and goat-vs.-rabbit antiserum to test the specificity of the reaction. Indirect staining was performed by flooding the slides with unconjugated rabbit anti-Au(1) antiserum, washing in buffered saline, and then applying fluorescein-labeled goat-vs.-rabbit anti-globulin antiserum. Control slides for the indirect test were treated first with normal rabbit serum in place of the anti-Au(1) antiserum before the application of conjugated goat-vs.-rabbit anti-globulin antiserum.

¹ These include: The American Oncologic Hospital, Children's Hospital of Philadelphia, the Hospital of the University of Pennsylvania, Jeanes Hospital, Jefferson Medical College Hospital, Philadelphia General Hospital, Pennsylvania Hospital, Temple University Hospital, the Philadelphia Veterans Administration Hospital, and Woman's Medical College Hospital. One case was obtained from the Strong Memorial Hospital, Rochester, New York.

² McCoy's medium alone or buffered saline, pH 7.4, were used in some cases and produced similar results.

³ We have tried direct tissue impressions on many liver specimens in the past and found that they were unsatisfactory.

Testing of Serum.—Serum from each patient was tested for the presence of Au(1) by double diffusion in agar gel (Ouchterlony method), using a panel of anti-Au(1) antisera consisting of rabbit, mouse, and human antisera (11).

Examination of Slides.—Slides were examined for fluorescence in dark field using a Zeiss microscope with the HBO 200 watt illuminator, BG 12 exciter filter, and 53 barrier filter. All slides were read by one of us (V.C.) without knowledge of the histologic diagnosis or the serum results for Au(1). The reproducibility of results was established by examining duplicate slides from the same patients and by reading the same slides on different days. To test the accuracy of reading, 10 slides were chosen at random and coded. They were read by V.C. and I.M. independently. The correlation between the two observers was 100%.

RESULTS

I. Liver Biopsies

Appearance of Fluorescence.—When tested by the direct method, the liver biopsies could be divided into two groups on the basis of fluorescence. In the first group, which we called negative, the cytoplasm of the cells usually appeared dull orange-brown almost identical to the autofluorescence seen in unstained preparations. The nuclei of cells in this group always appeared completely dark (Fig. 1). In the second group, which we called positive, we could detect apple-green fluorescence in, or on the surface of, the nucleus and occasionally in the cytoplasm. The nuclear fluorescence appeared in three different forms: (a) discrete granules varying in size and number, but usually averaging one to three per cell (Fig. 2); (b) diffuse finely granular fluorescence of the entire nucleus (Fig. 3a); (c) fluorescence of the nuclear rim (Fig. 3b). The first type was the most common, but all three types could be seen in the same specimen in some cases. In the positive cases, most of the cells on the slide showed some form of fluorescence. In some cases discrete fluorescent granules were seen in the cytoplasm as well as in the nucleus. Control slides stained with fluorescein-conjugated goat-vs.-human or goat-vs.-rabbit antisera, not expected to react with Au(1), showed neither intranuclear nor discrete cytoplasmic fluorescence. Occasionally we observed a pale green diffuse cytoplasmic fluorescence in both positive and negative slides as well as in some control slides. This was considered nonspecific.

The indirect method of staining demonstrated fluorescent granules only in those preparations that were positive by the direct stain. However, the granules were located to a large extent in the cytoplasm and intranuclear particles were few. In some cases the nucleus was disrupted and fluorescent granules were dispersed in the cytoplasm (Fig. 4a, b). We interpreted this to indicate that the particles had been dislodged from the nucleus by the prolonged washing procedure. Therefore, we confined our observations to the direct method.

Classification of Patients.—Table I lists the patients on whom liver biopsies were performed according to their clinical diagnosis, the histologic diagnosis made on the liver specimen, the presence of Au(1) in the serum, and the

presence of fluorescence. 33 patients had a clinical and histologic diagnosis of viral hepatitis including acute infectious, posttransfusion, chronic recurrent, and

TABLE I
Classification of Patients Whose Liver Biopsies Were Studied

Clinical diagnosis	Histologic diagnosis	Number of patients	Number with Au(1)	Number with positive fluorescence
Infectious hepatitis	Viral hepatitis	9	5	8
Posttransfusion hepatitis	Viral hepatitis	3	3	3
Hepatitis in drug users (exposure to needles)	Viral hepatitis	6	4	4
Chronic alcoholism and drug use	Laënnec's cirrhosis + acute and chronic inflammation	2	0	2
Chronic recurrent hepatitis	Chronic active hepatitis	2	1	2
Chronic anicteric hepatitis and Down's syndrome	Mild inflammatory changes to early postnecrotic cirrhosis	12	10	12
Chronic anicteric hepatitis, Down's syndrome, and leukemia	Chronic hepatitis	1	1	1
Postnecrotic cirrhosis	Postnecrotic cirrhosis	1	0	1
Mental retardation (institutionalized)	Normal liver	3	1	3
Biliary cirrhosis	Biliary cirrhosis	1	0	1
Biliary atresia	Biliary atresia	1	0	1
Chronic renal disease, (received many blood transfusions)	Hemosiderosis and chronic inflammation	1	1	1
Chronic renal disease	Normal liver	1	0	0
Drug toxicity	Toxic hepatitis	3	0	0
Hepatoma	Hepatoma	1	0	0
Metastatic malignancy	Carcinoma of colon metastasized to liver	1	0	0
Hepatomegaly and jaundice	Adenocarcinoma, ? of bile duct origin	1	0	1
Renal malignancy	Carcinoma of kidney metastasized to liver	1	0	1
Fever of unknown origin	Nonspecific necrosis	2	0	0
Acute alcoholic	Acute alcoholic hepatitis	4	0	0
Chronic alcoholism	Laënnec's cirrhosis	4	0	0
Sickle cell disease	Hemosiderosis and intravascular sickling	1	0	0
Totals		61	26	41

chronic anicteric hepatitis. Two patients were chronic alcoholics and drug users who had been exposed to needles. One patient had postnecrotic cirrhosis which was presumed to have resulted from previous viral hepatitis. One pa-

tient with chronic renal disease had received many blood transfusions. The 24 remaining patients had a variety of other diagnoses.

Relationship between Fluorescence and Serum Au(1).—Table II A gives the comparison between the occurrence of fluorescence in the liver cells and the presence of Au(1) in the serum. There were 26 patients who had Au(1) in their blood. 24 had a diagnosis of viral hepatitis, one was a patient with chronic renal disease who had received many blood transfusions, and the other was an institutionalized mentally retarded patient with both Au(1) and antibody to Au(1) in his serum, but a histologically normal liver. All 26 patients with

TABLE II
Comparison of Immunofluorescence with Presence of Au(1) and Pathologic Diagnosis

Fluorescence	A. Fluorescence vs. serum Au(1)		Total
	Number of patients with serum Au(1)		
	+	0	
+	26	15	41
0	0	20	20
Totals	26	35	61
Chi square = 19.58; <i>P</i> value <0.001			
Fluorescence	B. Fluorescence vs. hepatitis (histologic diagnosis)		Total
	Number of patients with hepatitis		
	+	0	
+	30	11	41
0	3	17	20
Totals	33	28	61

Chi square = 16.05; *P* value <0.001

Au(1) in their blood had specific fluorescence in the nuclei of cells obtained from the liver biopsy. In addition, 15 of the 35 patients who did not have Au(1) in their blood had fluorescent granules in their liver cells. Six of these patients had a histologic diagnosis of viral hepatitis. Two were alcoholics and drug users; one was a patient with postnecrotic cirrhosis; two were residents of an institution for the mentally retarded and had been exposed repeatedly to patients with known hepatitis and Au(1). Two were patients with malignancies involving the liver and had undergone surgery. One patient had biliary atresia and the other primary biliary cirrhosis.

Relationship between Fluorescence and Hepatitis.—Table II B gives the comparison between the occurrence of fluorescence and the histologic diagnosis of viral hepatitis. 30 out of 33 patients with evidence of viral hepatitis (91%)

showed nuclear fluorescence. The three patients with hepatitis who did not have fluorescence were in the recovery phase of their illness and did not have Au(1) in their serum.

Results of Repeat Biopsies.—Both patients on whom a repeat biopsy was performed had Au(1) in their serum and acute hepatitis at the time of the first biopsy. In both cases fluorescent granules were present in the first specimen. In one patient fluorescence was not seen on the second specimen, taken 4 wk after the first biopsy, coincident with clinical improvement and disappearance

TABLE III
Tissues and Fluids Tested for Fluorescence

Type of specimen	Number of patients	Number with Au(1) in serum	Number with positive fluorescence
Kidney	2	1	0
Jejunal loop	4	4	0
Lymph node	2	2	0
Spleen	2	1	1
Bone marrow	8	6	2
Testis	1	1	1
Mesentery	1	1	1
Adrenal	1	0	0
Ovary	1	0	0
Gall bladder	1	0	0
Lung	1	0	0
Cancer of lung	1	0	0
Bile and duodenal drainage	8	4	0
Seminal fluid	1	1	0
Total	34	21	5

of Au(1) from the serum. The other patient had a more prolonged illness with persistence of Au(1) in his blood for at least 3 months. Fluorescent granules were still present in his second biopsy specimen, obtained 6 wk after the initial biopsy.

II. *Tissues Other Than Liver*

Table III lists the tissues and cells studied for fluorescence. All the tissues studied from D.M. (the patient with Down's syndrome and acute myelogenous leukemia), taken immediately after death, showed fluorescence. The fluorescence in the liver, testis, and mesenteric connective tissue is similar to that found in the liver preparation from patients with hepatitis in that the three patterns of fluorescence were found in all these tissues (Fig. 5a, b, c). In the spleen, however, only a small percentage of the cells showed fluorescence which

was mostly in the cytoplasm. The bone marrow specimen, obtained 3 wk prior to death and consisting almost entirely of myeloblasts, did not have fluorescence (Fig. 5d).

Two of eight bone marrow specimens from patients with acute or chronic hepatitis showed fluorescence confined to the cytoplasm of the cells. These were from a patient with acute infectious hepatitis with Au(1) in the blood, and from a mentally retarded institutionalized patient who had both Au(1) and antibody to Au(1). In both of these cases only a small percentage of the cells on the slide were involved.

None of the other tissues studied including buffy coat smears, cells obtained from bile, duodenal drainage, and seminal fluid showed fluorescence. Peripheral lymphocyte cultures in six patients with chronic hepatitis and Au(1) in their serum also were negative.

DISCUSSION

By means of the fluorescent antibody technique, using a specific anti-Au(1) antiserum, we have demonstrated fluorescent particles mainly in the nuclei and occasionally in the cytoplasm of cells from liver biopsies. Fluorescent particles were present in 100% of patients who had Au(1) in their serum. Fluorescent granules occurred in 15 patients who did not have Au(1) in their blood. Six of these had definite clinical and histologic evidence of acute or chronic hepatitis, and 5 others probably had been exposed to viral hepatitis (Table I). We interpret these results to indicate that the fluorescence test is more sensitive in detecting Au(1) than is the precipitin test. An alternative explanation is that in some patients there is little or no cellular necrosis and consequently little or no antigen is released into the peripheral blood; however, it can be detected in the cells.

The finding of fluorescent granules in one patient with biliary atresia and another patient with biliary cirrhosis (Table I) raises the question of possible involvement by viral hepatitis in the pathogenesis of these diseases of the biliary system. Biliary atresia as an end result of neonatal hepatitis has been discussed by Alpert et al. in their study of patients with trisomy 17-18 (12).

The presence of three forms of fluorescence indicates that Au(1) is not restricted to one location within the nucleus. In most cases the fluorescence appeared as one to three small masses within the nucleus corresponding morphologically to the site of the nucleoli. The finding of fluorescence in the region of or in the nucleolus is interesting in view of the studies of Bearcroft and Peachey (13, 14). Using cytological and cytochemical methods and electron microscopy they found that there was swelling of the nucleolus and an increase in nucleolar ribonucleoprotein early in viral hepatitis. They postulated that these changes may be concerned with viral synthesis. The three forms of fluorescence which we observed could indicate stages of viral replication within the nucleolus,

proceeding to the dispersal of granules throughout the nucleus, attachment to the nuclear membrane, and eventual appearance in the cytoplasm.

The appearance of fluorescence in a few cells in two bone marrow specimens could be explained on the basis of phagocytosis of circulating antigen. The widespread presence of fluorescent particles in the tissues of D.M. may represent either massive invasion by virus in a patient who was critically ill and debilitated or a viral proliferation which was directly related to the leukemic process.

We believe that the fluorescent antibody used in this study specifically identifies Au(1) for the following reasons. (a) The immunologic specificity of the antisera was confirmed by immunodiffusion and immunoelectrophoretic analysis (8). (b) Fluorescein conjugates of antisera which did not contain antibody to Au(1) failed to produce fluorescence in the positive liver preparations. (c) The association between fluorescent particles in the liver and the presence of Au(1) in the serum is highly significant ($P < 0.001$). (d) Most of the liver specimens negative for fluorescence were from abnormal livers, suggesting that the fluorescent antibody does not detect simply a nonspecific product of cell injury.

SUMMARY

We have studied the localization of Australia antigen, a particulate substance associated with hepatitis, by means of the fluorescent antibody technique. Preparations were made from 61 liver biopsy specimens taken from patients with infectious hepatitis, serum hepatitis, and a variety of other diseases. When tested with fluorescein-conjugated rabbit anti-Au(1) antisera all 26 patients who had Au(1) in their serum had specific fluorescence in their liver cells. The fluorescence appeared in three forms: as discrete particles within the nucleus, diffuse fluorescence of the entire nucleus, and fluorescence of the nuclear rim. Occasionally there were also fluorescent particles in the cytoplasm. Other specimens were tested with the fluorescent antibody including a variety of human tissues, buffy coat smears, peripheral lymphocyte cultures, and cells obtained from bile and duodenal drainage. Among these specimens, fluorescence was found in the cytoplasm of a few cells in the bone marrow of two patients with hepatitis and Au(1) in their serum, and in the liver, spleen, mesentery, and testis of one patient with leukemia, chronic hepatitis, and Au(1) in his serum. We have shown that the presence of fluorescent particles in the liver cells is strongly associated with the presence of Au(1) in the serum and the diagnosis of viral hepatitis. We believe that this study adds support to the hypothesis that Australia antigen is an antigenic determinant of a virus capable of causing hepatitis.

BIBLIOGRAPHY

1. Blumberg, B. S., H. J. Alter, and S. Visnich. 1965. A "new" antigen in leukemia sera. *J. Amer. Med. Ass.* **191**:541.

2. Blumberg, B. S., B. J. S. Gerstley, D. A. Hungerford, W. T. London, and A. I. Sutnick. 1967. A serum antigen (Australia antigen) in Down's syndrome, leukemia and hepatitis. *Ann. Intern. Med.* **66**:924.
3. Blumberg, B. S., A. I. Sutnick, and W. T. London. 1968. Hepatitis and leukemia: their relation to Australia antigen. *Bull. N. Y. Acad. Med.* **44**:1566.
4. Okochi, K., and S. Murakami. 1968. Observations on Australia antigen in Japanese. *Vox Sang.* **15**:374.
5. Blumberg, B. S., A. I. Sutnick, W. T. London, B. J. S. Gerstley, I. Millman, V. E. Zavatone, J. R. Senior, and J. J. Cerda. 1969. Current status of the Australia antigen hepatitis studies. *Gastroenterology.* **56**:1212.
6. Hirschmann, R. J., N. R. Shulman, L. F. Barker, and K. O. Smith. 1969. Virus-like particles in sera of patients with infectious and serum hepatitis. *J. Amer. Med. Ass.* **208**:1667.
7. Bayer, M. E., B. S. Blumberg, and B. Werner. 1968. Particles associated with Australia antigen in the sera of patients with leukemia, Down's syndrome and hepatitis. *Nature (London).* **218**:1057.
8. Millman, I., V. E. Zavatone, B. J. S. Gerstley, and B. S. Blumberg. 1969. Australia antigen detected in the nuclei of liver cells of patients with viral hepatitis by the fluorescent antibody technique. *Nature (London).* **222**:181.
9. Millman, I., L. A. Loeb, M. E. Bayer, and B. S. Blumberg. 1970. Australia antigen (hepatitis associated antigen): purification and physical properties. *Fed. Proc.* In press.
10. Hungerford, D. A. 1965. Leukocytes cultured from small inocula of whole blood and the preparation of metaphase chromosomes by treatment with hypotonic KCl. *Stain Technol.* **40**:333.
11. Melartin, L., and B. S. Blumberg. 1966. Production of antibody against Australia antigen in rabbits. *Nature (London).* **210**:1340.
12. Alpert, L. I., L. Strauss, and K. Hirschhorn. 1969. Neonatal hepatitis and biliary atresia associated with trisomy 17-18 syndrome. *N. Engl. J. Med.* **280**:16.
13. Bearcroft, W. G. C., and R. D. C. Peachey. 1962. Cytological and cytochemical studies on the liver in infective hepatitis. *J. Pathol. Bacteriol.* **83**:373.
14. Bearcroft, W. G. C., and R. D. C. Peachey. 1962. Electron microscopic studies on the liver in infective hepatitis. *J. Pathol. Bacteriol.* **83**:383.

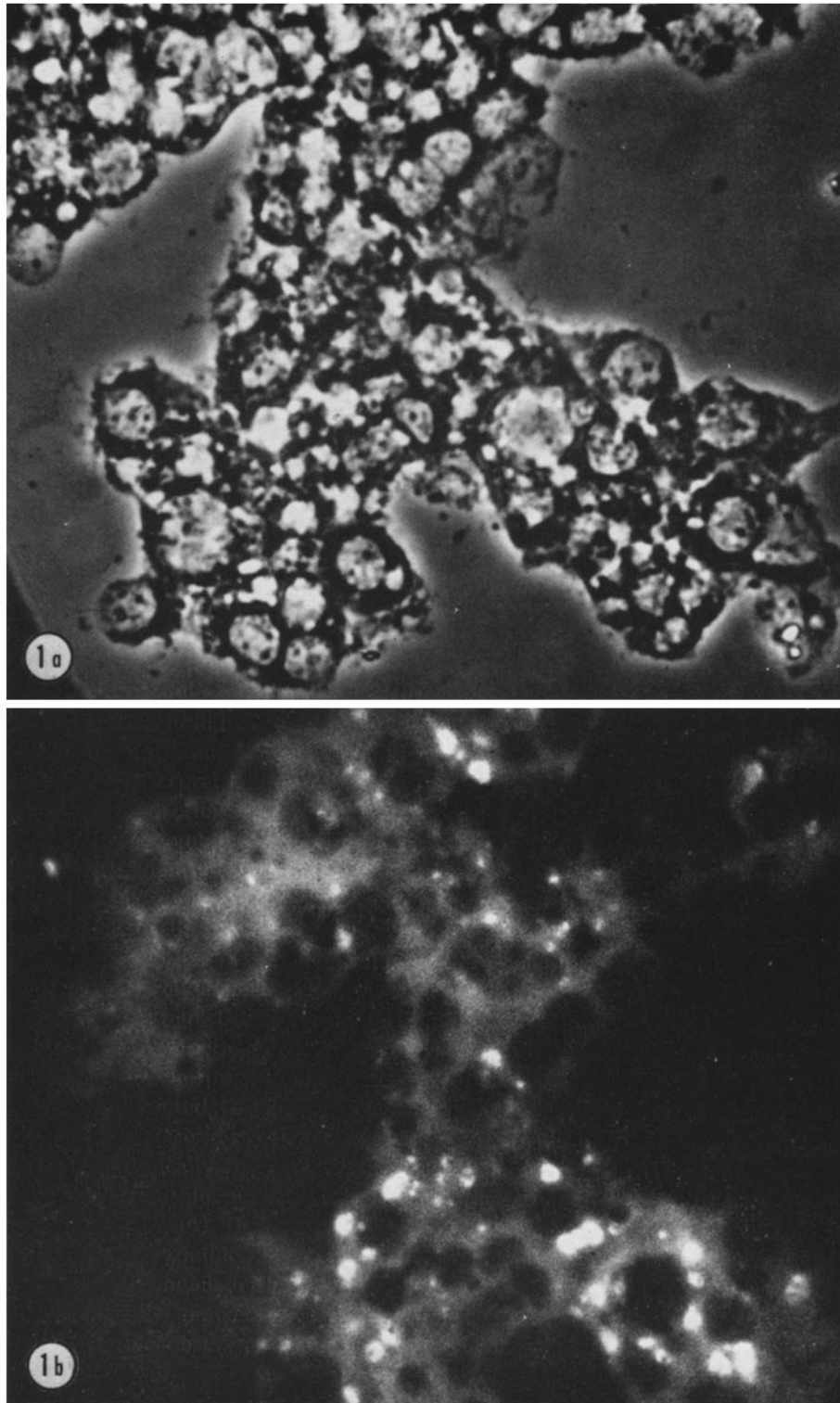


FIG. 1a and b. Cells from liver biopsy of a patient with Laënnec's cirrhosis stained with conjugated rabbit anti-Au(1) antiserum. This patient did not have Au(1) in the peripheral blood and had no clinical or histologic evidence of hepatitis. Nuclei appear dark. Cytoplasmic particles due to orange autofluorescence of lipids. This is scored as negative for fluorescence. (a) phase; (b) ultraviolet. Magnification, $\times 1700$.

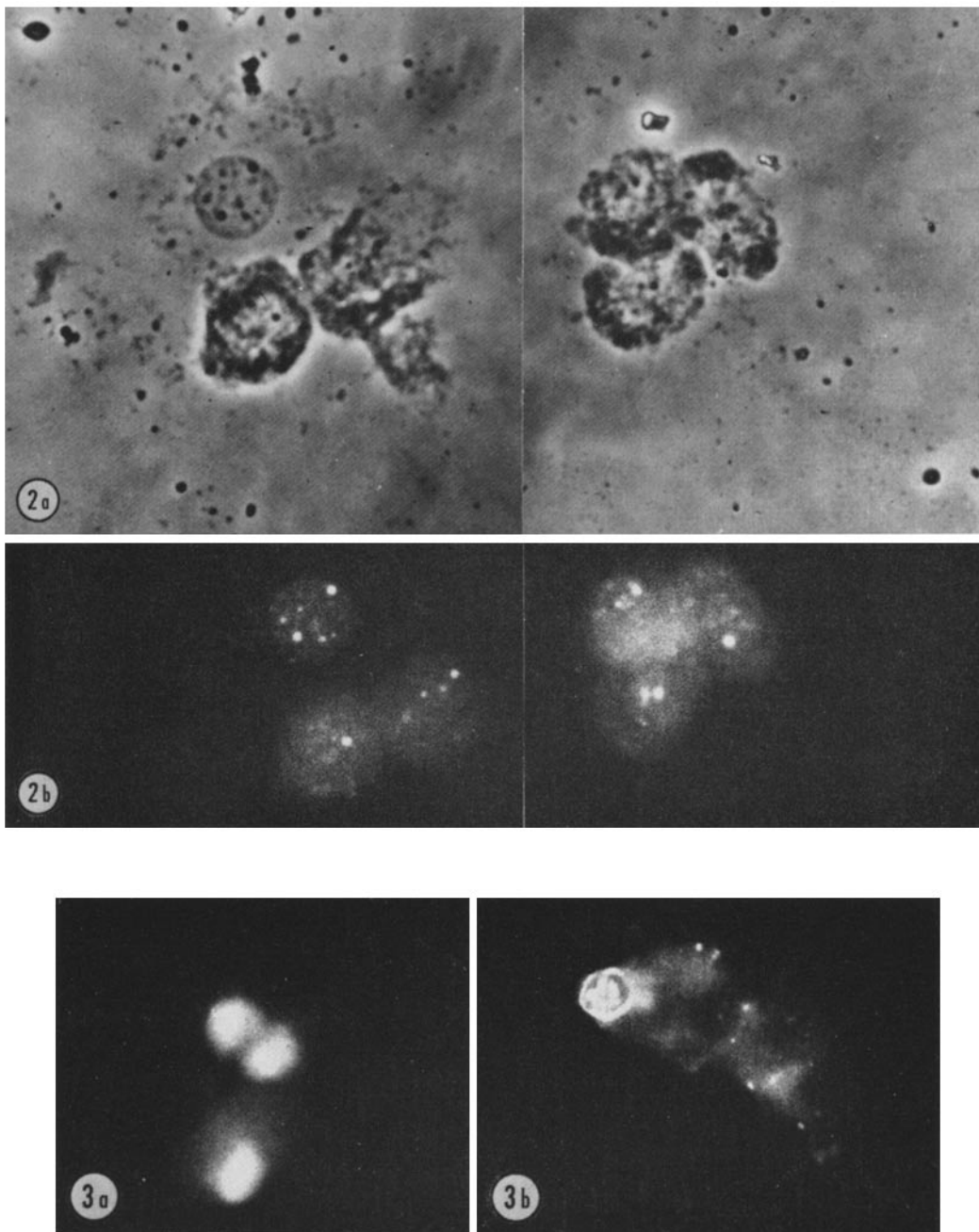


FIG. 2a and b. Cells from liver biopsy of a patient with chronic anicteric hepatitis who had Au(1) in his peripheral blood. The biopsy is stained with conjugated rabbit anti-Au(1) antiserum, and shows intranuclear fluorescent particles. This is scored as positive fluorescence. (a) phase; (b) ultraviolet. $\times 1700$.

FIG. 3. Liver preparations from two patients with viral hepatitis who had Au(1) in their peripheral blood. The biopsy is stained with conjugated rabbit anti-Au(1) antiserum. (a) Diffuse fluorescence of entire nucleus. (b) Fluorescence of nuclear rim, as well as intranuclear particles. $\times 1350$.

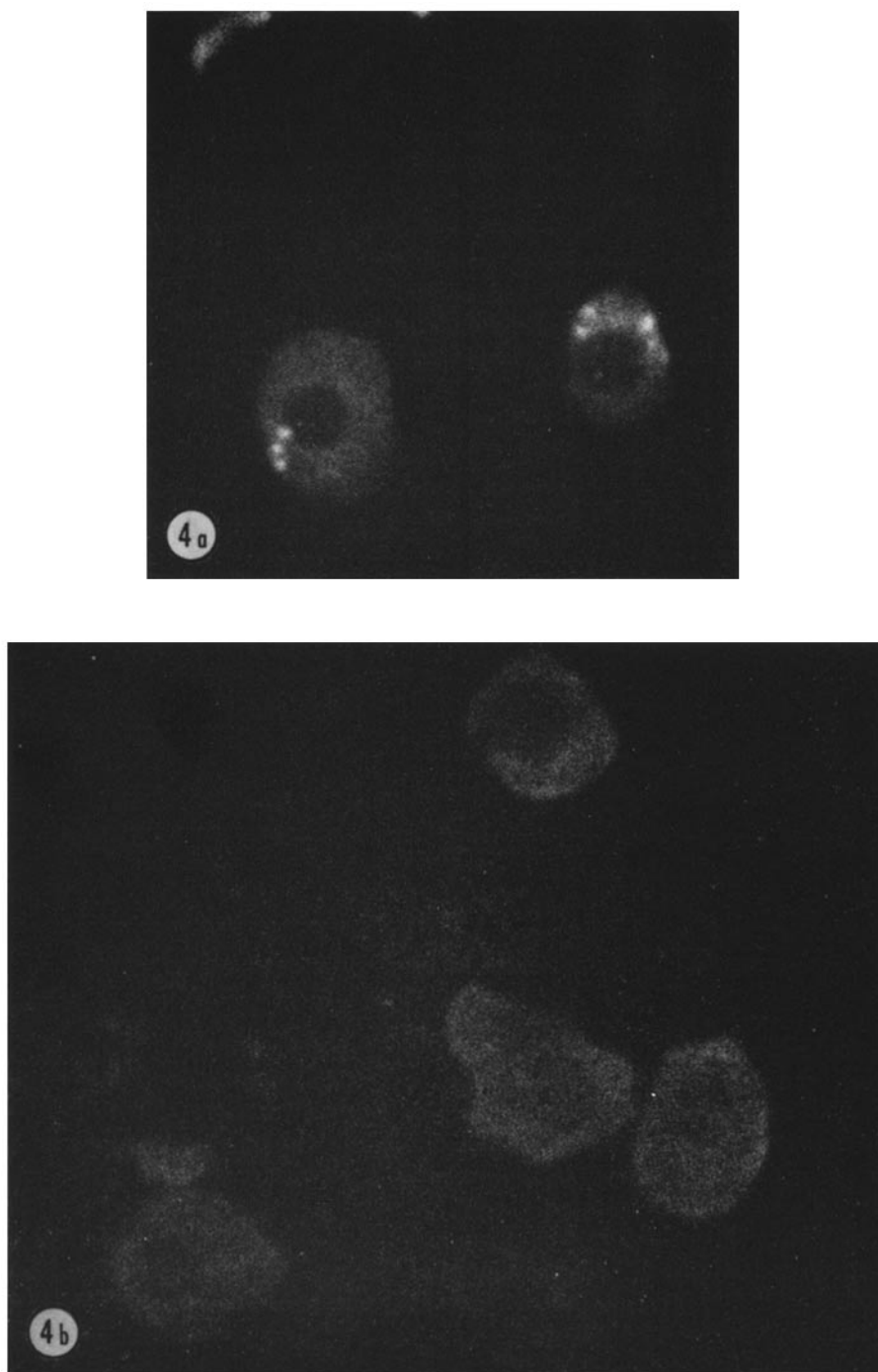


FIG. 4. Liver preparation from a patient with viral hepatitis stained by the indirect method. (a) Stained with unconjugated rabbit anti-Au(1) antiserum. (b) Stained with unconjugated normal rabbit serum. $\times 1700$.

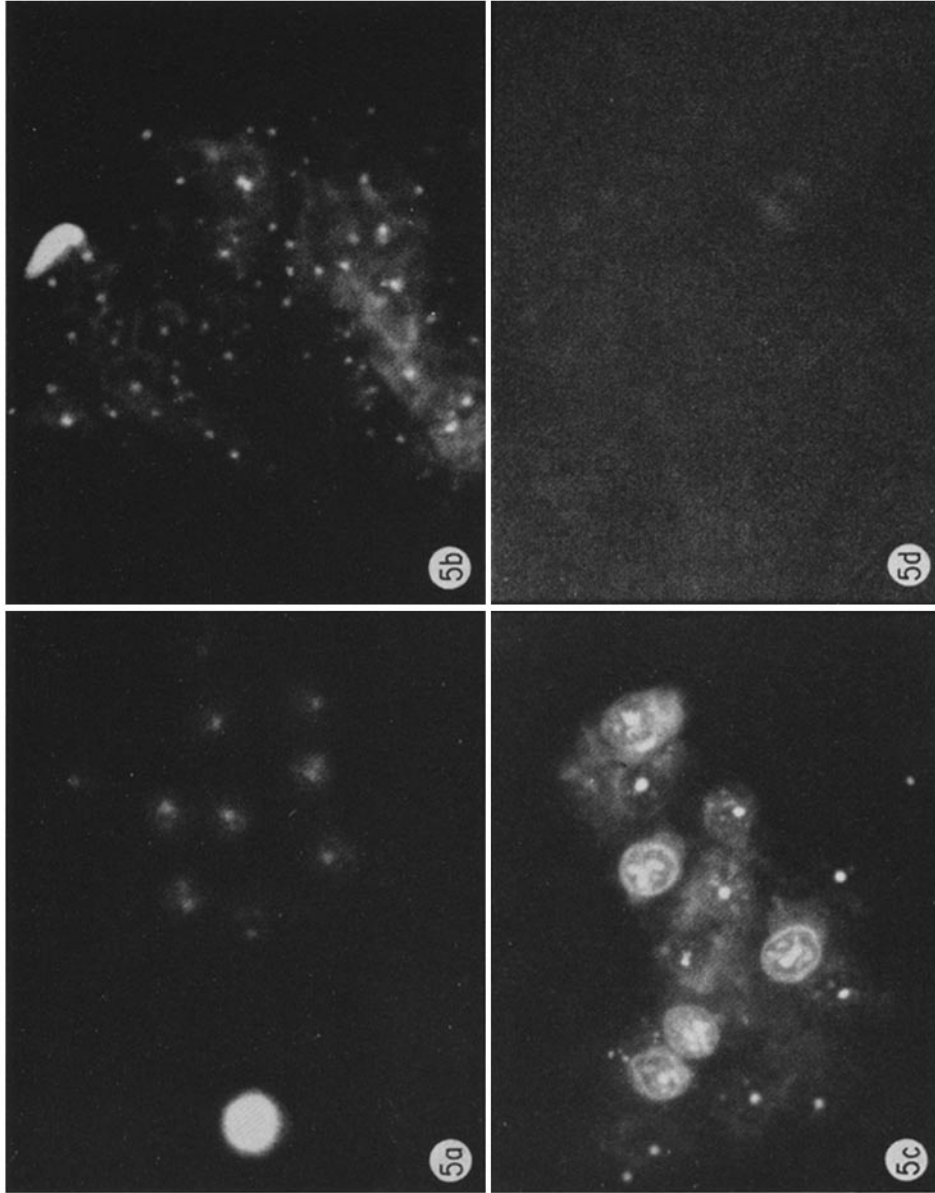


Fig. 5a, b, c, and d. Tissues from D.M. (a patient with Down's syndrome, chronic anicteric hepatitis and acute myelogenous leukemia) stained with conjugated rabbit anti-Au(1) antiserum. (a) liver; (b) mesentery; (c) testis; (d) bone marrow. X 1350.