# THYMUS-DEPENDENT AREAS IN THE LYMPHOID ORGANS OF NEONATALLY THYMECTOMIZED MICE

By DELPHINE M. V. PARROTT, Ph.D., MARIA A. B. de SOUSA,* M.D., and JUNE EAST, Ph.D.

*(From the Imperial Cancer Research Fund, Mill Hill, London, England)*

Plates 33 to 39

(Received for publication 12 August 1965)

Downloaded from http://rupress.org/jem/article-pdf/123/1/191/1651055/191.pdf by guest on 08 February 2026

Intravenously injected syngeneic thymus cells are less efficient than the same number of spleen cells in reducing the lymphocyte deficit, preventing the wasting syndrome, and restoring the impaired immunological responses of neonatally thymectomized mice (1–5). This apparent paradox led us to investigate the possibility that the injected cells differed in efficiency because they reached different destinations within the lymphoid organs of the thymectomized recipients.

The destinations of comparable numbers of syngeneic thymus and spleen cells, labeled in vitro with tritiated adenosine and injected into neonatally thymectomized C3H/Bi and $F_1$(C57BL × C3H/Bi) mice, were determined by autoradiography. A dose of 30 million cells was selected because previous experiments had shown that this number of spleen cells would restore the immunological competence of thymectomized recipients but the same number of thymus cells would be without effect (3). In the course of the autoradiographic investigations described below specific areas of severe lymphocyte depletion were defined within the spleen and lymph nodes of the neonatally thymectomized animals and termed "thymus-dependent areas". These findings were confirmed using additional groups of thymectomized and intact, but otherwise untreated, inbred and hybrid mice.

## *Materials and Methods*

*Animals.*—Inbred C3H/Bi and $F_1$ (C57BL × C3H/Bi) mice were thymectomized within 24 hr of birth using anesthesia produced by cooling (6). Whenever practicable some littermates were left intact. Completeness of thymectomy was checked postmortem and by histological examination of the mediastinal region.

*Preparation of Labeled Cell Suspensions.*—Spleen or thymus tissue removed from intact syngeneic donors aged 8 to 10 wk was chopped into large pieces and dissociated in a syringe containing versene buffer. The cells were centrifuged at 1500 *g*, counted in a Neubauer hemocytometer, resuspended at a concentration of $10^8$ cells/ml in 5 ml of the same buffer containing 10 $\mu$c tritiated adenosine/ml (specific activity 1.07 c/mM; Radiochemical Center, Amersham,

* Visiting worker from the Gulbenkian Foundation, Lisbon, Portugal.

England), and incubated for 1 hr at 37°C. After incubation the cells were washed thoroughly, twice with versene buffer, and once with isotonic saline, and recounted.

*Injection of Labeled Cell Suspensions.*—Labeled cells, resuspended in isotonic saline, were injected slowly into the right femoral vein of thymectomized or intact C3H/Bi & $F_1$ (C57BL × C3H/Bi) mice anesthetized with Avertin. Alternate littermates were given $3 \times 10^7$ thymus or spleen cells/mouse in a volume of 0.15 ml and were killed 15 min, 1 hr 15 min, 5 to 6 hr, 24 hr, and 62 hr later.

*Histology.*—Sections of the lungs, liver, spleen, mesenteric and inguinal lymph nodes, and thymus (where available) of thymectomized or intact C3H/Bi and $F_1$ (C57BL × C3H/Bi) mice were cut routinely at 5 $\mu$ and stained with hematoxylin and eosin or methyl green–pyronin (Unna Pappenheim).

The same organs of mice which had received isotopically labeled cell suspensions were fixed in formal saline, embedded in paraffin wax, and sectioned at 3 $\mu$. The mounted sections were coated with photographic emulsion (Ilford K 5) by the "dipping" technique of Kopriwa and Leblond (7), stored at 4°C for 4 wk, and stained through the emulsion with methyl green–pyronin after development.

Smears of the isotopically labeled thymus and spleen inocula were fixed in methyl alcohol and stained with Giemsa after development.

## RESULTS

### *Histological Findings in Thymectomized and Intact C3H/Bi and $F_1$ (C57BL × C3H/Bi) Mice*

Histological material was obtained from 55 thymectomized and 39 intact C3H/Bi mice aged 2 to 9 wk (including 20 thymectomized and 11 intact animals used for autoradiographic studies) and 50 thymectomized and 30 intact $F_1$ (C57BL × C3H/Bi) hybrids of the same age. Both healthy and wasting thymectomized mice were examined. The general histological picture of the lymphoid organs of the neonatally thymectomized C3H/Bi mice has been described previously (3) but for the purpose of these investigations detailed data from the inbred and hybrid mice are considered together.

*Spleen.*—With one important exception, there was little to distinguish the spleens of neonatally thymectomized and intact mice less than 6 wk old. Their organs were initially (birth to 3 wk) composed of myelopoietic and erythropoietic cells with reticular cells and a few primary follicles located around the central arterioles. As the animals aged from 3 to 7 wk the lymphoid follicles increased in number and size and active germinal centers developed (Figs. 1 *a* and 1 *b*). However, in the thymectomized mice of this age, clearly delineated areas of severe lymphocytic depletion, the thymus-dependent areas, were seen within the follicles and immediately surrounding the central arterioles (Text-fig. 1; Figs. 2 *a* and 2 *b*) and the large, pale-stained, nucleated, reticular cells became more prominent by contrast. These thymus-dependent areas were evident in the youngest (3 wk) of the thymectomized mice examined as well as in the older healthy or wasting animals.

If the thymectomized mice survived for more than 6 to 7 wk, the follicles became smaller and the germinal centers fewer and less active. It was, moreover, no longer easy to distinguish the thymus-dependent areas in sections stained with hematoxylin-eosin but, if methyl green–pyronin was used, it became obvious that the areas had been repopulated by rapidly dividing pyroninophilic cells (Figs. 3 *a* and 3 *b*). The majority of

Downloaded from http://rupress.org/jem/article-pdf/123/1/191/1651055/191.pdf by guest on 08 February 2026

these were immature plasma cells identified by a paranuclear halo in the ample cytoplasm, a nucleus with clumped chromatin, and a prominent central nucleolus. Other cells having a large round nucleus with delicate chromatin, one or two less distinct nucleoli, and only a thin rim of cytoplasm were also seen, particularly in C3H/Bi mice. These pyroninophilic cells could proliferate to cover the entire white pulp. The repopulation occurred mainly in wasting thymectomized mice but was also seen in some healthy animals of this age.

The amount of red pulp varied in relation to the white pulp. In some thymectomized mice it occupied a relatively greater space, in others it was normal in extent. Plasma

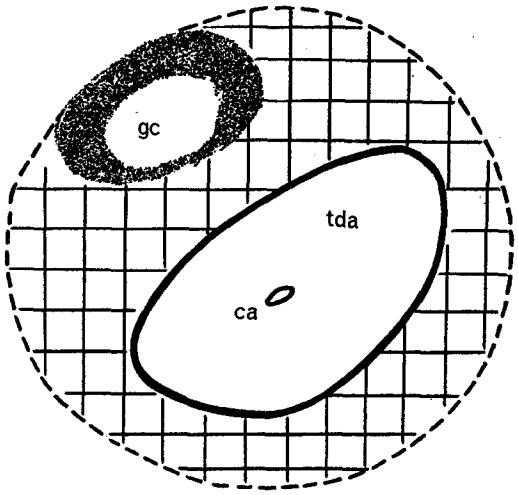


TEXT-FIG. 1. Diagram of a spleen follicle of a neonatally thymectomized mouse showing germinal center (gc) and thymus-dependent area (tda) surrounding central arteriole (ca).

cells were always present in the red pulp of the thymectomized mice and showed marked proliferative activity in the older animals.

Granulomatous lesions, giant cells, and large macrophages containing nuclear debris, were also noted in the spleens of some healthy and many wasting thymectomized mice. These changes are associated with the presence of an hepatotrophic virus MHV-1 (8) and are usually, although not invariably, accompanied by macroscopic liver lesions. The lesions were present in both the white and the red pulp and had no particular relation to the thymus-dependent areas.

*Lymph Nodes.*—Aggregates of lymphocytes appeared in the mesenteric and inguinal lymph nodes of both intact and thymectomized mice during the 2nd wk after birth. During the succeeding 7 wk the nodes of the intact mice developed progressively to comprise an outer cortical zone containing primary and secondary lymphoid nodules, mid and deep cortical zones of reticular cells and lymphocytes, and a medullary region with sinuses lined by lymphocytes and plasma cells (Fig. 4). Postcapillary venules with walls of cuboidal endothelial cells, surrounded by and containing numerous

Downloaded from http://rupress.org/jem/article-pdf/123/1/191/1651055/191.pdf by guest on 08 February 2026

lymphocytes, were prominent in the mid and deep cortex (Fig. 5). Some primary and secondary lymphoid follicles also developed in the outer cortex of thymectomized mice aged 2 to 7 wk but the remainder of the mid and deep cortex, with the exception of a narrow band adjoining the medulla, was greatly depleted of lymphocytes (Text-fig. 2; Fig. 6.), and the postcapillary venules were thin-walled and empty (Fig. 7). This is the thymus-dependent area of the lymph node which is presumably equivalent to the areas around the central arterioles within the splenic follicles.

The medullary region of 6-wk-old thymectomized mice was normal but, in animals surviving beyond 6 to 7 wk, immature plasma cells proliferated in the medullary cords and seemed to replace the narrow remaining band of lymphocytes at the corticomedullary junction and encroach upon the depleted areas of the mid cortex. Occasionally they covered the entire cortex. Few primary and secondary follicles remained in the outer cortex of thymectomized mice of this age.

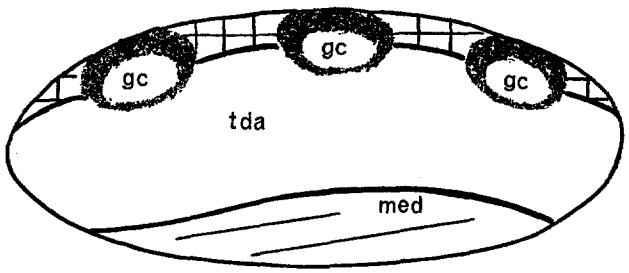


TEXT-FIG. 2. Diagram of a lymph node of a neonatally thymectomized mouse showing follicles with germinal centers (gc) in outer cortex, the thymus-dependent area (tda) in the mid and deep cortex, and the medullary region (med).

Lesions attributable to the virus MHV-1 were also seen in the cortex of the lymph nodes.

### *Autoradiographic Studies on Thymectomized and Intact Mice*

Inocula of isotopically labeled cells were injected intravenously into 20 thymectomized and 11 intact, anesthetized, C3H/Bi mice aged 37 to 50 days, and 4 thymectomized $F_1$(C57BL × C3H/Bi) hybrids aged 44 days. Members of at least two different litters were killed at each time interval.

*Labeling of Inocula.*—More than 90 % of all thymus and spleen cells were labeled after incubation in vitro with tritiated adenosine for 1 hr. The thymus suspensions contained large and small lymphocytes in almost equal proportions but the former were more heavily labeled. The constituent cells of the spleen inocula were more diverse. Approximately 20% of lightly labeled cells were myeloid in character, 10% were very large, heavily labeled blast cells, and 70% were lymphocytes of various sizes which labeled with varying intensity.

### *The Destination of Isotopically Labeled Thymus and Spleen Cells in C3H/Bi Mice*

The total number of labeled cells in longitudinal sections of spleens selected at random from thymectomized and intact recipients was counted at a magnification of 400.

Downloaded from http://rupress.org/jem/article-pdf/123/1/191/1651055/191.pdf by guest on 08 February 2026

The counts represent the relative distribution of such cells in the red pulp, the perifollicular area, and the follicles, but they cannot be related directly to the number of cells injected. There was good correlation between counts made on different sections of the same organ and reasonable agreement in the data obtained from different mice

TABLE I

*Destination of $H^3$-Adenosine-Labeled Thymus and Spleen Cells in the Spleen of Thymectomized and Intact C3H/Bi Mice*

| Time after injection | | Inoculum | No. of mice | No. of sections counted* | No. of labeled cells | | | |
|---|---|---|---|---|---|---|---|---|
| | | | | | Red pulp | Perifollicular area | Follicles | |
| | | | | | | | Periphery | Thymus-dependent area‡ |
| *hr* | *min* | | | | | | | |
| 0 | 15 | Thymus cells | 1 Thymectomized | 2 | 87, 133 | 21, 30 | 0, 0 | 0, 0 |
| | | | 1 Intact | 3 | 96, 91, 90 | 38, 68, 72 | 0, 0, 0 | 0, 0, 0 |
| 1 | 15 | " " | 2 Thymectomized | 4 | 3, 0, 2, 1 | 61, 10, 12, 2 | 5, 0, 0, 0 | 0, 0, 0, 0 |
| 5–6 | | " " | 3 Thymectomized | 12 | 1 (0–3) | 0 | 1 (0–3) | 2 (0–10) |
| | | | 1 Intact | 1 | 0 | 1 | 2 | 9 |
| 24 | | " " | 3 Thymectomized | 8 | 1 (0–4) | 0 | 8 (0–16) | 51 (18–90) |
| | | | 2 Intact | 3 | 0, 0, 0 | 0, 0, 0 | 2, 8, 38 | 20, 42, 120 |
| 62 | | " " | 1 Thymectomized | 1 | 0 | 2 | 9 | 145 |
| 0 | 15 | Spleen cells | 1 Thymectomized | 4 | 1, 0, 0, 0 | 0, 1, 2, 0 | 0, 0, 0, 0 | 0, 0, 0, 0 |
| | | | 1 Intact | 4 | 1, 5, 1, 1 | 7, 6, 0, 1 | 0, 3, 0, 0 | 0, 0, 0, 0 |
| 1 | 15 | " " | 2 Thymectomized | 5 | 8 (1–24) | 1 (0–1) | 1 (0–2) | 1 (0–1) |
| 5–6 | | " " | 2 Thymectomized | 3 | 4, 5, 4 | 0, 2, 0 | 99, 67, 38 | 47, 49, 22 |
| | | | 3 Intact | 3 | 7, 13, 22 | 0, 2, 4 | 56, 188, 113 | 22, 140, 113 |
| 24 | | " " | 3 Thymectomized | 3 | 1, 16, 2 | 1, 1, 0 | 176, 349, 54 | 63, 90, 24 |
| | | | 2 Intact | 2 | 0, 9 | 0, 5 | 224, 425 | 38, 97 |
| 62 | | " " | 2 Thymectomized | 2 | 6, 14 | 6, 11 | 258, 239 | 90, 116 |

* The mean number and range of labeled cells counted is indicated when more than 4 sections were scanned.

‡ Thymus-dependent areas estimated in intact mice by comparison with thymectomized mice.

killed at the same time after injection. This applied to both thymectomized and intact mice although, in the latter, the region corresponding to the thymus-dependent area could only be estimated and with particular difficulty in large follicles in which the central arteriole was branched. Sections of lymph nodes were not easy to orientate and the distribution of labeled cells was more uneven than in the spleen. Thus, one section could be devoid of label while succeeding sections contained 20 or more labeled cells.

*Destination in the Spleen.*—(Table I) Many labeled thymus cells were seen in the

Downloaded from http://rupress.org/jem/article-pdf/123/1/191/1651055/191.pdf by guest on 08 February 2026

TABLE II

*Destination of $H^3$-Adenosine-Labeled Thymus and Spleen Cells in the Mesenteric Lymph Nodes of Thymectomized and Intact C3H/Bi Mice*

| Time after injection | | Inoculum | No. of mice | No. of sections counted* | No. of labeled cells | | |
|---|---|---|---|---|---|---|---|
| | | | | | Outer cortex | Thymus-dependent area | Medulla and cortico-medullary junction |
| *hr* | *min* | | | | | | |
| 0 | 15 | Thymus cells | 1 Thymectomized | 1 | 0 | 1 | 1 |
| | | | 1 Intact | 1 | 0 | 1 | 0 |
| 1 | 15 | " " | 2 Thymectomized | 6 | 0 | 1 (0–2) | 1 (0–2) |
| 5–6 | | " " | 3 Thymectomized | 17 | 0 | 1 (0–7) | 1 (0–4) |
| | | | 1 Intact | 1 | 0 | 0 | 0 |
| 24 | | " " | 2 Thymectomized | 5 | 0 | 4 (0–9) | 0 |
| | | | 2 Intact | 2 | 0, 0 | 1, 19 | 0, 0 |
| 62 | | " " | — | — | — | — | — |
| 0 | 15 | Spleen cells | 1 Thymectomized | 3 | 0, 0, 0 | 0, 0, 0 | 0, 0, 0 |
| | | | 1 Intact | 4 | 0, 0, 0, 0 | 0, 0, 0, 0 | 0, 0, 0, 0 |
| 1 | 15 | " " | 2 Thymectomized | 10 | 0 | 2 (0–11) | 1 (0–4) |
| 5–6 | | " " | 2 Thymectomized | 8 | 1 (0–1) | 5 (0–17) | 1 (0–1) |
| | | | 3 Intact | 7 | 1 (0–1) | 8 (3–14) | 2 (0–5) |
| 24 | | " " | 3 Thymectomized | 8 | 4 (0–21) | 10 (0–52) | 1 (0–2) |
| | | | 2 Intact | 4 | 8, 1, 18, 0 | 8, 9, 22, 72 | 2, 0, 8, 0 |
| 62 | | " " | 2 Thymectomized | 2 | 12, 13 | 27, 34 | 1, 6 |

* The mean number and range of labeled cells counted is indicated when more than 4 sections were scanned.

splenic red pulp (Fig. 8) and in the perifollicular zones (Fig. 9) of both thymectomized and intact animals killed 15 min after injection and whilst still anesthetized, but none had localized in the follicles. The two types of labeled thymus cells were readily distinguished in the sinusoids. By contrast very few labeled spleen cells had accumulated in any part of the spleen at this time. 1 hr later the total population of injected thymus cells had decreased, although a few appeared within the periphery of the follicle of one thymectomized recipient. Labeled spleen cells were now present in the red pulp but only in small numbers. By 5 to 6 hr after injection very few thymus cells were identified in any of the 13 sections scanned but large numbers of spleen cells were at the periphery and in the thymus-dependent areas of the follicles.

Downloaded from http://rupress.org/jem/article-pdf/123/1/191/1651055/191.pdf by guest on 08 February 2026

TABLE III

*Destination of $H^3$-Adenosine-Labeled Thymus and Spleen Cells in the Inguinal Lymph Nodes of Thymectomized and Intact C3H/Bi Mice*

| Time after injection | | Inoculum | No. of mice | No. of sections counted* | No. of labeled cells | | |
|---|---|---|---|---|---|---|---|
| | | | | | Outer cortex | Thymus-dependent area | Medulla and cortico-medullary junction |
| *hr* | *min* | | | | | | |
| 0 | 15 | Thymus cells | 1 Thymectomized | 1 | 0 | 0 | 0 |
| | | | 1 Intact | 1 | 0 | 0 | 0 |
| 1 | 15 | " " | 1 Thymectomized | 7 | 0 | 0 | 0 |
| 5–6 | | " " | 3 Thymectomized | 17 | 0 | 0 | 0 |
| | | | 1 Intact | 10 | 0 | 0 | 0 |
| 24 | | " " | 3 Thymectomized | 7 | 1 (0–1) | 2 (0–4) | 1 (0–1) |
| | | | 2 Intact | 7 | 0 | 5 (0–13) | 0 |
| 62 | | " " | 1 Thymectomized | 3 | 0, 0, 0 | 12, 12, 12 | 0, 0, 16 |
| 0 | 15 | Spleen cells | 1 Thymectomized | 5 | 0 | 1 (0–1) | 0 |
| 1 | 15 | " " | 2 Thymectomized | 10 | 0 | 0 | 0 |
| 5–6 | | " " | 1 Thymectomized | 9 | 0 | 1 (0–2) | 0 |
| | | | 3 Intact | 6 | 1 (0–1) | 2 (0–6) | 1 (0–1) |
| 24 | | " " | 2 Thymectomized | 9 | 2 (0–2) | 1 (0–2) | 1 (0–1) |
| | | | 1 Intact | 5 | 1 (0–2) | 2 (0–5) | 0 |
| 62 | | " " | 1 Thymectomized | 1 | 8 | 6 | 0 |

* The mean number and range of labeled cells counted is indicated when more than 4 sections were scanned.

At 24 to 62 hr thymus cells reappeared in the spleen but they now favoured the thymus-dependent areas, often clustering in large numbers around the central arterioles (Fig. 10) rather than at the periphery of the follicles. Approximately the same number of labeled spleen cells was found in the thymus-dependent areas but, in addition, many more were at the follicle periphery (Fig. 11). The red pulp and perifollicular zones were relatively deserted at these times but contained more spleen than thymus cells.

*Destination in Lymph Nodes.*—(Tables II and III) Far fewer labeled cells were identified in the lymph nodes than in the spleen. Although more cells appeared in the mesenteric than in the inguinal nodes and at an earlier time, the number of cells in both organs increased progressively. Most of the thymus cells and the majority of the

Downloaded from http://rupress.org/jem/article-pdf/123/1/191/1651055/191.pdf by guest on 08 February 2026

spleen cells localized preferentially in the thymus-dependent area many of them in, or in close proximity to, the postcapillary venules (Figs. 5 and 7). A few labeled spleen cells also penetrated to the outer cortical zones and into the primary nodules and small numbers of both thymus and spleen cells were found at the corticomedullary junction and in the medulla, particularly in the mesenteric nodes.

*Destination in Thymus.*—Labeled thymus or spleen cells were rarely seen in the thymus of intact recipients at any time after injection.

*Destination in Lungs and Liver.*—Fairly large numbers of both thymus and spleen cells were identified in sections of lungs and liver 15 min, and 1 hr 15 min after injection but not subsequently.

### *The Destination of Isotopically Labeled Thymus and Spleen Cells in $F_1$(C57BL × C3H/Bi) Mice*

Of 4 neonatally thymectomized hybrid mice injected with syngeneic lymphoid cells. 2 were given labeled thymus cells and two labeled spleen cells. They were killed 24 hr later and the distribution of the labeled cells in the spleen was very similar to that already described for C3H/Bi mice.

## DISCUSSION

The specific areas of lymphocyte depletion, the thymus-dependent areas, which have been delineated in the spleen and lymph nodes of neonatally thymectomized mice, are most clearly defined 3 to 7 wk after operation but they also appear in the spleen 3 months after thymectomy at weaning (9) and persist throughout life (10). They are roughly comparable to the depleted areas found in intact rats subjected to prolonged drainage of the thoracic duct lymph (11). Recirculation of lymphocytes from the blood to the lymph is now an established fact (12). Since there is a marked lymphocyte deficit in the blood of neonatally thymectomized mice (1, 13) and in the thoracic duct lymph of rats thymectomized when 6 to 8 days old (14), we assume that the primary effect of thymectomy is upon the migratory or circulatory lymphocyte population which Caffrey et al. (15) have called the "mobilizable lymphocyte pool". It was, therefore, very satisfactory to find that intravenously injected thymus cells, labeled in vitro with tritiated adenosine, localized preferentially in the thymus-dependent areas of the spleen and lymph nodes of the neonatally thymectomized animals. In this respect they behaved very similarly to isotopically-labeled thoracic duct lymphocytes infused into intact rats (16).

The injected spleen and thymus cells, like the thoracic duct lymphocytes of the intact rats, apparently crossed the walls of the postcapillary venules to enter the lymph nodes of both the thymectomized and intact mice. However, their portal of entry into the white pulp of the spleen is less easy to envisage as it seems physiologically unlikely that the labeled cells issued from the central arterioles within the lymphoid follicles. Their prompt appearance in the red pulp suggested that the cells migrated across this region, a route indicated by

Downloaded from http://rupress.org/jem/article-pdf/123/1/191/1651055/191.pdf by guest on 08 February 2026

Fichtelius (17), but this may have no more significance than the early and transient accumulation of the cells trapped in the liver and lungs. Although thymus cells reached the red pulp more quickly and in greater numbers than spleen cells, more of the latter were ultimately found in the follicles. It may be that lymphoid cells normally enter the spleen by a direct route, comparable to the postcapillary venules in the lymph nodes, but as yet unknown.

The complete disappearance of the thymus cells from the spleen 5 to 6 hr after injection and their reappearance at 24 hr requires an explanation, the most reasonable being that they were recirculating in the interim. Obviously both types of cells could have recirculated many times during the period of the experiments as the time schedules do not enable us to build up a sequential picture of their progress but only provide evidence of their presence or absence at isolated moments of time. It may, however, be relevant that Everett et al. (18) found a small but significant proportion of thymocytes labeled with tritiated thymidine in the spleen and the thoracic duct lymph of rats 4 hr after intravenous injection.

The number of labeled cells in the white pulp of the spleen and in the lymph nodes increased gradually and progressively but the spleen appeared to be the favourite target for both types of cells. Many more (2 to 10 times) spleen cells than thymus cells entered the lymphoid tissues and there were also marked differences in their relative distribution within the organs. These differences could account for the relatively greater efficiency of spleen cells in restoring neonatally thymectomized mice to normality but their immunological significance is difficult to understand.

We and others have found that the initial development of lymphoid follicles can proceed in the absence of the thymus and that proliferation of plasma and reticulum cells is unrestricted by neonatal thymectomy (1, 3, 13, 19, 20). Some consideration must, therefore, be given to the possibility that the ultimate diminution or disappearance of the lymphoid follicles and the repopulation of the thymus-dependent areas with pyroninophilic cells are secondary or indirect effects of neonatal thymectomy. It is known that the latent hepatotrophic virus MHV-1 is activated by removing the thymus at birth (8) and Hirano and Ruebner (21) have recently reported lymphocyte destruction followed by pyroninophilia in intact mice infected with MHV-3. Thus, the presence of such a virus could intensify the lymphocyte depletion caused by neonatal thymectomy.

The origin of the rapidly dividing pyroninophilic cells which repopulated the thymus-dependent areas is unknown. They may represent an attempt to reduce a severe lymphocyte deficit, albeit with the wrong type of cell, analogous to the situation in which the total blood leukocyte population is maintained by a polymorphonuclearcytosis (1, 13). The pyroninophilic cells could, under these circumstances, originate from the hyperplastic proliferation of existing clones of cells, an hypothesis already discussed in previous publications (22, 23).

Downloaded from http://rupress.org/jem/article-pdf/123/1/191/1651055/191.pdf by guest on 08 February 2026

Various authors have also described the appearance of pyroninophilic blast cells and a subsequent proliferation of plasma cells in the lymphoid organs of intact animals responding to antigenic stimuli such as BGG, horse GG, and paratyphoid-B (24–27). These initial reactions occurred in areas directly comparable to the thymus-dependent areas and the plasma cells were presumed to derive from small lymphocytes. However, Gowans (28), and Porter et al. (29) have shown that injected small lymphocytes from thoracic duct lymph transform, not into plasma cells, but into large pyroninophilic lymphoid cells in these same areas after initiation of $F_1$ hybrid disease in rats and secondary disease in rabbits. Burwell (30) too has described similar changes in rabbits rejecting bone grafts. Such large pyroninophilic lymphoid cells do not have a secretory endoplasmic reticulum (31). In our experiments the majority of the pyronin-stained cells which appeared in areas specifically depleted of lymphocytes were immature or mature plasma cells only a very few were large pyroninophilic lymphoid cells. It is possible, therefore, that the plasma cells of the thymectomized mice arose *in situ*, conceivably from reticulum cells, under continual antigenic stimulus from an unknown source although the germinal centres showed no sign of proliferative activity and ultimately disappeared. This problem is now being investigated in more detail.

We interpret our results as indicating that the normal thymus produces throughout life, but particularly in the neonatal period, large numbers of cells which contribute directly to the "mobilizable pool" of lymphocytes. The results suggest that there also exists another system primarily responsible for production of the plasma cell series, comparable to the Bursa of Fabricius in chickens, but as yet unidentified in mammals (32). Nevertheless, these two systems function synergistically so that diminution or absence of the thymus-dependent population of lymphocytes will cause aberrant activity of the plasma cell series. The thymus may thus, directly or indirectly, control the balance of cell populations within the body a conclusion which receives additional support from recent studies using the "autoimmune" strain of New Zealand Black mice (33).

## SUMMARY

Specific areas of lymphocyte depletion, termed thymus-dependent areas, have been delineated in neonatally thymectomized C3H/Bi and $F_1$ (C57BL × C3H/Bi) mice. They occur within the lymphoid follicles of the spleen immediately surrounding the central arterioles, and constitute the mid and deep cortical zones of the lymph nodes. These depleted areas appear in healthy thymectomized mice as early as 3 wk after operation but, in mice which survive for more than 6 to 7 wk, the thymus-dependent areas are repopulated by rapidly dividing pyroninophilic cells, the majority of which are immature plasma cells.

Syngeneic thymus cells, labeled in vitro with tritiated adenosine localize preferentially in the thymus-dependent areas after intravenous injection. Simi-

Downloaded from http://rupress.org/jem/article-pdf/123/1/191/1651055/191.pdf by guest on 08 February 2026

larly labeled spleen cells also accumulate in these areas but, in addition, are distributed at the periphery of splenic follicles and in the outer cortical zone of the lymph nodes. Many more spleen than thymus cells enter the lymphoid tissues and the spleen appears to be the primary target.

The apparent paradox that syngeneic thymus cells are less efficient than spleen cells in restoring neonatally thymectomized mice to normality is discussed in the light of these results and possible routes by which the migrating cells could enter the lymphoid tissues are considered. The origin of the plasma cells which repopulate the lymphocyte depleted areas is also discussed.

It is concluded that the normal thymus produces cells which contribute directly to the migratory or circulatory lymphocyte population but that there also exists another source of supply for the plasma cell series. These two systems may function synergistically so that the thymus may control, directly or indirectly, the balance of cell populations within the body.

Our thanks are due to Miss A. Purtill and Mr. P. Cleary for skilled technical assistance. We are also most grateful for the help given by Mrs. M. O. Phillips and Miss J. Ridley who prepared the histological material, and by Mr. A. J. Pringle who was responsible for the photography.

## BIBLIOGRAPHY

1. Parrott, D. M. V., and East, J., Studies on a fatal wasting syndrome of mice thymectomized at birth, *in* The Thymus in Immunobiology, (R. A. Good and A. E. Gabrielson, editors), New York, Hoeber-Harper, 1964, 523.
2. Parrott, D. M. V., and East, J., The immunological status of thymectomized animals. A survey, *Proc. Roy. Soc. Med.*, 1964, **57,** 147.
3. East, J., and Parrott, D. M. V., Prevention of wasting in mice thymectomized at birth and their subsequent rejection of allogeneic leukaemic cells, *J. Nat. Cancer Inst.*, 1964, **33,** 673.
4. Dalmasso, A. P., Martinez, C., Sjodin, K., and Good, R. A., Studies on the role of the thymus in immunobiology. Reconstitution of immunologic capacity in mice thymectomized at birth, *J. Exp. Med.*, 1963, **118,** 1089.
5. Hilgard, H. R., Yunis, E. J., Sjodin, K., Martinez, C., and Good, R. A., Reversal of wasting in thymectomized mice by the injection of syngeneic spleen or thymus suspensions, *Nature*, 1964, **202,** 668.
6. East, J., and Parrott, D. M. V., Operative techniques for newborn mice using anaesthesia by cooling, *J. Endocrinol*, 1962, **24,** 249.
7. Kopriwa, B. M., and Leblond, C. P., Improvements in the coating technique of radioautography, *J. Histochem. and Cytochem.*, 1962, **10,** 269.
8. East, J., Parrott, D. M. V., Chesterman, F. C., and Pomerance, A., The appearance of a hepatotrophic virus in mice thymectomized at birth, *J. Exp. Med.*, 1963, **118,** 1069.
9. Metcalf, D., The effect of thymectomy on the lymphoid tissues of the mouse, *Brit. J. Haematol.*, 1960, **6,** 324.
10. Parrott, D. M. V., and de Sousa, M. A. B., unpublished observations.

Downloaded from http://rupress.org/jem/article-pdf/123/1/191/1651055/191.pdf by guest on 08 February 2026

11. McGregor, D. D., and Gowans, J. L., The antibody response of rats depleted of lymphocytes by chronic drainage from the thoracic duct, *J. Exp. Med.*, 1962, **117,** 303.
12. Gowans, J. L., The recirculation of lymphocytes from blood to lymph in the rat, *J. Physiol*, 1959, **146,** 54.
13. Parrott, D. M. V., and East, J., Role of the thymus in neonatal life, *Nature*, 1962, **195,** 347.
14. Schooley, J. C., and Kelly, L. S., Influence of the thymus on the output of thoracic duct lymphocytes, *in* The Thymus in Immunobiology, (R. A. Good and A. E. Gabrielson, editors), New York, Hoeber-Harper, 1964, 236.
15. Caffrey, R. W., Rieke, W. O., and Everett, N. B., Radioautographic studies of small lymphocytes in the thoracic duct of the rat, *Acta Haematol.*, 1962, **28,** 145.
16. Gowans, J. L., and Knight, E. J., The route of recirculation of lymphocytes in the rat, *Proc. Roy. Soc. (London), Ser. B*, 1964, **159,** 257.
17. Fichtelius, K. E., On the destination of thymus lymphocytes, *Ciba Found. Symp. Haemopoiesis: Cell Prod. and Regulation*, 1960, 204.
18. Everett, N. B., Caffrey, R. W., and Rieke, W. O., Recirculation of lymphocytes, *Ann. New York Acad. Sc.*, 1964, **113,** 887.
19. Waksman, B. H., Arnason, B. G., and Janković, B. D., Role of the thymus in immune reactions in rats. III. Changes in the lymphoid organs of thymectomized rats, *J. Exp. Med.*, 1962, **116,** 187.
20. de Vries, M. J., van Putten, L. M., Balner, H., and van Bekkum, D. W., Lésions suggérant une réactivité auto-immune chez des souris atteintes de la "runt disease" après thymectomie néonatale, *Rev. Franc. Etudes Clin. et Biol.*, 1964, **9,** 381.
21. Hirano, T., and Ruebner, B. M., The effect of hepatitis virus infection on lymphatic organs, *Lab. Inv.*, 1965, **14,** 488.
22. Humphrey, J. H., Parrott, D. M. V., and East, J., Studies on globulin and antibody production in mice thymectomized at birth, *Immunology*, 1964, **7,** 419.
23. East, J., and Parrott, D. M. V., The role of the thymus in autoimmune disease, *Acta Allergol.*, 1965, **20,** 227.
24. Congdon, C. C., and Makinodan, T., Splenic white pulp alteration after antigen injection: relation to time of serum antibody production, *Am. J. Path.*, 1961, **39,** 697.
25. Langevoort, H. L., The histopathology of the antibody response. 1. Histogenesis of the plasma cell reaction in rabbit spleen, *Lab. Inv.*, 1963, **12,** 106.
26. Hanna, M. G., Germinal centre changes and plasma cell reaction during the primary immune response, *Intern. Arch. Allergy and Appl. Immunol.*, 1965, **26,** 230.
27. Movat, H. Z., and Fernando, N. V. P., The fine structure of the lymphoid tissue during antibody formation, *Exp. and Mol. Path.*, 1965, **4,** 155.
28. Gowans, J. L., The fate of parental strain small lymphocytes in $F_1$ hybrid rats, *Ann. New York Acad. Sc.*, 1962, **99,** 432.
29. Porter, K. A., Chapuis, G., and Freeman, M. K., Responsibility of small lymphocytes for the killing effect of blood-marrow mixtures in irradiated rabbits, *Ann. New York Acad. Sc.*, 1962, **99,** 456.

Downloaded from http://rupress.org/jem/article-pdf/123/1/191/1651055/191.pdf by guest on 08 February 2026

30. Burwell, R. G., Studies on the primary and the secondary immune responses of lymph nodes draining homografts of fresh cancellous bone (with particular reference to mechanisms of lymph node reactivity), *Ann. New York Acad. Sc.*, 1962, **99,** 821.
31. Binet, J. L., and Mathé, G., Optical and electron microscope studies of the immunologically competent cells during the reaction of graft against host, *Ann. New York Acad. Sc.*, 1962, **99,** 426.
32. Peterson, R. D. A., Cooper, M. D., and Good, R. A., The pathogenesis of immunologic deficiency diseases, *Am. J. Med.*, 1965, **38,** 579.
33. East, J., de Sousa, M. A. B., and Parrott, D. M. V., The immunopathology of New Zealand Black (NZB) mice, *Transplantation*, 1965, in press.

Downloaded from http://rupress.org/jem/article-pdf/123/1/191/1651055/191.pdf by guest on 08 February 2026

## EXPLANATIONS OF PLATES

### PLATE 33

FIGS. 1 *a* and 1 *b*. Spleen follicle of an intact $F_1$ (C57BL × C3H/Bi) mouse aged 49 days.

FIG. 1 *a*. The follicle contains an eccentric germinal center and numerous lymphocytes packed around the central arteriole. Hematoxylin-eosin. × 180.

FIG. 1 *b*. Area immediately surrounding the central arteriole seen at higher magnification. Note the abundant aggregations of lymphocytes and a few reticular cells. Hematoxylin-eosin. × 720.

Downloaded from http://rupress.org/jem/article-pdf/123/1/191/1651055/191.pdf by guest on 08 February 2026

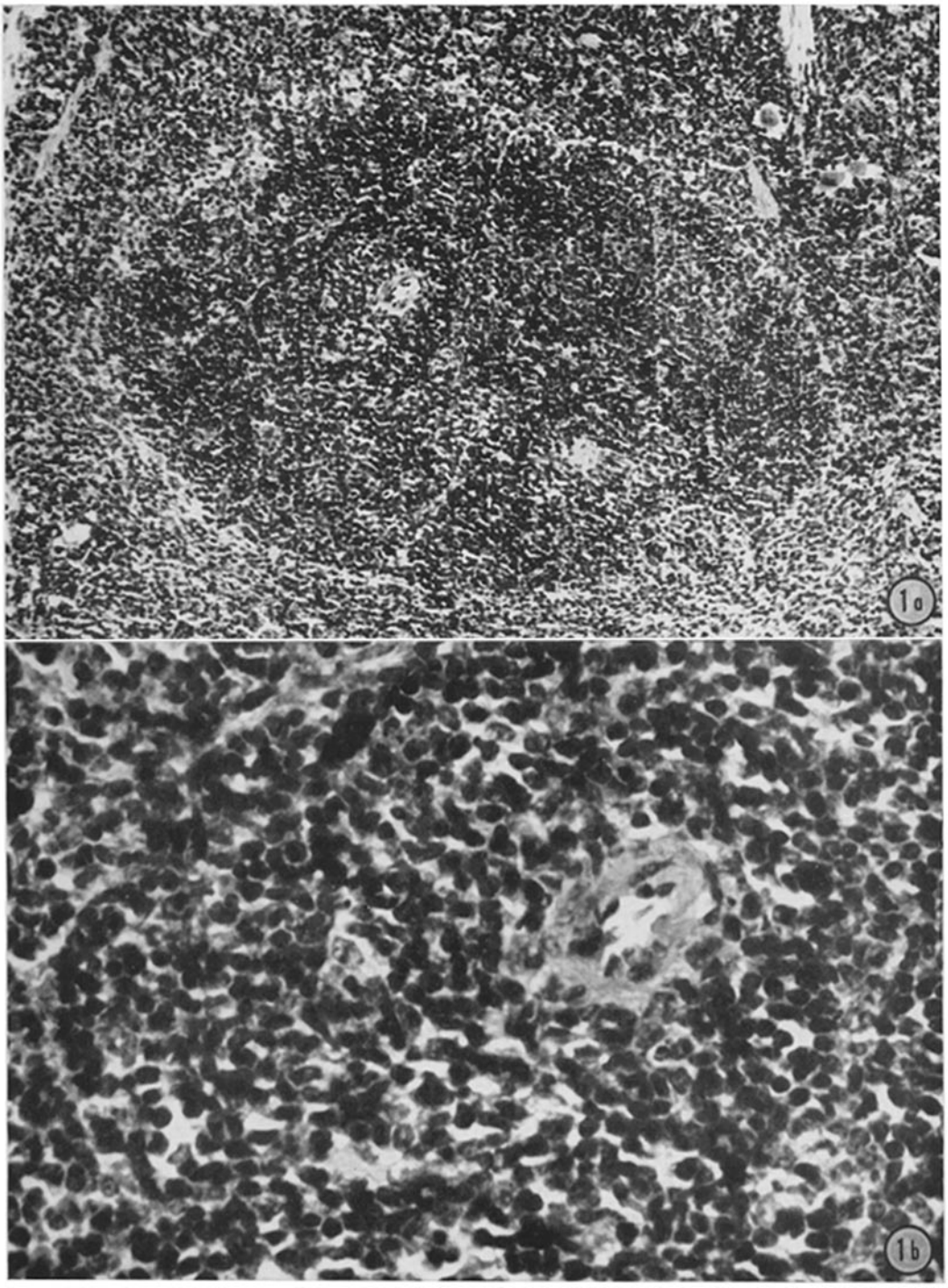


(Parrott et al.: Thymus-dependent areas in lymphoid organs)

Downloaded from http://rupress.org/jem/article-pdf/123/1/191/1651055/191.pdf by guest on 08 February 2026

PLATE 34

FIGS. 2 *a* and 2 *b*. Spleen follicle of a neonatally thymectomized wasting $F_1$ (C57BL × C3H/Bi) mouse aged 49 days.

FIG. 2 *a*. The pale depleted thymus-dependent area is clearly defined around the central arteriole. Hematoxylin-eosin. × 180.

FIG. 2 *b*. Thymus-dependent area seen at higher magnification. Note the marked lymphocyte depletion and persistent reticular cells. Hematoxylin-eosin. × 612.

Downloaded from http://rupress.org/jem/article-pdf/123/1/191/1651055/191.pdf by guest on 08 February 2026

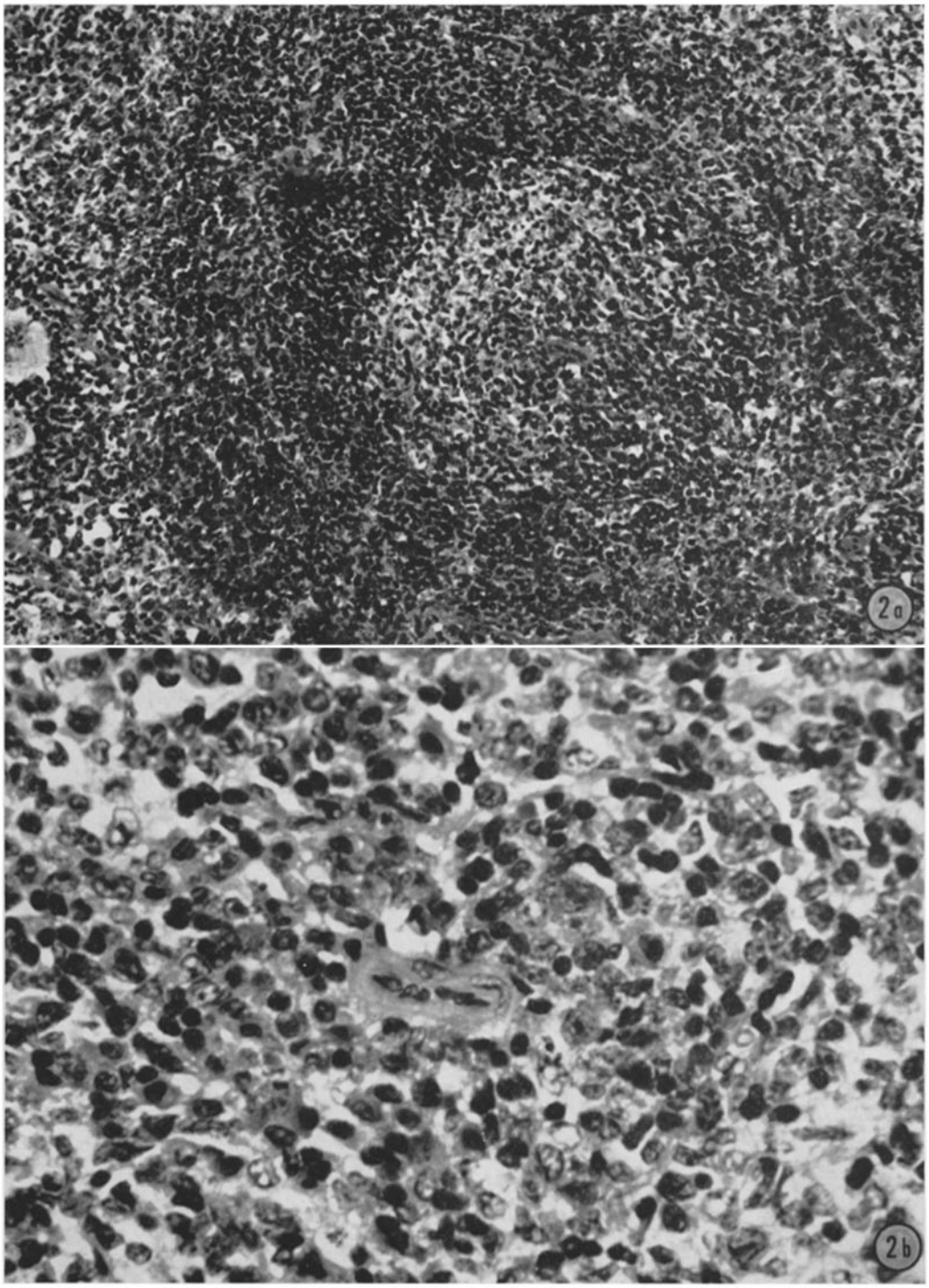


(Parrott et al.: Thymus-dependent areas in lymphoid organs)

Downloaded from http://rupress.org/jem/article-pdf/123/1/191/1651055/191.pdf by guest on 08 February 2026

PLATE 35

FIGS. 3 *a* and 3 *b*. Spleen follicle of a neonatally thymectomized wasting $F_1$ (C57BL × C3H/Bi) mouse aged 54 days.

FIG. 3 *a*. The thymus-dependent area is repopulated. Hematoxylin-eosin. × 180.

FIG. 3 *b*. The thymus-dependent area is seen at higher magnification to be repopulated by pyroninophilic cells the majority of which are immature plasma cells. Methyl green–pyronin. × 760.

Downloaded from http://rupress.org/jem/article-pdf/123/1/191/1651055/191.pdf by guest on 08 February 2026

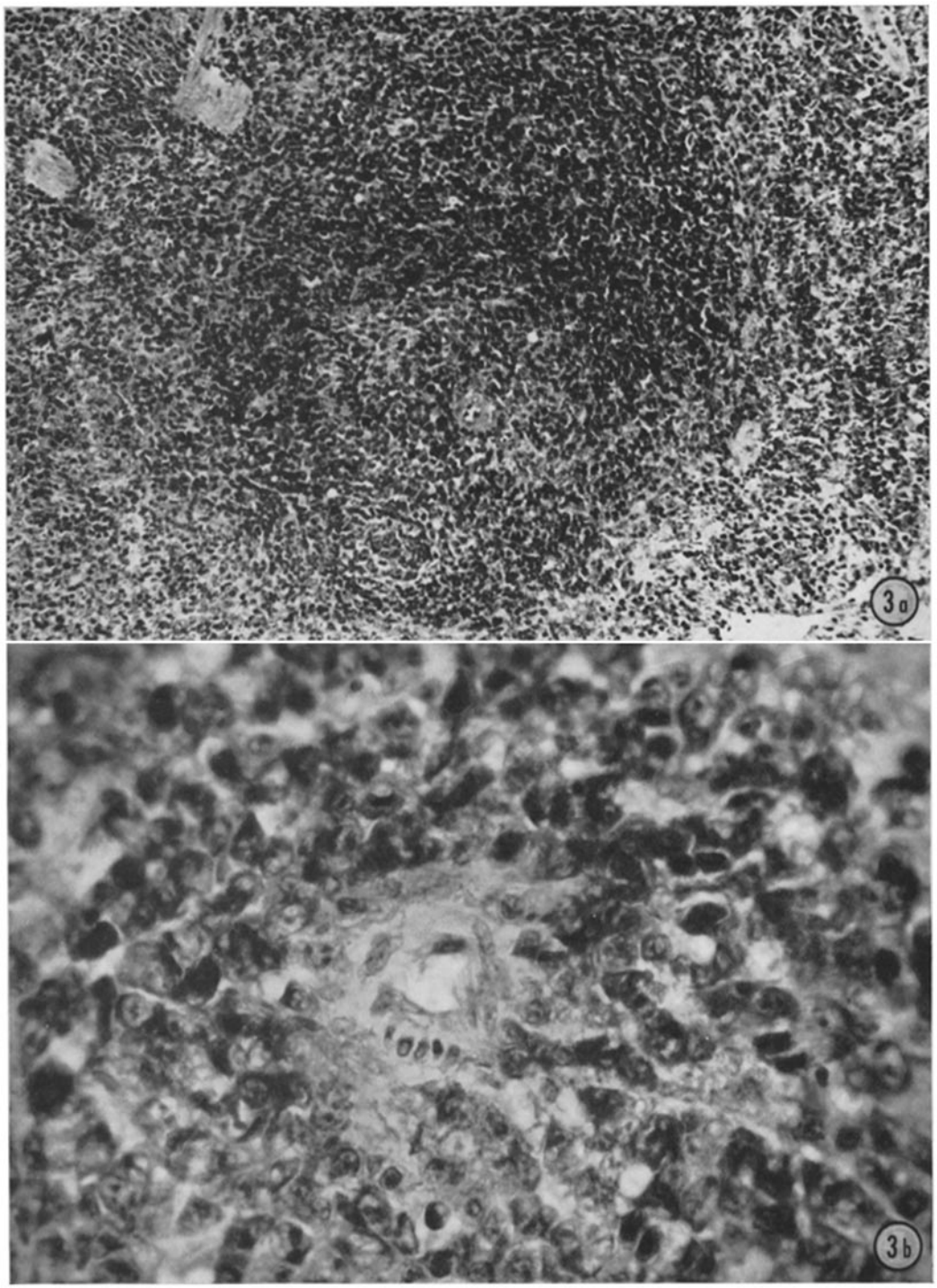


(Parrott et al.: Thymus-dependent areas in lymphoid organs)

Downloaded from http://rupress.org/jem/article-pdf/123/1/191/1651055/191.pdf by guest on 08 February 2026

PLATE 36

FIG. 4. Inguinal lymph node of an intact C3H/Bi mouse aged 46 days showing primary and secondary follicles in the outer cortex and lymphocytes evenly distributed throughout the mid and deep cortex. Hematoxylin-eosin. × 40.

FIG. 5. Postcapillary venule of the lymph node shown in Fig. 4. The venule has a high endothelial wall and many small lymphocytes in the lumen. Note one adjacent $H^3$-adenosine–labeled thymus cell 24 hr after intravenous injection. Methyl green–pyronin × 1590.

Downloaded from http://rupress.org/jem/article-pdf/123/1/191/1651055/191.pdf by guest on 08 February 2026

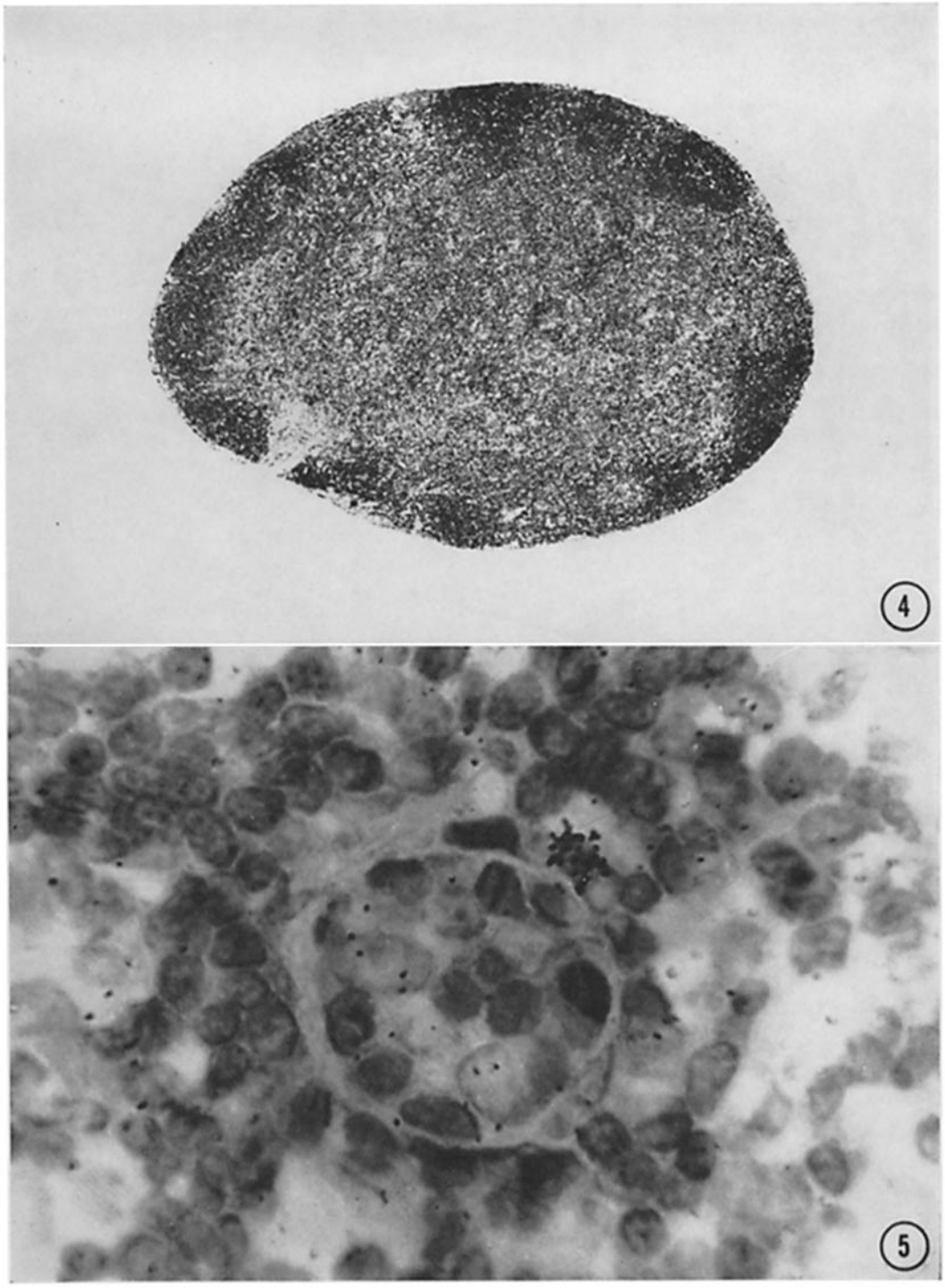


(Parrott et al.: Thymus-dependent areas in lymphoid organs)

Downloaded from http://rupress.org/jem/article-pdf/123/1/191/1651055/191.pdf by guest on 08 February 2026

PLATE 37

FIG. 6. Inguinal lymph node of a neonatally thymectomized C3H/Bi mouse aged 44 days showing primary and secondary follicles in the outer cortex but lymphocyte depletion of the mid and deep cortex (thymus-dependent area). Hematoxylin-eosin. × 76.

FIG. 7. Postcapillary venule (*pcv*) of the lymph node shown in Fig. 6. The venule is collapsed; the endothelial cells are flattened and no lymphocytes are present in the lumen. Note the adjacent $H^3$-adenosine–labeled thymus cells 24 hr after intravenous injection. Methyl green–pyronin. × 1120.

Downloaded from http://rupress.org/jem/article-pdf/123/1/191/1651055/191.pdf by guest on 08 February 2026

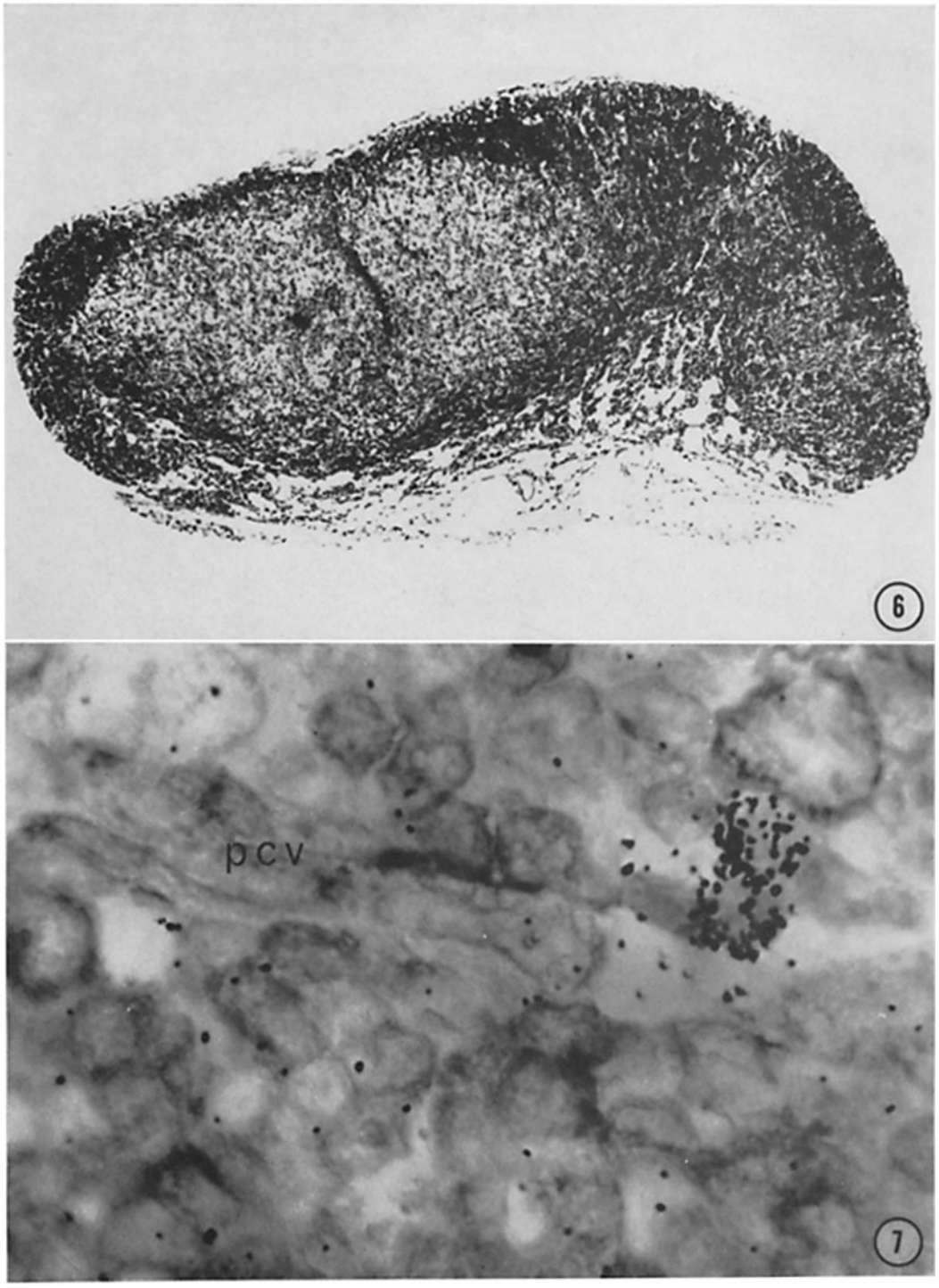


(Parrott et al.: Thymus-dependent areas in lymphoid organs)

Downloaded from http://rupress.org/jem/article-pdf/123/1/191/1651055/191.pdf by guest on 08 February 2026

PLATE 38

FIG. 8. Spleen of a neonatally thymectomized healthy C3H/Bi mouse showing $H^3$-adenosine–labeled thymus cells in the red pulp 15 min after intravenous injection. Methyl green–pyronin. × 1220.

FIG. 9. $H^3$-adenosine–labeled thymus cells in the perifollicular area of the spleen shown in Fig. 8. Methyl green–pyronin. × 135.

Downloaded from http://rupress.org/jem/article-pdf/123/1/191/1651055/191.pdf by guest on 08 February 2026

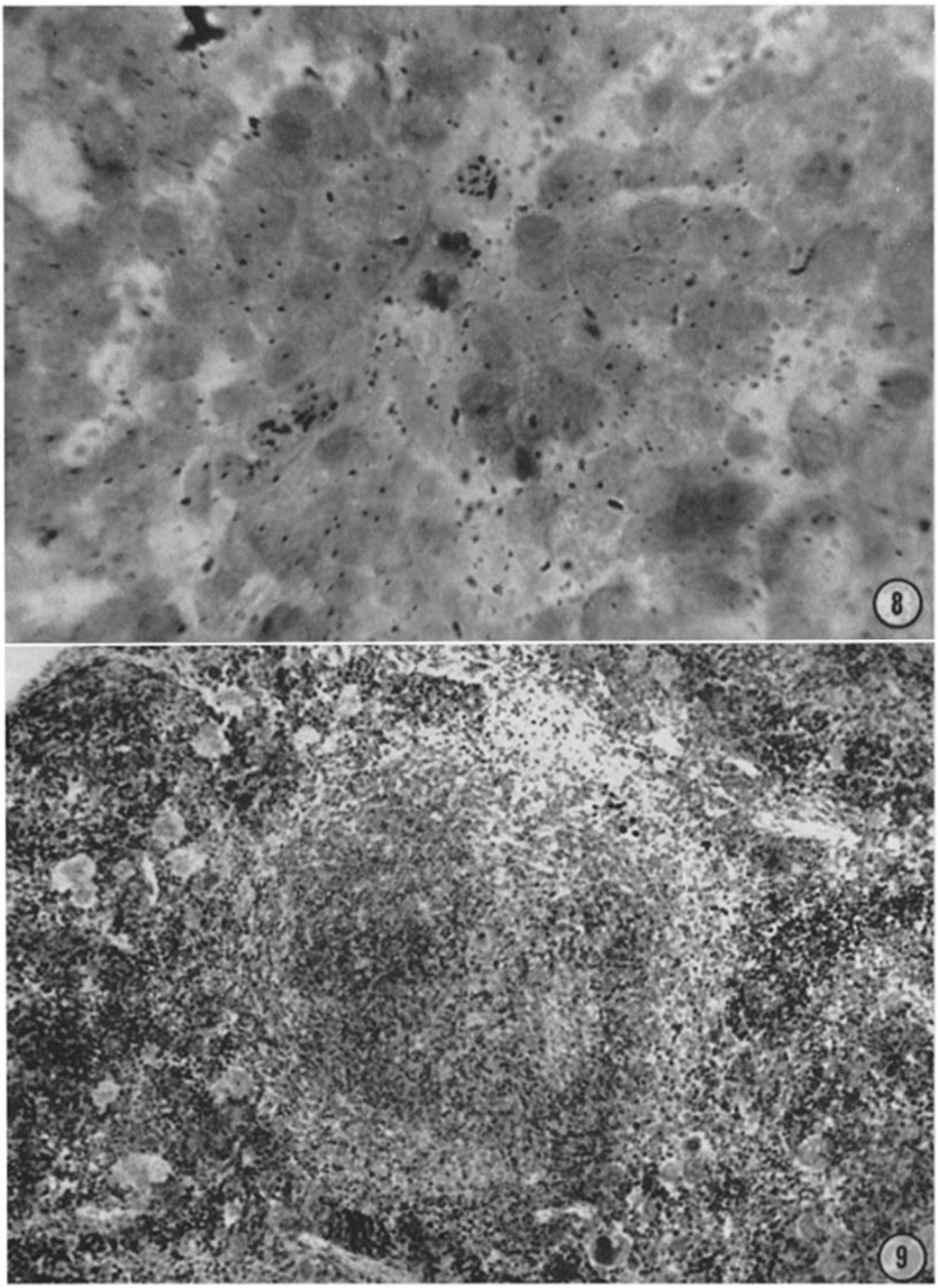


(Parrott et al.: Thymus-dependent areas in lymphoid organs)

Downloaded from http://rupress.org/jem/article-pdf/123/1/191/1651055/191.pdf by guest on 08 February 2026

PLATE 39

FIG. 10. Spleen follicle of a neonatally thymectomized healthy C3H/Bi mouse aged 45 days showing $H^3$-adenosine–labelled thymus cells clustering around the central arteriole (*ca*) in the thymus-dependent area 24 hr after intravenous injection. Methyl green–pyronin. × 900.

FIG. 11. Spleen follicle of a neonatally thymectomized healthy C3H/Bi mouse aged 45 days showing $H^3$-adenosine–labeled spleen cells distributed at the periphery of the follicle 24 hr after intravenous injection. Central arteriole (ca). Methyl green–pyronin. × 760.

Downloaded from http://rupress.org/jem/article-pdf/123/1/191/1651055/191.pdf by guest on 08 February 2026

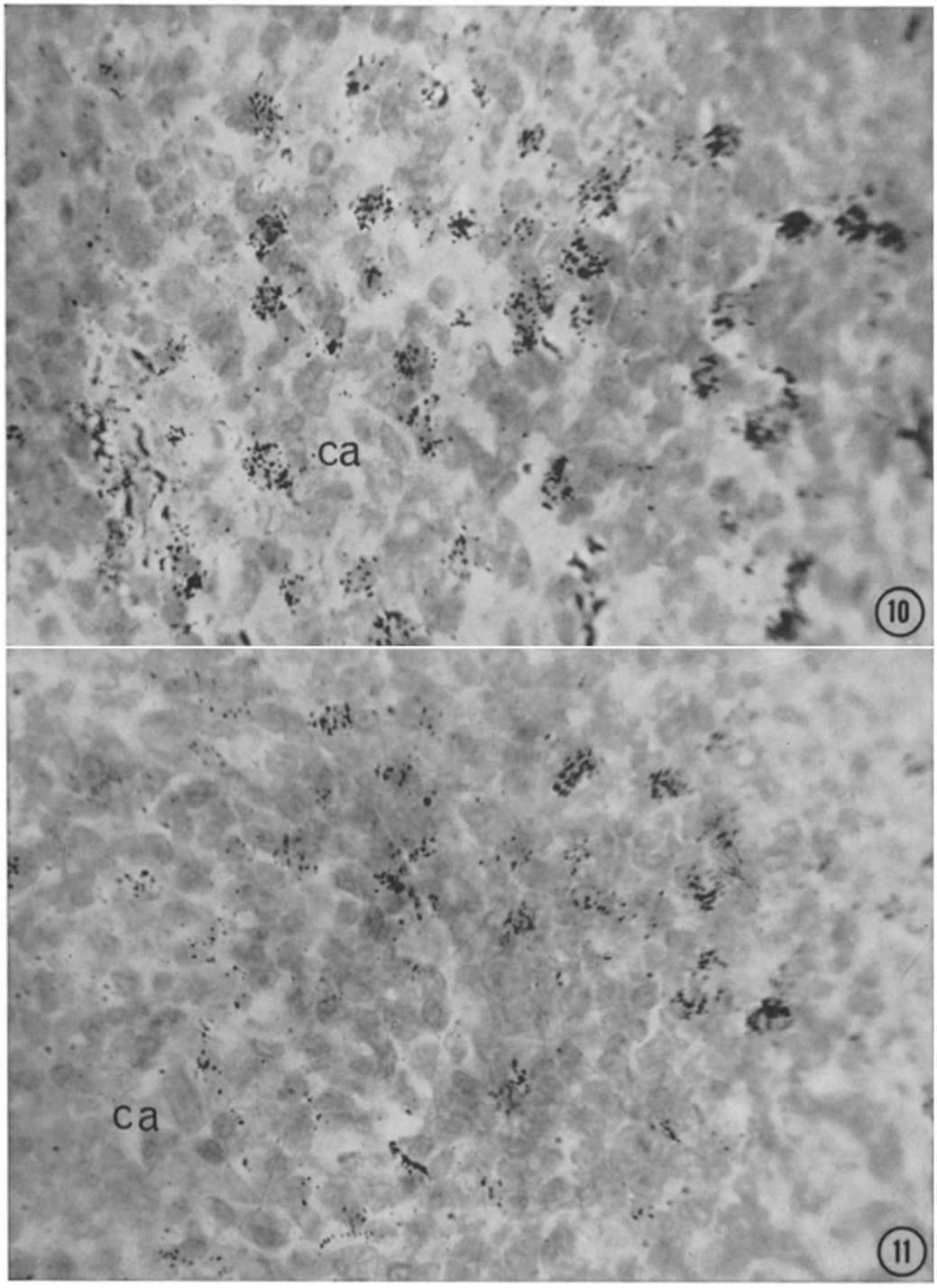


(Parrott et al.: Thymus-dependent areas in lymphoid organs)

Downloaded from http://rupress.org/jem/article-pdf/123/1/191/1651055/191.pdf by guest on 08 February 2026