

## Brief Notes

### The Nucleolus and Parachromatin of the Ascites Tumor Cell. BY ROBERT LOVE.\*

(From the Viral and Rickettsial Section, Research Division, American Cyanamid Company, Pearl River, New York.)‡

The parachromatin of the nucleus of the ascites tumor cell is a substance which is chemically similar to the nucleolus but is topographically distinct from it<sup>1</sup> (1). In fixed preparations, the parachromatin of the interphase nucleus is usually diffusely stained or finely granular, but occasionally it is aggregated in the form of well defined parachromatin bodies (1). A study of the parachromatin and the nucleolus during the mitotic cycle has provided some indication of the functional significance of these structures in the ascites tumor cell.

Since the parachromatin has been demonstrated in all of ten mouse ascites tumors (1) three representative tumors, the Ehrlich, Krebs, and MC1M neoplasms (3) were selected for more intensive study. The morphology of the nucleolus and parachromatin can be observed in smears of these tumors stained by a modification of Barrett's stain (1); by staining in the more basic range of the buffer solutions used in this stain, the nucleolus can be colored blue-green and the parachromatin red. The parachromatin can also be stained purple and the nucleolus blue-green by the

following technic. Thick smears are fixed wet in formol-sublimate for 1 hour, treated with Lugol's iodine solution followed by thiosulfate, stained with freshly prepared 0.01 per cent toluidine blue (Coleman and Bell Co.) in McIlvaine's buffer at pH 3.0 for 30 minutes, rinsed for 5 seconds in tap water, and placed in molybdate-ferrocyanide (4) for 15 minutes; after a very brief rinse in distilled water they are dehydrated with tertiary butyl alcohol, cleared with xylol, and mounted in permount.

In preparations stained by the methods outlined above, the onset of prophase is characterized by aggregation of the finely granular or diffusely stained parachromatin of the interphase cell to form parachromatin bodies; at the same time the nuclear membrane and chromatin strands of the nucleus are accentuated and give rise to the prophase chromosomes. In toluidine blue preparations the chromatin of the interphase nucleus is not recognizably stained (Figs. 1 and 2); with the onset of prophase the chromosomes and the parachromatin bodies are stained purple while the remainder of the nucleus is colorless (Figs. 3 and 4). The nucleoli remain in contact with several chromosomes in early prophase (Fig. 4), but later they become detached and are quite discrete. When the nuclear membrane disintegrates at the end of prophase the nucleoli and parachromatin bodies are liberated into the cytoplasm where they

\* Present address: Laboratory of Pathology, National Cancer Institute, Bethesda, Maryland.

‡ Received for publication, May 28, 1956.

<sup>1</sup> The term parachromatin was first used by Pfitzner (2), to describe the "achromatic" substance of the nucleus.

are distinguishable as blue-green nucleolar and purple (toluidine blue) or red (Barrett) parachromatin bodies (Figs. 5, 6, and 8). Since the nucleoli can only be seen in the cytoplasm during metaphase (Fig. 5) they must undergo rapid disintegration or solution. Parachromatin bodies, however, disappear more slowly and are visible in the cytoplasm throughout anaphase (Fig. 7) and even in the later stages of telophase (Figs. 11 and 12). Although parachromatin bodies are found in the vicinity of the spindle, they are equally common in other parts of the cytoplasm (Figs. 6 to 8) and do not appear to contribute to the formation of the spindle, as suggested by Pfitzner (2). In smears stained by the toluidine blue method, the metaphase plate consists of strongly metachromatic material (Fig. 5), in which the slender pale blue-staining chromosomes can often be seen (Fig. 8). Throughout anaphase and early telophase the chromosomes appear thicker than in Feulgen preparations and are often indistinguishable in a densely staining metachromatic mass (Fig. 7); during telophase a metachromatic nuclear membrane and several chromatin threads are formed. Interphase is finally established when the chromatin loses its metachromasia and the purple parachromatin and blue-green nucleoli reappear. It is possible that some of the parachromatin remains associated with chromatin in interphase but the pattern of metachromatic material is quite distinct from that which is seen in Feulgen preparations (*cf.* Figs. 1 and 2). Telophase follows a comparable course in smears stained by Barrett's method, in which the nucleolus reforms in close relationship to a mass of chromatin and the acidophilic parachromatin becomes apparent between the chromatin threads.

Nucleoli and nuclear and cytoplasmic

parachromatin are demonstrable by a number of cytochemical stains. After fixation in formol-sublimate or alcohol-ether, they stain with the ninhydrin-Schiff (5) (Fig. 11), chloramine-T Schiff (5), and dinitrofluorobenzene methods (5) for amino acids, Danielli's tetrazonium method for tyrosine, tryptophane, and histidine (6) (Fig. 12), the Millon reaction for tyrosine (7), and Barnett and Seligman's method for sulfhydryl groups (8). Contrary to previous results with toluidine blue at a higher pH (1), staining of the nucleolus and parachromatin at pH 3.0 is abolished if the smears are previously incubated for 2 hours in 0.1 per cent aqueous ribonuclease (*cf.* Figs. 8 and 9). The nucleolus and parachromatin, therefore, contain demonstrable amino acids, sulfhydryl groups, tyrosine, possibly histidine or tryptophane, and ribonucleic acid. The occurrence of RNA and basic amino acids in different proportions in the nucleolus and parachromatin would explain why these structures stain differently in both the Barrett and the toluidine blue preparations. Although the parachromatin and the nucleolus will bind either the acid or the basic dyes of Barrett's stain if the pH is suitably adjusted, the parachromatin may contain insufficient amounts of RNA to bind the cationic dyes in the lower pH range. The metachromatic reaction of the parachromatin and the blue-green coloration of the nucleolus with toluidine blue could also be a reflection of the difference in concentration of RNA in these structures. Lison has noted that small amounts of nucleic acids give a metachromatic reaction with toluidine blue while more concentrated solutions are greenish blue (9).

After enzymatic digestion of RNA the chromosomes are clearly defined and stain pale blue by the toluidine blue method (*cf.* Figs. 8 and 9). Extraction of

all the nucleic acids by Schneider's method (10) removes all affinity for toluidine blue. The configuration of the chromosomes in toluidine blue preparations would appear to be produced by central filaments containing DNA surrounded by a sheath of metachromatic material comprising RNA (*cf.* Figs. 8 and 10). During the mitotic cycle metachromatic RNA first becomes demonstrable in, or on the chromosomes as they lie in an unstained medium, after the formation of parachromatin bodies (Fig. 4). This RNA may therefore be the product of the chromosome or a precipitation of preexisting parachromatin. The striking increase in the amount of metachromatic material during prophase and metaphase (*cf.* Fig 4 with Figs. 5 and 8) indicates that RNA becomes increasingly demonstrable in its metachromatic form in close relation to the chromosomes and may be synthesized at this site. When the chromatin loses its metachromasia in late telophase, it is probable that this metachromatic RNA contributes to the formation of the parachromatin which reappears at this time.

Ribonucleoprotein, in the form of the nucleolus and parachromatin, is present in the interphase nucleus and some of this material is transferred to the cytoplasm during mitotic division. According to Heidenhain (11) the transfer of nucleolar material to the cytoplasm during mitosis is a feature of cells with large nucleoli. The prominence of nucleoli and parachromatin in the ascites tumor cell certainly facilitated the present observations. Further study, and the development of more sensitive staining methods should determine whether the formation of parachromatin bodies and their liberation into the cytoplasm are unique features of ascites tumors or whether

they occur also in other neoplastic or normal cells.

#### SUMMARY

1. A method is described for distinguishing the ribonucleoproteins of the nucleolus and parachromatin of ascitic tumor cells of the mouse.

2. In these cells the transfer of ribonucleoprotein from the nucleus to the cytoplasm can occur in two ways. (*a*) At the end of prophase the nucleolus separates from the chromosomes and nucleolar fragments are released into the cytoplasm. (*b*) During prophase the parachromatin is aggregated to form parachromatin bodies which are discharged into the cytoplasm, where they can be detected during metaphase, anaphase, and telophase.

3. A metachromatic form of RNA is demonstrable, and may be synthesized, in close relation to the chromosomes during prophase, metaphase, and anaphase. During telophase the distribution of metachromatic RNA changes, the chromatin loses its metachromasia, and intranuclear metachromatic parachromatin becomes evident.

The author wishes to thank Miss Eugenia E. Berry for her valuable technical assistance.

#### BIBLIOGRAPHY

1. Love, R., Orsi, E. V., and Koprowski, H., *J. Biophysic. and Biochem. Cytol.*, 1956, **2**, 1.
2. Pfitzner, W., *Arch. mikr. Anat.*, 1883, **22**, 616.
3. Levan, A., and Hauschka, T. S., *J. Nat. Cancer Inst.*, 1953, **14**, 1.
4. Love, R., Orsi, E. V., and Berry, E. E., *Proc. Soc. Exp. Biol. and Med.*, 1955, **88**, 666.
5. Burstone, M. S., *J. Histochem. and Cytochem.*, 1955, **3**, 32.
6. Danielli, J. F., Nucleic Acid Symposium of the Society for Experimental Biology, (J. F. Danielli and R. Brown,

- editors), Cambridge University Press, 1951, No. 1, 101.
7. Pearse, A. G. E., *Histochemistry, Theoretical and Applied*, Boston, Little, Brown and Co., 1954, 414.
8. Barnett, R. J., and Seligman, A. M., *Science*, 1952, **116**, 323.
9. Lison, L., *Histochemie et Cytochimie Animales*, Gauthier-Villars, Paris, 2nd edition, 1953, 108.
10. Schneider, W. C., *J. Biol. Chem.*, 1945, **161**, 293.
11. Heidenhain, M., *Plasma und Zelle*, Jena, Gustav Fischer, 1907, 191.

## EXPLANATION OF PLATE 20

FIG. 1. Krebs ascites tumor. Interphase nucleus, previously stained by the toluidine blue method (Fig. 2), decolorized with ethanol and restained by the Feulgen method. Arrows indicate masses of chromatin associated with nucleoli. Note the well defined nuclear membrane.  $\times 1700$ .

FIG. 2. Same cell as depicted in Fig. 1, stained by the toluidine blue method. The darkly staining material in the nucleus is metachromatic and has a different distribution from the chromatin shown in Fig. 1. The nuclear membrane is practically unstained.  $\times 1700$ .

FIG. 3. Krebs ascites tumor. Early prophase stained by the Feulgen method.  $\times 1700$ .

FIG. 4. Same cell as in Fig. 3, stained with toluidine blue. Metachromatic chromosomes clearly defined. Note the prominent parachromatin body (*P*) and the nucleolus (*N*) with associated chromosomes.  $\times 1700$ .

FIG. 5. Krebs ascites tumor. Ill-defined strongly metachromatic metaphase plate with cytoplasmic nucleolar fragment (*N*) and one parachromatin body (*P*) in focus. Toluidine blue stain.  $\times 1700$ .

FIG. 6. Ehrlich ascites tumor. Acidophil parachromatin bodies in cytoplasm of cell in metaphase. Barrett's stain.  $\times 1700$ .

FIG. 7. Krebs ascites tumor. Purple parachromatin bodies in cytoplasm of cell in anaphase. Note the ill-defined deeply staining masses formed by the chromosomes. Toluidine blue stain.  $\times 1700$ .

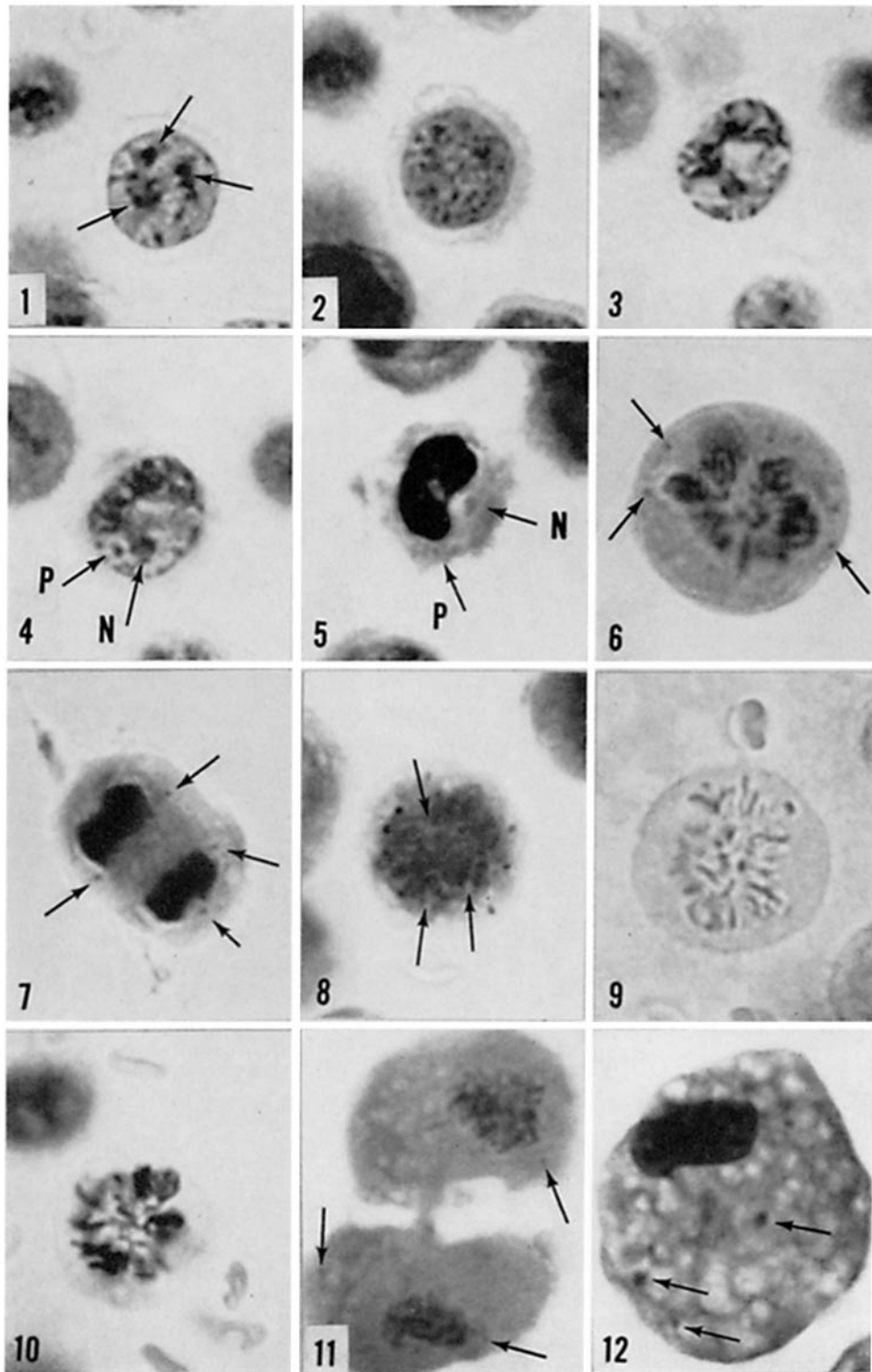
FIG. 8. Krebs ascites tumor. Pale blue-staining chromosomes (shown by arrows) embedded in abundant metachromatic material during metaphase. Note deeply stained parachromatin bodies around the periphery of the metaphase plate. Toluidine blue stain.  $\times 1700$ .

FIG. 9. Smear stained along with that shown in Fig. 8, but previously digested with ribonuclease. No metachromatic staining and no parachromatin granules in colorless cytoplasm. Pale blue chromosomes clearly defined.  $\times 1700$ .

FIG. 10. Smear made at same time as those shown in Figs. 8 and 9, and stained by the Feulgen method. Metachromatic material shown in Fig. 8 is Feulgen-negative.  $\times 1700$ .

FIG. 11. MC1M ascites tumor. Parachromatin bodies in cytoplasm of two cells in telophase. Ninhydrin-Schiff.  $\times 1700$ .

FIG. 12. MC1M ascites tumor. Several unusually large parachromatin bodies in cytoplasm of cell in late telophase. Tetrazonium stain.  $\times 1700$ .



(Love: Nucleolus and parachromatin of ascites tumor cell)