

## HISTOLOGY AND CYTOCHEMISTRY OF HUMAN SKIN

### IX. THE DISTRIBUTION OF NON-SPECIFIC ESTERASES\*

By WILLIAM MONTAGNA, Ph.D.

(From Arnold Biological Laboratory, Brown University, Providence)

PLATES 3 TO 5

(Received for publication, September 8, 1954)

#### INTRODUCTION

Abundant non-specific esterase activity can be demonstrated in human skin, by the method of Nachlas and Seligman (5). In the epidermis the enzyme is concentrated in a strongly reactive band just above the stratum granulosum (Fig. 1). This striking morphological entity is peculiar to the general epidermis and is not found in that of the palm (Fig. 2). Enzyme activity is pronounced in the outer sheath of hair follicles (Fig. 5), and in the sebum of sebaceous glands (Figs. 6 and 7). The axillary apocrine sweat glands are very strongly reactive but the eccrine glands everywhere in the skin show only traces of the enzyme (Figs. 9 to 11).

#### *Materials and Methods*

The biopsy specimens used in this investigation were collected from the scalp, the back, the chest, the palm, and the axilla of human volunteers. Each specimen was removed without anesthesia with a high-speed rotary biopsy punch, 5 mm. in diameter. Those from the scalp, back, chest, and palm were collected from healthy males about 25 years old; those from the axilla were collected from two females 24 and 34 years old. The pieces were fixed 24 hours in chilled, 10 per cent neutral formaldehyde and eventually sectioned with the freezing microtome at 10 to 15  $\mu$ . The sections were hardened for 2 hours in 10 per cent formaldehyde.<sup>1</sup> They were then washed thoroughly in water, defatted in acetone for 5 minutes, returned to distilled water, and finally placed in the incubation mixture described by Nachlas and Seligman (5), using  $\alpha$ -naphthyl acetate as the substrate (2). The incubation mixture was prepared by dissolving 20 mg. of  $\alpha$ -naphthyl acetate in 0.5 ml. acetone, and then adding to it 20 ml. of 0.1 M phosphate buffer at pH 7.4 (6). The solution was stirred, and when its cloudiness disappeared, 20 mg. of naphthyl diazo blue B was added to it. The solution was filtered before it

\* This work was supported in part by a grant from the United States Public Health Service, RG 2125 C4.

<sup>1</sup> Although Nachlas and Seligman (5) used acetone as a fixative because "almost complete inactivation was produced by exposure of the tissue for 24 hours to formaldehyde (10 per cent) . . ." in the experience of this investigator the results obtained with the two fixatives were essentially similar. Formaldehyde has the advantage of being a better fixative for the maintenance of tissue integrity. It has been noted moreover that strong enzyme activity is preserved even in tissues deliberately left in formaldehyde for 1 week.

was used. After the sections had been incubated at room temperature from 5 to 30 minutes, they were washed in distilled water and mounted in glycerin jelly.

#### OBSERVATIONS

The epidermis of the general skin has a moderate amount of demonstrable enzyme activity in the basal layer and in the lower two or three cells of the Malpighian layer. The reaction fades in the upper cells and is completely absent from the granular layer. Just above the granular layer is a very strongly reactive, uninterrupted band (Fig. 1). This band rests above the granular layer and below the stratum corneum, both of which are unreactive. In the epidermis of the palm, the reaction is confined almost entirely to the lower three or four layers of cells of the Malpighian layer (Fig. 2). There is no strongly reactive band above the granular layer; the stratum lucidum is weakly reactive and the granular layer and the stratum corneum are unreactive.

In the pilosebaceous canal of hair follicles, enzyme activity is identical with that of the surface epidermis (Fig. 8). The cells of the outer sheath abound in enzyme activity all the way to the tip of the matrix (Fig. 3). Enzyme reaction in the rest of the follicle is scant. The cells in the dermal papilla contain reactive granules. In resting hair follicles, the outer sheath has only a moderate amount of enzyme reaction. That part of the outer sheath which forms the epithelial capsule around the hair club, however, contains isolated clusters of very strongly reactive cells (Fig. 5). The peg of cells underneath the capsule, which maintains contact with the dermal papilla, the so called "hair germ", is weakly reactive. During *catagen*, when the bulb of the hair follicle begins to degenerate, in preparation for the establishment of a quiescent follicle, its cells are particularly rich in esterases (Fig. 4). The cells of the dermal papilla remain active during *catagen* but are relatively unreactive in quiescent follicles.

The indifferent peripheral sebaceous cells and those cells which are undergoing sebaceous transformation are rich in non-specific esterases (Figs. 6 and 7). The mature cells, however, and the newly formed sebum in the middle of the acini are unreactive. The old sebum in the ducts and in the pilosebaceous canal, however, is very strongly reactive (Fig. 7). The hair shaft and its surrounding, fragmenting internal sheath emerge from the follicle bathed in esterase-rich sebum (Fig. 8).

Eccrine sweat glands show a weak to moderate reaction. The reaction is strongest in the "dark" cells (3); the clear cells show only a trace of it (Fig. 9). The transition segment of the duct shows scant enzyme reaction while the rest of the duct is negative.

The axillary apocrine sweat glands have strong esterase activity. The enzyme is confined to the upper part of the epithelial cells; the basal part and the myoepithelial cells are unreactive (Figs. 10 and 11). The strength of the reaction in the epithelial cells is dependent upon the amount of secretion material stored

in the cells. The cells with the most secretion material have the strongest enzyme reaction (Fig. 10). The ducts show only a trace of reaction.

In the connective tissue, enzyme activity is found in the endothelial cells of capillaries around the epidermal appendages and in the fibroblasts. Mast cells in the tela subcutanea show variable numbers of reactive granules.

#### DISCUSSION

One of the peculiarities of skin surface lipids is that they contain large quantities of free fatty acids (7). Since the chief sources of these lipids are the sebaceous glands and the lipid products of keratinization, the fatty acids must originate from these lipids. If, as has been stated, non-specific esterases hydrolyze esters of short and long chained fatty acids with various alcohols (5), then the free fatty acids in surface lipids could be released through the action of these enzymes. The localization of the enzyme in the epidermis and in the sebum seems to be particularly strategic for such action. The band outlined by the enzyme in the epidermis is a morphological entity which coincides with the stratum lucidum and with a layer rich in protein-bound sulfhydryl groups (4). However, the stratum lucidum proper in the epidermis of the palm shows only a negligible reaction for non-specific esterases. Therefore, the esterase-rich layer in the general skin cannot be considered to be the stratum lucidum, and perhaps deserves a name of its own.

In contrast with the tween method of Gomori (1), which demonstrates only traces of esterase activity in human sebaceous glands, the present technique shows abundant enzyme activity. Enzyme activity is also found in the indifferent sebaceous cells and in the cells which are storing sebaceous lipids. The mature and decaying sebaceous cells, and the new sebum in the center of the acinus show no enzyme reaction. It is surprising, therefore, to find strong enzyme activity in the sebum in the excretory duct and in the pilosebaceous canal. Since the esterases in the sebum must be derived from the sebaceous cells, one might speculate that when the cells break down they release something which inhibits enzyme activity. The action of such a presumptive inhibitor must, however, be short lived, or additional substances in the duct must overcome the action, because, the old sebum abounds in esterase activity.

Since apocrine sweat glands in the axilla store large amounts of lipids, the abundant enzyme which they contain could be tied up with fatty hydrolysis. Enzyme activity is particularly strong in cells which have visible secretion products in the cytoplasm. This property sharply separates the apocrine from the eccrine glands, which show only moderate to weak enzyme reaction.

The eccrine sweat glands possess scanty enzyme activity, and the localization of the activity is confined to the "dark" cells, in contrast to alkaline phosphatase, which is localized primarily in the "clear" cells. The "clear" and "dark" cells, then, appear to be two distinct types of secretory cells.

## SUMMARY

1. In the epidermis non-specific esterase activity outlines a strongly reactive band between the stratum granulosum and the stratum corneum. In the epidermis of the palm, there is no such esterase-rich band.
2. The outer sheath of active hair follicles has strong enzyme activity. The degenerating hair bulb in *catagen* follicles is very strongly reactive, and clusters of cells around the hair club in quiescent follicles are rich in enzyme activity.
3. Strong enzyme activity is found in young sebaceous cells, while decaying sebaceous cells and newly formed sebum are unreactive. Old sebum, however, is very intensely reactive.
4. Only the "dark" cells of eccrine sweat glands show a reaction; the "clear" cells are negative.
5. The cells of axillary apocrine glands abound in enzyme.

## BIBLIOGRAPHY

1. Gomori, G., *Arch. Path.*, 1946, **41**, 121.
2. Gomori, G., *Microscopic Histochemistry*, Chicago, University of Chicago Press, 1952.
3. Montagna, W., Chase, H. B., and Lobitz, W. C., Jr., *J. Inv. Dermatol.*, 1953, **20**, 415.
4. Montagna, W., Eisen, A. Z., Rademacher, A. H., and Chase, H. B., *J. Inv. Dermatol.*, 1954, **23**, 23.
5. Nachlas, M. M., and Seligman, A. M., *J. Nat. Cancer Inst.*, 1949, **9**, 415.
6. Pearse, A. G. E., *Histochemistry. Theoretical and Applied*, London, J. and A. Churchill, Ltd., 1954.
7. Rothman, S., *Physiology and Biochemistry of the Skin*, Chicago, University of Chicago Press, 1954.

## EXPLANATION OF PLATES

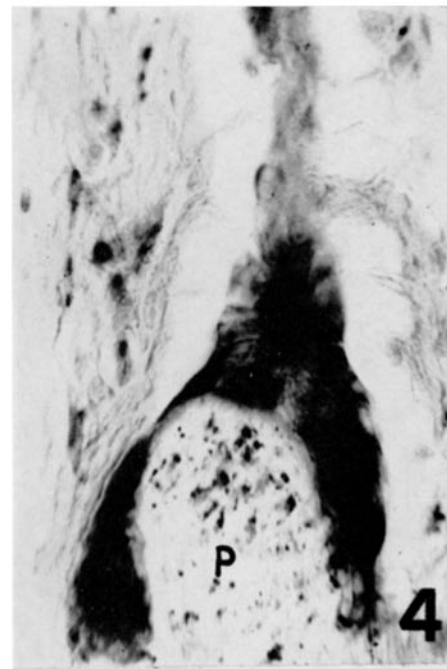
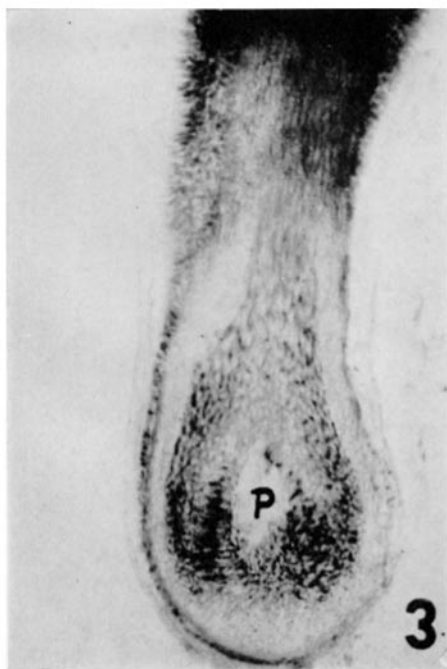
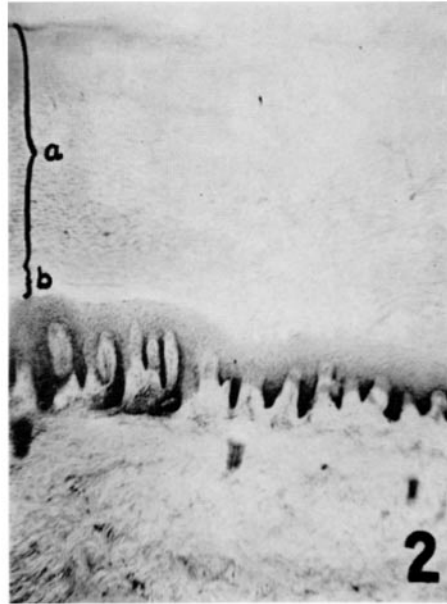
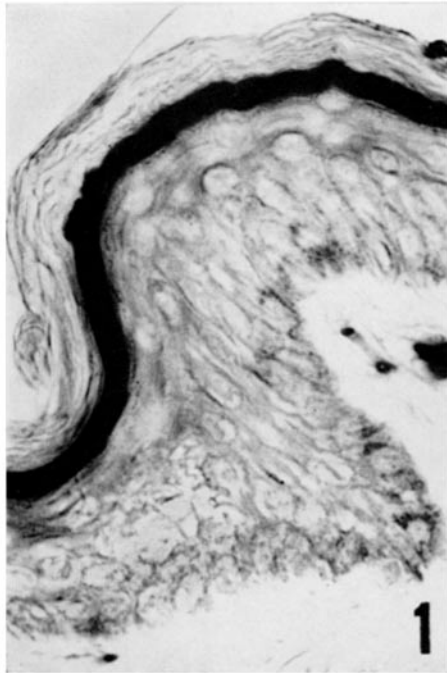
## PLATE 3

FIG. 1. Epidermis from the axilla. Reactive granules are present in the lower cells of the Malpighian layer. An esterase-rich band is to be noted above the granular layer.  $\times 560$ .

FIG. 2. Epidermis of the palm. Enzyme reaction is demonstrable in the lower cells of the Malpighian layer. There is, however, no strongly reactive band above the granular layer, *a* indicates the stratum corneum and *b* the stratum lucidum.  $\times 60$ .

FIG. 3. Esterase activity in the bulb of an active hair follicle from the chest. Strong enzyme activity is evident in the outer sheath. With the exception of the cone of black cells around the dermal papilla (*P*) which contain melanin, all dark colored material represents enzyme activity.  $\times 60$ .

FIG. 4. Catagen hair follicle from the chest. The degenerating cells of the bulb show very strong enzyme activity. The dermal papilla (*P*) also contains reactive cells.  $\times 270$ .



(Montagna: Esterases in human skin)

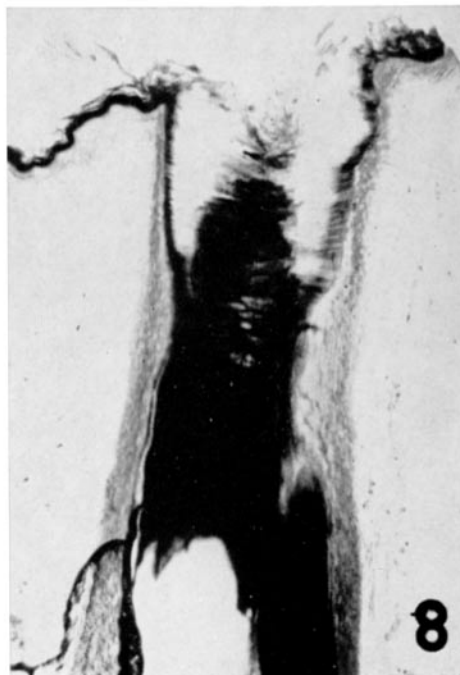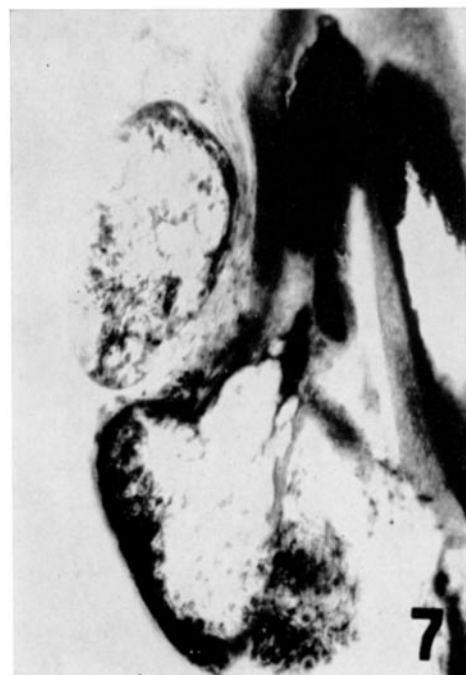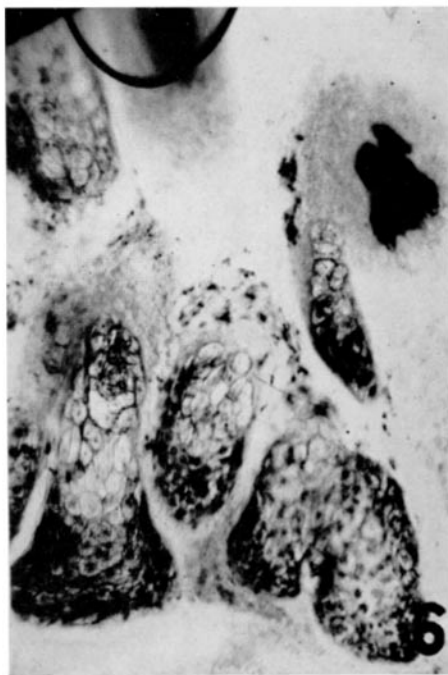
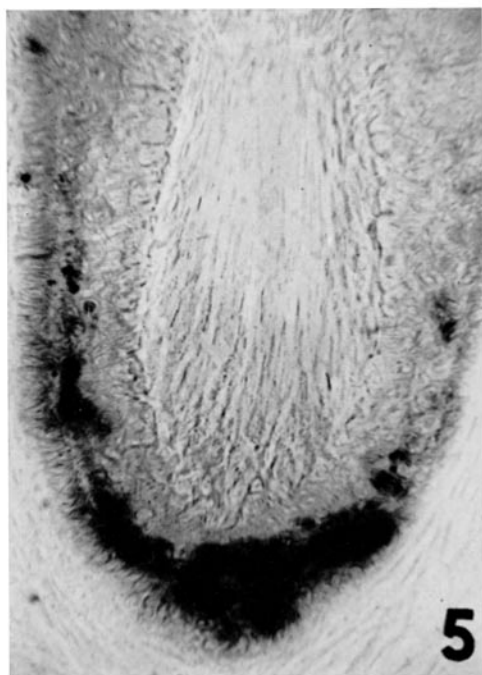
PLATE 4

FIG. 5. Hair club from the chest. The epithelial capsule contains clusters of very reactive cells.  $\times 270$ .

FIG. 6. Sebaceous glands from the axilla.  $\times 270$ .

FIG. 7. Sebaceous gland from the scalp. Degenerating cells and new sebum are unreactive; the old sebum, on the other hand, is strongly reactive.  $\times 270$ .

FIG. 8. Pilosebaceous canal containing strongly reactive sebum. This was found in a specimen from the axilla.  $\times 270$ .



(Montagna: Esterases in human skin)

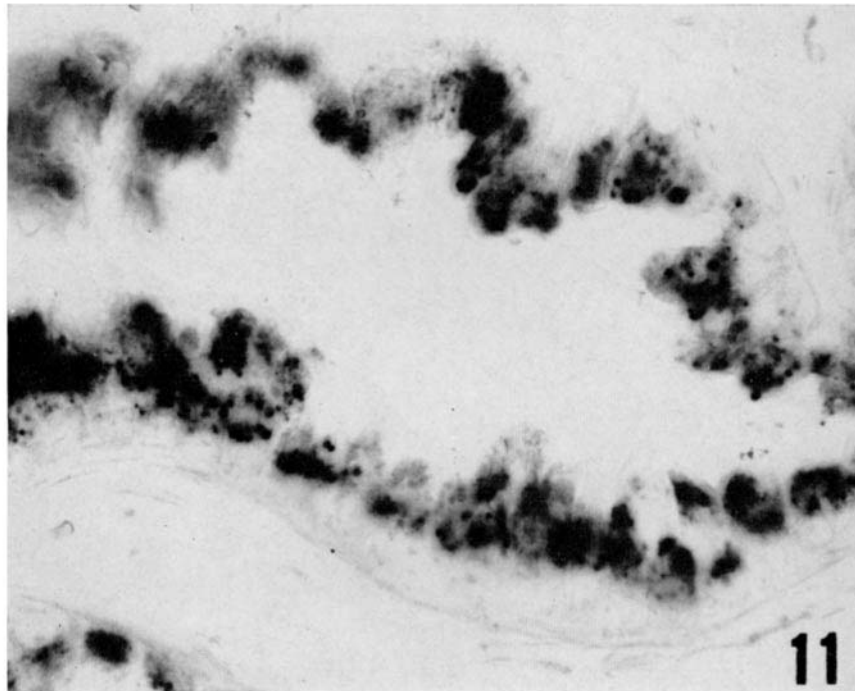
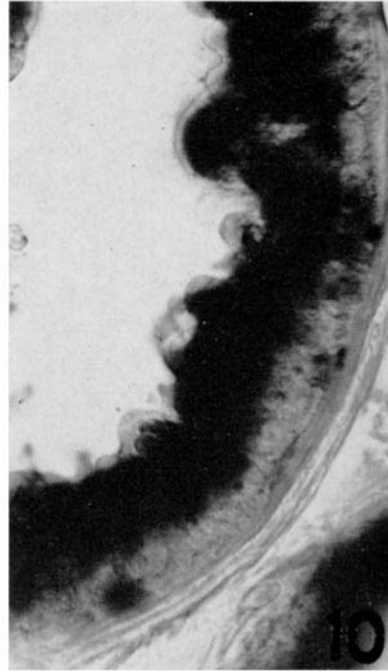
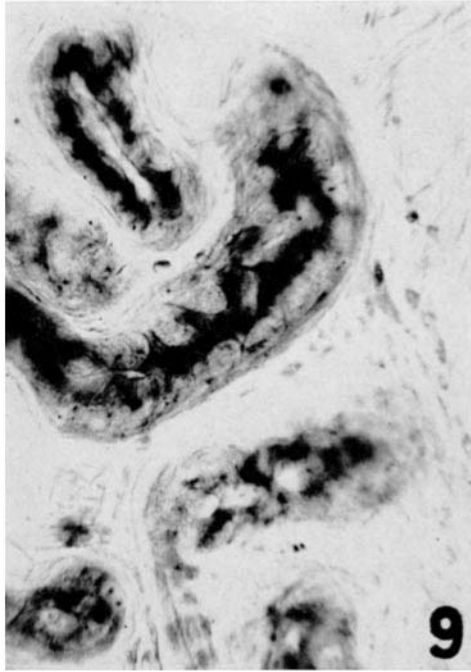
PLATE 5

FIG. 9. Enzyme activity in the eccrine sweat glands of the axilla. The "dark" cells show the strongest reaction.  $\times$  560.

FIG. 10. Abundant reaction present in axillary apocrine gland.  $\times$  560.

FIG. 11. Moderate reaction evident in the apical portion of the cells of the apocrine glands.  $\times$  560.





(Montagna: Esterases in human skin)